



**PATIENT**

Honey Kirby

**SPECIES**

Canine

**BREED**

American Pit Bull  
Terrier

**SEX**

Spayed Female

**AGE**

6

**WEIGHT**

48 Pounds

**INTERPRETED BY**

Kathleen Sennello DVM,  
MS, Diplomate ACVIM  
(Small Animal Internal  
Medicine)

**IMAGING  
PERFORMED BY**

Dr. James Hornbuckle

**HOSPITAL NAME**

Golden Isles AH

**REFERRING VET**

Dr. James Hornbuckle

**INVOICE**

45921

**DATE**

3/15/23

**PRESENTING CLINICAL SIGNS**

Acute vomiting and Diarrhea.

**ULTRASONOGRAPHIC EXAMINATION OF THE ABDOMEN**

**Urinary System**

The urinary bladder is minimally distended with anechoic urine. The Bladder wall, trigone, ureteral papillae and visible urethra (to a depth of 2cm) appear normal with no evidence of wall thickening, mucosal irregularities, masses or cystic calculi. Evaluation of the bladder is greatly reduced due to lack of urine distention.

The left kidney has a normal shape and size (6.61 cm). Overall echogenicity is normal with adequate corticomedullary distinction and a typical 1:3 cortex:medulla ratio. There is no evidence of focal perinephric inflammation or effusion. There is no evidence of pyelectasia, nephroliths, infarcts or hydronephrosis. Renal vasculature is normal.

The right kidney has a normal shape and size (6.32 cm). Overall echogenicity is normal with adequate corticomedullary distinction and a typical 1:3 cortex:medulla ratio. There is no evidence of focal perinephric inflammation or effusion. There is no evidence of pyelectasia, nephroliths, infarcts or hydronephrosis. Renal vasculature is normal.

**Adrenal Glands**

The left adrenal gland is normal in size measuring 0.71 cm at the caudal pole. It is observed in its normal position cranial to the left renal artery. It is normal in appearance (uniformly hypoechoic) and shape with no evidence of a mass effect.

The right adrenal gland is normal in size measuring 0.83 cm at the caudal pole. It is observed in its normal position between the cranial aspect of the right kidney and the caudal vena cava. It is normal in appearance (uniformly hypoechoic) and shape with no evidence of a mass effect.

**Spleen**

The spleen is subjectively normal in size, echotexture is homogenous, and the splenic capsule is smooth with no irregularities. The blood flow through the hilus and splenic parenchyma appears normal. No focal parenchymal abnormalities are visualized.

**Liver**

The liver is subjectively normal in size, and hypoechoic with smooth peripheral margins. The parenchyma is heterogenous in echotexture with subtle, indistinct focal mottling. The visible portions of the vasculature and biliary tract appear normal. No focal nodules or cystic lesions are observed.

The gallbladder lumen is moderately distended. The wall of the gall bladder is not thickened and has a smooth mucosal surface. Luminal contents are mild and primarily anechoic. The cystic and common bile ducts are normal/not visible.

**Gastrointestinal**

The stomach contains a large amount of ingesta. It measures at a normal thickness of <0.7cm with some variability due to the presence of rugal folds. The distinction of the gastric wall layers is adequate and there is no impression of reduced peristaltic activity. No masses or focal lesions were observed.



**PATIENT**

Honey Kirby

**SPECIES**

Canine

**BREED**

American Pit Bull  
Terrier

**SEX**

Spayed Female

**AGE**

6

**WEIGHT**

48 Pounds

**INTERPRETED BY**

Kathleen Sennello DVM,  
MS, Diplomate ACVIM  
(Small Animal Internal  
Medicine)

**IMAGING  
PERFORMED BY**

Dr. James Hornbuckle

**HOSPITAL NAME**

Golden Isles AH

**REFERRING VET**

Dr. James Hornbuckle

**INVOICE**

45921

**DATE**

3/15/23

The visualized areas of duodenum, jejunum and ileum have a relatively uniform diameter with minimal fluid distension. Wall thickness is normal. Bowel loops follow a curvilinear path with distinct wall layering maintaining the typical 1:3 muscularis:mucosa layer ratio. Duodenum wall measures 0.62 cm. Jejunum wall measures 0.40 cm. Visualized peristalsis appears appropriate. There were no focal lesions consistent with obstruction or a mass effect observed.

The ileocecal junction was visualized and exhibited normal intact wall layering and is subjectively of normal thickness. Sections of colon are visualized with formed fecal material and gas shadowing distally. There is no observed focal or generalized colon wall thickening or loss of layering.

**Pancreas**

The pancreas is normal and isoechoic to surrounding mesentery. There is no evidence of nodules or cystic lesions. There is no evidence of regional mesenteric inflammation or fluid.

**Free Abdomen**

Evaluation of the peritoneal cavity did not reveal any evidence of effusion. The lymph nodes appear normal. There is a slightly prominent sublumbar lymph node measuring at 0.62 cm. The omentum is of normal echogenicity.

**ULTRASONOGRAPHIC FINDINGS**

- Hypoechoic, heterogeneous liver – The diffuse hepatic changes are non-specific and could be consistent with vacuolar hepatopathy, nodular hyperplasia, inflammatory/immune-mediated disease, fibrosis, extramedullary hematopoiesis, toxic hepatopathy (e.g., copper), infiltrative neoplasia (less likely) or other hepatopathy. Correlate these findings with lab work. If liver enzymes are normal, this could be within normal limits for this individual.
- Large shadowing ingesta within the gastric lumen – Findings are most consistent with a non-fasted patient.

**INTERPRETATION OF THE FINDINGS & FURTHER RECOMMENDATIONS**

No focal lesions are visualized associated with the gastrointestinal tract to explain the acute vomiting and diarrhea reported. The liver appears slightly heterogeneous and hypoechoic. Correlate this with current bloodwork. If liver enzyme elevations are not present, this is likely an incidental finding.

Recommend treatment for acute gastroenteritis. Consider screening for GI parasitism and correlate with serial imaging (radiographs +/- ultrasound) and probiotic therapy. If symptoms are persistent, then consider the following:

- Consider a novel protein/hydrolyzed protein diet (exclusively at least 4-6 weeks)
- Consider a GI panel to Texas A&M for evaluation of B12 levels, folate, PLI/TLI etc.. to further evaluate for pancreatic/small intestinal disease.
- Recommend pre- and probiotic therapy.
- If symptoms become chronic and there is no evidence of GI foreign material, etc., you could consider obtaining GI biopsies.



**PATIENT**

Honey Kirby

**SPECIES**

Canine

**BREED**

American Pit Bull  
Terrier

**SEX**

Spayed Female

**AGE**

6

**WEIGHT**

48 Pounds

**INTERPRETED BY**

Kathleen Sennello DVM,  
MS, Diplomate ACVIM  
(Small Animal Internal  
Medicine)

**IMAGING  
PERFORMED BY**

Dr. James Hornbuckle

**HOSPITAL NAME**

Golden Isles AH

**REFERRING VET**

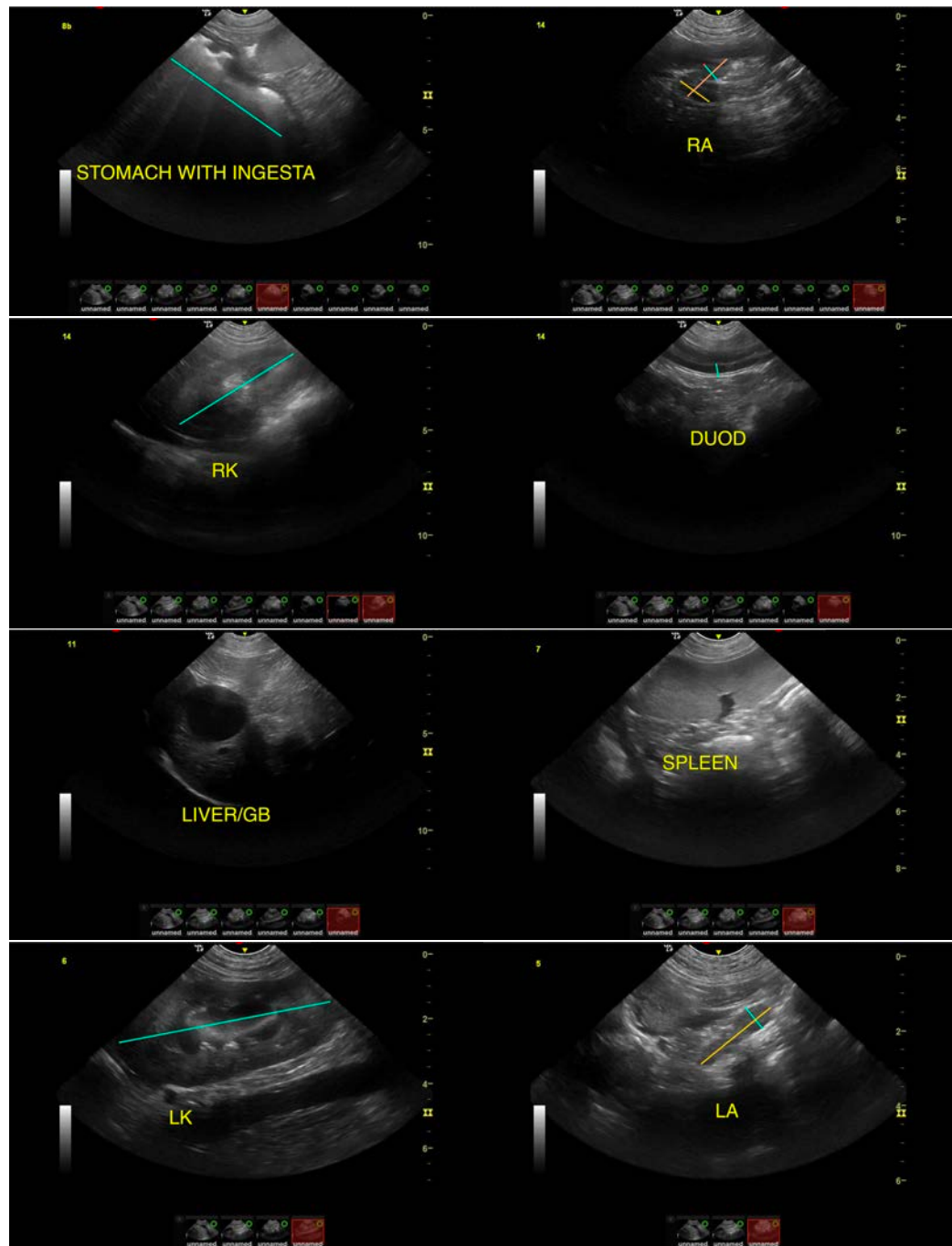
Dr. James Hornbuckle

**INVOICE**

45921

**DATE**

3/15/23





**PATIENT**

Honey Kirby

**SPECIES**

Canine

**BREED**

American Pit Bull  
Terrier

**SEX**

Spayed Female

**AGE**

6

**WEIGHT**

48 Pounds

**INTERPRETED BY**

Kathleen Sennello DVM,  
MS, Diplomate ACVIM  
(Small Animal Internal  
Medicine)

**IMAGING  
PERFORMED BY**

Dr. James Hornbuckle

**HOSPITAL NAME**

Golden Isles AH

**REFERRING VET**

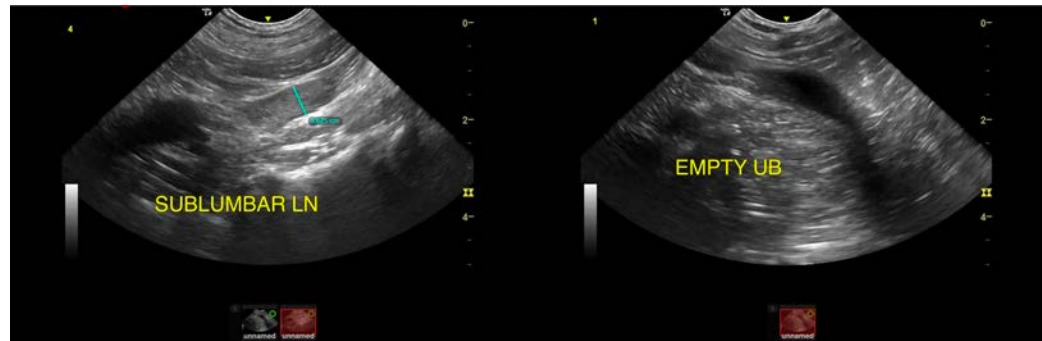
Dr. James Hornbuckle

**INVOICE**

45921

**DATE**

3/15/23



The information and recommendations provided are based on the images presented by the referring veterinarian/sonographer. No evaluation can be communicated regarding pathology that was not visible in the image/video clips provided.

Thank you for this referral. If the clinical or image interpretation does not parallel your findings or if I can be of any further assistance please contact me.

Kathleen Sennello DVM,MS, Diplomate ACVIM (Small animal Internal Medicine)

kathleen.sennello@sonopath.com