

IMAGING PERFORMED BY

IntraPet.com



SonoPath

Clinical Sonography & Telectology

EDUCATIONAL TELECONSULTATION SERVICES™

1-800-838-4268 info@sonopath.com SonoPath.com

DATE PRESENTING CLINICAL SIGNS

3/15/22

Owners were out of town for about 2 weeks; adult children stayed home and cared for animals so no changes in routine during that time. They did think Moe was eating slightly less than usual. When owners got back they could tell she had marked weight loss, appetite decreased, and today she vomited three times. No diarrhea.

PATIENT

Moe Badeker

SPECIES

Feline

Current Medications: Buprenorphine, Cerenia.

Lab Results: BUN = 129, CREAT = 12.1, PHOS = 14.4, ALKP = 570, SDMA = 93.

Date of Previous IntraPet Ultrasound: No previous.

Sedation: Not required to complete full diagnostic ultrasound.

Stat Report: Not requested.

BREED

DSH

SEX

Spayed Female

ULTRASONOGRAPHIC EXAMINATION OF THE ABDOMEN

Urinary System

The urinary bladder is moderately distended with anechoic urine. The Bladder wall, trigone, ureteral papillae and visible urethra (to a depth of 2cm) appear normal with no evidence of wall thickening, mucosal irregularities, masses or cystic calculi.

AGE

10/14/12

The left kidney is large and very irregular in shape. It measures at a length of 5.12 cm with significant pyelectasia at 0.50 cm. The lateral cortical portion of the kidney is visible, but medially towards the hilus there is a large area of irregular hypoechoic and inflamed tissue creating a mass effect. This area is larger than 4.22 cm x 3.8 cm. It is difficult to differentiate a mass lesion in this region from echogenic fluid, and there are occasional small shadowing structures consistent with mineralization. Findings are most consistent with a renal mass effect and some degree of obstruction.

WEIGHT

11 Pounds

INTERPRETED BY

Kathleen Sennello DVM,
MS, Diplomate ACVIM
(Small Animal Internal
Medicine)

The right kidney has a normal shape and size (4.6 cm). Overall echogenicity is normal with adequate corticomedullary distinction and a typical 1:3 cortex:medulla ratio. There is no evidence of perinephric inflammation or effusion. There is no evidence of pyelectasia, nephroliths, infarcts or hydroureter. Renal vasculature is normal.

IMAGING PERFORMED BY

Rachel Brilhart RDMS

Adrenal Glands

The region of left adrenal (Cranial to left renal artery) is unremarkable but the adrenal is not distinctly visualized. No evidence of a mass effect.

HOSPITAL NAME

Animal Emergency
Hospital

The right adrenal gland is normal in size measuring 0.50 cm at the caudal pole. It is observed in its normal position between the cranial aspect of the right kidney and the caudal vena cava. It is normal in appearance (uniformly hypoechoic) and shape with no evidence of a mass effect.

REFERRING VET

Dr. Martinoli

Spleen

The spleen is subjectively normal in size, echotexture is homogenous, and the splenic capsule is smooth with no irregularities. The blood flow through the hilus and splenic parenchyma appears normal. No focal parenchymal abnormalities are visualized.

INVOICE

36193

Liver

The liver is subjectively normal in size, and echogenicity with smooth peripheral margins. The parenchyma is homogenous echotexture. The visible portions of the vasculature and biliary tract appear normal. No focal nodules or cystic lesions are observed.

The gallbladder lumen is moderately distended. The wall of the gall bladder is not thickened and has a smooth mucosal surface. Luminal contents are primarily anechoic. The cystic and common bile ducts are normal/not visible.

Gastrointestinal

The stomach contains minimal luminal contents. It measures at a normal thickness of <0.36cm with some variability due to the presence of rugal folds. The distinction of the gastric wall layers is adequate and there is no impression of reduced peristaltic activity. No masses or focal lesions were observed.

The visualized areas of duodenum, jejunum and ileum have a relatively uniform diameter with minimal fluid distension. Wall thickness is normal. Bowel loops follow a curvilinear path with distinct wall layering maintaining the typical 1:3 muscularis:mucosa layer ratio. The duodenum measured as normal (between 0.13-0.38cm in wall thickness) and the jejunum measured as normal (between 0.15-0.36cm.) Visualized peristalsis appears appropriate. There were no focal lesions consistent with obstruction or a mass effect observed.

The ileocecal junction was visualized and exhibited normal intact wall layering and is subjectively of normal thickness. Sections of colon are visualized with formed fecal material and gas shadowing distally. There is no observed focal or generalized colon wall thickening or loss of layering.

Pancreas

The pancreas is normal and isoechoic to surrounding mesentery. There is no evidence of nodules or cystic lesions. There is no evidence of regional mesenteric inflammation or fluid.

Free Abdomen

Evaluation of the peritoneal cavity did not reveal any evidence of effusion, or subjective lymphadenomegaly. The Medial iliac nodes appear normal and there was no evidence of a caudal aortic thrombus at the bifurcation. Hyperechoic mesentery is surrounding the area of the left kidney.

ULTRASONOGRAPHIC FINDINGS

- Abnormal dilated left kidney with a hypoechoic mass effect
- Echogenic mesentery surrounding the left kidney

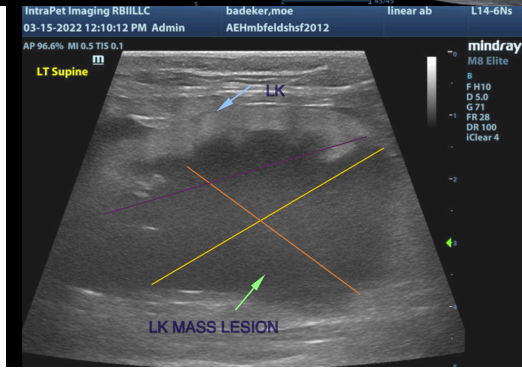
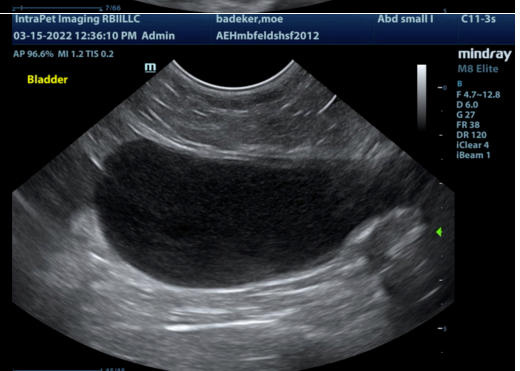
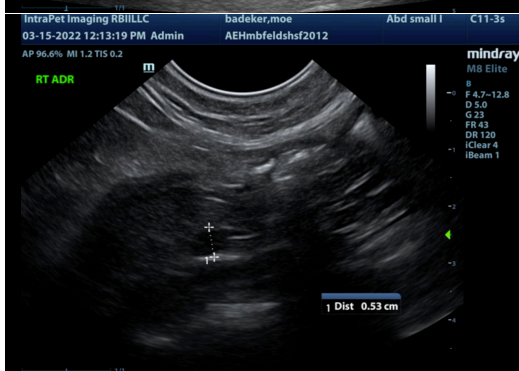
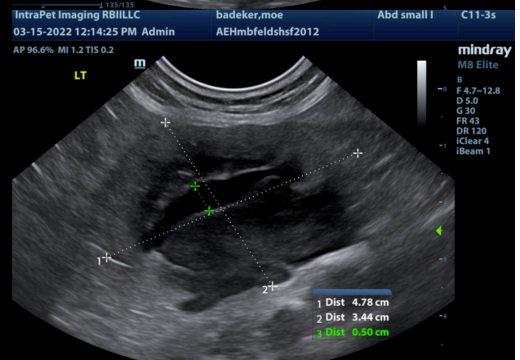
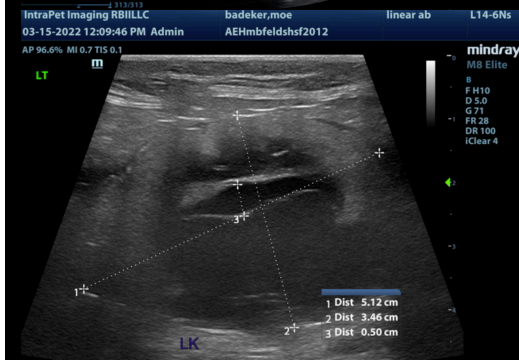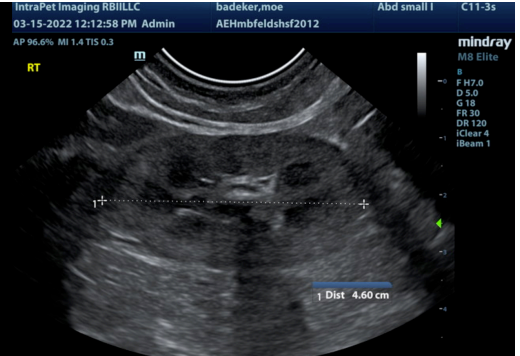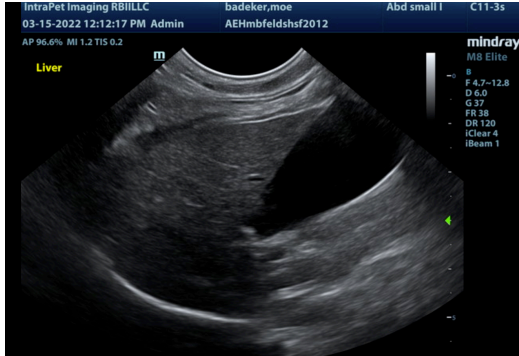INTERPRETATION OF THE FINDINGS & FURTHER RECOMMENDATIONS

The left kidney is large, irregular and abnormal with some evidence of fluid dilation. The mass effect is irregular and hypoechoic, and it is difficult to differentiate what could be echogenic fluid from tissue, and to what extent an obstructive process plays in the size and dimensions of this lesion. Ideally, a contrast CT scan would be performed to obtain better resolution and a more global view of this lesion in an attempt to determine if there is a surgical option, a focal obstruction, etc.

There is a significant azotemia present, which indicates that the function of the right kidney is impaired as well. No focal lesions were observed on the right kidney. Recommend blood pressure, urinalysis, culture, and diuresis with continued monitoring of both kidneys.

Consider three view thoracic radiographs to rule out concurrent thoracic disease/involvement.

If the azotemia can be improved with medical management, then I suspect your options moving forward include either a contrast CT scan or surgical explore to further evaluate the kidney. If possible, some means of preoperative evaluation/imaging would be ideal. A fine needle aspirate of the mass area of the kidney could be considered, but urine leakage would be a significant risk factor. Additionally, some of the hypoechoic areas of this mass lesion could represent hemorrhage.



The information and recommendations provided are based on the images presented by the referring veterinarian/sonographer. No evaluation can be communicated regarding pathology that was not visible in the image/video clips provided.

Thank you for this referral. If the clinical or image interpretation does not parallel your findings or if I can be of any further assistance please contact me.

Kathleen Sennello DVM,MS, Diplomate ACVIM (Small animal Internal Medicine)
kathleen.sennello@sonopath.com