

**DATE PRESENTING CLINICAL SIGNS**

3/14/23 Presented for trauma after being stepped on. On survey rads loss of detail in abdomen with caudal displacement of intestines. History of IBD and liver enzyme elevation.

PATIENT

Shadow Capirichio

Current Medications: Ursodiol, SAME, Methimazole
 Lab Results: 1/3/23- ALKP 463,m ALT 780, AST 330, Tbili 1.4
 Radiographs: Loss of detail and possible mass effect.
 Date of Previous IntraPet Ultrasound: 4/3/21. See attached.
 Sedation: Not required to complete full diagnostic ultrasound.
 Stat Report: Declined at this time.
 Imaging Performed By: Stephanie Warga RDCS, RVT.

SPECIES

Feline

BREED

DSH

SEX

Neutered Male

AGE

3/25/09

WEIGHT

8.18 Pounds

INTERPRETED BY

Kathleen Sennello DVM,
 MS, Diplomate ACVIM
 (Small Animal Internal
 Medicine)

HOSPITAL NAME

Hickory Vet Hospital

REFERRING VET

Dr. Lyle

INVOICE

45872

ULTRASONOGRAPHIC EXAMINATION OF THE ABDOMEN**Urinary System**

The urinary bladder is moderately distended with anechoic urine. The Bladder wall, trigone, ureteral papillae and visible urethra (to a depth of 2cm) appear normal with no evidence of wall thickening, mucosal irregularities, masses or cystic calculi.

The left kidney has a normal shape and size (4.22 cm). Overall echogenicity is slightly hyperechoic with poor corticomedullary distinction and a typical 1:3 cortex:medulla ratio. There is no evidence of focal perinephric inflammation or effusion. There is no evidence of pyelectasia, nephroliths, infarcts or hydroureter. Renal vasculature is normal.

The right kidney has a normal shape and size (4.14 cm). Overall echogenicity is slightly hyperechoic with poor corticomedullary distinction and a typical 1:3 cortex:medulla ratio. There is no evidence of focal perinephric inflammation or effusion. There is no evidence of pyelectasia, nephroliths, infarcts or hydroureter. Renal vasculature is normal.

Adrenal Glands

The left adrenal gland is normal in size measuring 0.33 cm at the caudal pole. It is observed in its normal position cranial to the left renal artery. It is normal in appearance (uniformly hypoechoic) and shape with no evidence of a mass effect.

The right adrenal gland is normal in size measuring 0.60 cm at the caudal pole. It is observed in its normal position between the cranial aspect of the right kidney and the caudal vena cava. It is normal in appearance (uniformly hypoechoic) and shape with no evidence of a mass effect.

Spleen

The spleen is subjectively normal/borderline "plump" (0.94 cm in width at the level of the hilus), echotexture is homogenous, and the splenic capsule is smooth with no irregularities. The blood flow through the hilus and splenic parenchyma appears normal. No focal parenchymal abnormalities are visualized.

Liver

The liver is subjectively normal in size, and echogenicity with irregular shape and irregular, almost nodular peripheral margins. The parenchyma is heterogenous in echotexture with subtle, indistinct focal mottling. The gallbladder and bile duct appear severely dilated and thickened. There is a small cystic structure visualized on the right side of the liver measuring 0.50 cm. Some of the irregular rounded margin regions create irregular "mass effects", but no definitive discrete mass is visualized.

The gallbladder lumen is severely distended. The wall of the gall bladder does not appear significantly thickened and has a smooth mucosal surface. Luminal contents consist of a moderate amount of non-

organized echogenic debris. The cystic and common bile duct appear significantly dilated and tortuous with evident echogenic intraluminal material, most consistent with debris, but tissue cannot be 100% ruled out. Proximally, the bile duct appears between 1.0-1.5 cm in diameter. More distally it appears to taper, and at the level of the duodenal papillae it measures at 0.50 cm.

Gastrointestinal

The stomach contains minimal luminal contents. It measures at a normal thickness of <0.36cm with some variability due to the presence of rugal folds. The distinction of the gastric wall layers is adequate and there is no impression of reduced peristaltic activity. No masses or focal lesions were observed.

The visualized areas of duodenum, jejunum and ileum have a uniform diameter with minimal fluid distension. Wall appears subjectively, mildly increased. Bowel loops follow a typical curvilinear path with distinct wall layering. Jejunum wall measures 0.26 cm. Visualized peristalsis appears appropriate. There were no focal lesions consistent with obstruction or a mass effect observed.

The ileocecal junction was visualized and exhibited normal intact wall layering and is subjectively of normal thickness. Sections of colon are visualized with formed fecal material and gas shadowing distally. There is no observed focal or generalized colon wall thickening or loss of layering.

Pancreas

The pancreas is large and hypoechoic to surrounding mesentery. There is no evidence of nodules or cystic lesions. There is evidence of regional mesenteric inflammation. Consistent with mild to moderate pancreatitis.

Free Abdomen

There is a large volume of anechoic free fluid. Visible/prominent mesenteric lymph nodes are noted measuring 0.34 cm and 0.28 cm. The omentum is diffusely hyperechoic.

PRIMARY FINDINGS

- Severely distended gallbladder and bile ducts with intraluminal material – Findings are concerning for possible chronic biliary obstruction (mass, stricture, inspissated bile, etc.).
- Severely heterogeneous, irregular liver – The liver appears irregular and almost nodular in some regions. This could be consistent with neoplasia, cirrhosis, regenerative nodules, etc.
- Hypoechoic, prominent pancreas with mildly surrounding hyperechoic mesentery – The pancreatic changes are most consistent with mild pancreatitis/pancreatic inflammation. Recommend fPLI testing and continued monitoring for improvement or possible development of a pancreatic abscess. Consider fine needle aspirate if not improving.
- Subjectively thickened small intestine – The mild small intestinal wall changes may be a normal variant in this patient or could be consistent with an inflammatory process (e.g., inflammatory bowel disease).
- Large volume free abdominal fluid – Recommend fluid analysis and cytology.

SECONDARY FINDINGS

- Decreased corticomedullary distinction in both kidneys – The bilateral renal findings are consistent with age-related change.

INTERPRETATION OF THE FINDINGS & FURTHER RECOMMENDATIONS

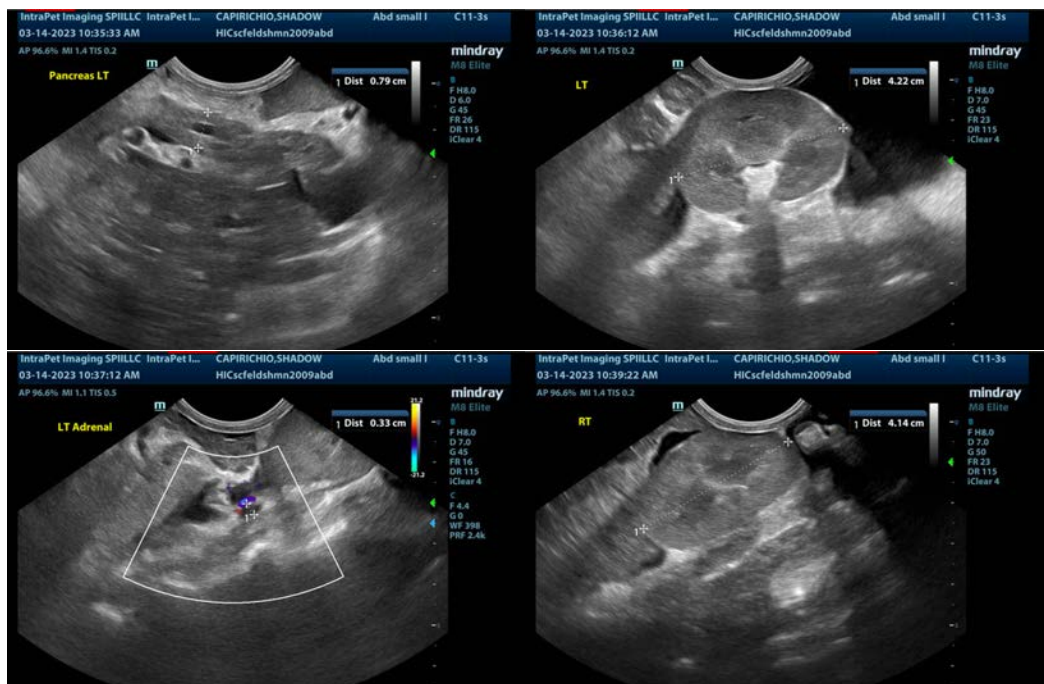
The gallbladder and the bile ducts appear severely dilated and tortuous. There is apparent intraluminal debris, but no obvious source or point of obstruction visualized. Additionally, there are some cystic lesions visualized in the liver, likely consistent with benign hepatic cysts. In general, the parenchyma appears irregular and severely heterogeneous, almost nodular in appearance. I would be concerned about the possibility of a neoplastic process causing progressive biliary stasis/obstruction. Additionally, the pancreas appears prominent and either mildly inflamed or remodeling due to previous inflammation, and the small bowel appears somewhat thickened, although this could be associated with edema due to the large amount of free abdominal fluid.

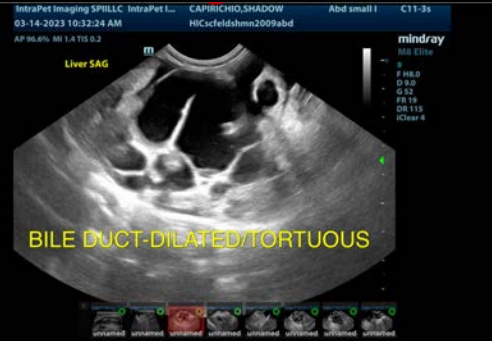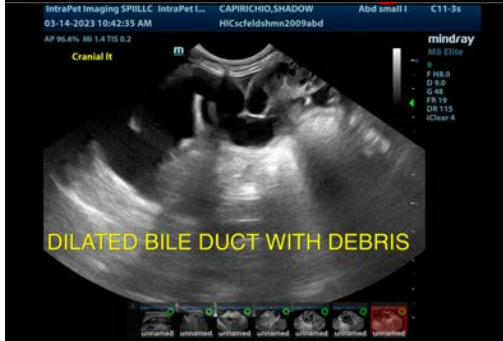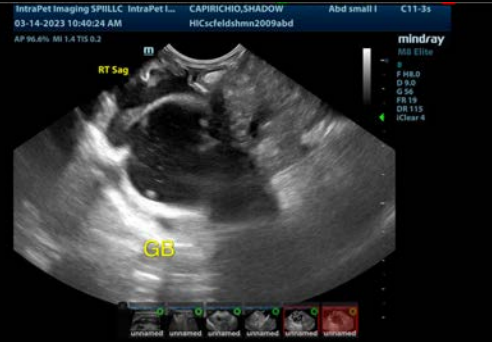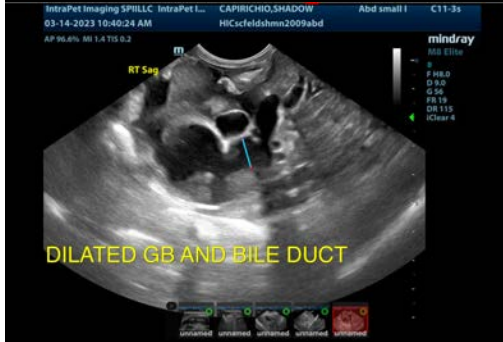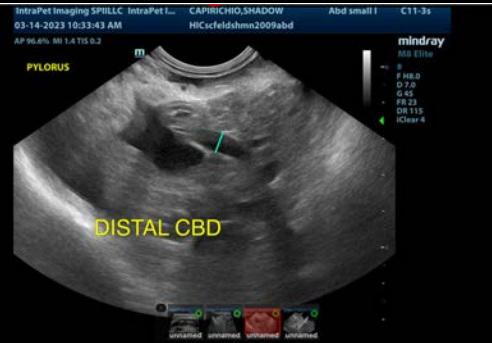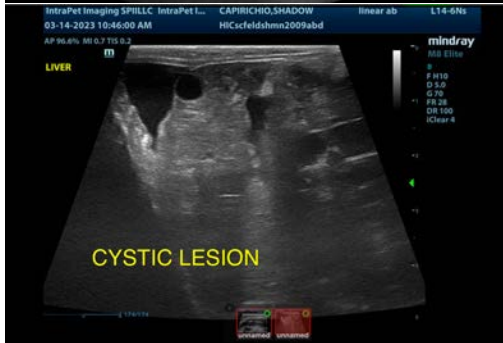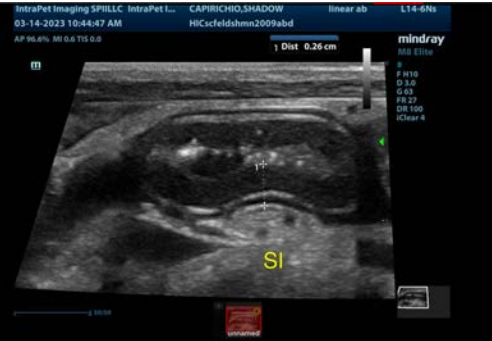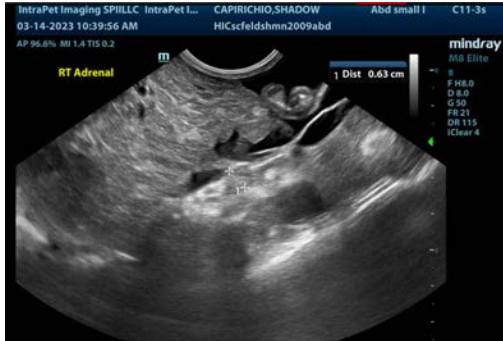Recommend sampling of the free abdominal fluid for fluid analysis and cytology, looking for abnormal cells, the possibility of bile peritonitis, or possibly evidence of cirrhosis/portal hypertension, etc.

Based on the appearance of today's scan, I suspect a contrast CT scan would be necessary to further evaluate this region, looking for a point of obstruction, and if surgical intervention is an option, additionally biopsies of the liver and cultures of the bile would likely be very helpful. If a less invasive route is desired, consider a fine needle aspirate of the liver, Ursodiol therapy, and close continued monitoring, but I'm concerned that this may be unlikely to significantly improve the situation.

Recommend three view thoracic radiographs to evaluate for possible concurrent thoracic disease/involvement.

The changes observed on today's scan show significant progression as compared to the previous scan 4/20/21.





The information and recommendations provided are based on the images presented by the referring veterinarian/sonographer. No evaluation can be communicated regarding pathology that was not visible in the image/video clips provided.

Thank you for this referral. If the clinical or image interpretation does not parallel your findings or if I can be of any further assistance please contact me.

Kathleen Sennello DVM,MS, Diplomate ACVIM (Small animal Internal Medicine)
kathleen.sennello@sonopath.com