

**DATE PRESENTING CLINICAL SIGNS**

3/14/23

Patient has cushing dz. and has been controlled for last 2 years with Vetroyl - acute onset on Sunday of diarrhea, not eating or drinking- and appears depressed.

PATIENT

Khloi Cullison

Current Medications: Vetroyl 30 mg 1 tab PO SID (2 years), Ursodiol 80mg/ml 1 ml PO BID (2 years), Amlodipine 2.5 mg 1/2 tab PO BID (1 year), Enalapril 5mg 1 tab PO BID (1 year)
Lab Results: Urine: Presence of Cocci and Rods. Chem: SDMA 38 Phos: 11.8 ALT - unable to register ALKP >2000 GGT 88 TBLI 4.2

SPECIES

Canine

Radiographs: See attached.
Date of Previous IntraPet Ultrasound: 1/13/22. See attached.
Sedation: Not required to complete full diagnostic ultrasound.
Stat Report: Not requested.

BREED

Shih Tzu X

Imaging Performed By: Rachel Brillhart, RDMS.

ULTRASONOGRAPHIC EXAMINATION OF THE ABDOMEN**SEX**

Spayed Female

Urinary System

The urinary bladder is moderately distended with anechoic urine. The Bladder wall, trigone, ureteral papillae and visible urethra (to a depth of 2cm) appear normal with no evidence of wall thickening, mucosal irregularities, masses or cystic calculi.

AGE

2/16/12

The left kidney has a normal shape and size (4.76 cm) with a small non-obstructive nephrolith measuring 0.25 cm. Overall echogenicity is slightly hyperechoic with poor corticomedullary distinction and a typical 1:3 cortex:medulla ratio. There is no evidence of focal perinephric inflammation or effusion. There is no evidence of pyelectasia, infarcts or hydroureter. Renal vasculature is normal.

WEIGHT

18 Pounds

The right kidney has a normal shape and size (4.78 cm). Overall echogenicity is slightly hyperechoic with poor corticomedullary distinction and a typical 1:3 cortex:medulla ratio. There is no evidence of focal perinephric inflammation or effusion. There is no evidence of pyelectasia, nephroliths, infarcts or hydroureter. Renal vasculature is normal.

INTERPRETED BY

Kathleen Sennello DVM,
MS, Diplomate ACVIM
(Small Animal Internal
Medicine)

Adrenal Glands

The left adrenal gland is large in size and slightly irregular in appearance, measuring 0.89 cm at the cranial pole, 0.89 cm at the caudal pole, and 2.4 cm in length. It is observed in its normal position cranial to the left renal artery. It is slightly irregular in shape and there is a mildly hyperechoic region in the cranial pole. The appearance of the left adrenal is stable from the previous evaluation on 1/20/22.

HOSPITAL NAME

Celebrie Vet Hospital

REFERRING VET

Dr. Garrett

The right adrenal gland is large and irregular, measuring 1.98 cm at the cranial pole, 1.28 cm at the caudal pole, and 4.38 cm in length. It is observed in its normal position between the cranial aspect of the right kidney and the caudal vena cava. It is abnormal in appearance in that there is a somewhat nodular. This irregular shape is stable from the previous scan on 1/20/22. In some views there is the suggestion of a rounded hypoechoic structure with heterogeneous lumen, concerning for possible early vascular invasion. This is not evident on all images.

INVOICE

45873

Spleen

The spleen is subjectively normal in size, echotexture is homogenous, and the splenic capsule is smooth with no irregularities. The blood flow through the hilus and splenic parenchyma appears normal. No focal parenchymal abnormalities are visualized.

Liver

The liver is subjectively normal in size, and echogenicity with smooth peripheral margins. The parenchyma is heterogenous in echotexture with subtle, indistinct focal mottling. The visible portions of the vasculature and biliary tract appear normal. No focal nodules or cystic lesions are observed.

The gallbladder lumen is large and distended with a moderate amount of intraluminal echogenic debris with some thickening and irregularity of the gallbladder wall, measuring 0.36 cm, with some mild mucosal stranding. The appearance of the gallbladder is consistent with a gallbladder mucocele, but there is some concern for mild surrounding inflammation.

Gastrointestinal

The stomach contains minimal luminal contents. It measures at a normal thickness of <0.7cm with some variability due to the presence of rugal folds. The distinction of the gastric wall layers is adequate and there is no impression of reduced peristaltic activity. No masses or focal lesions were observed.

The visualized areas of duodenum, jejunum and ileum have a relatively uniform diameter with minimal fluid distension. Wall thickness is normal. Bowel loops follow a curvilinear path with distinct wall layering maintaining the typical 1:3 muscularis:mucosa layer ratio. Duodenum wall measured 0.35 cm. Jejunum wall measures 0.32 cm. Visualized peristalsis appears appropriate. There were no focal lesions consistent with obstruction or a mass effect observed.

The ileocecal junction was visualized and exhibited normal intact wall layering and is subjectively of normal thickness. Sections of colon are visualized with formed fecal material and gas shadowing distally. There is no observed focal or generalized colon wall thickening or loss of layering.

Pancreas

The pancreas is prominent and mottled compared to the surrounding isoechoic mesentery. There is no evidence of nodules or cystic lesions. There is no evidence of regional mesenteric inflammation or fluid.

Free Abdomen

Evaluation of the peritoneal cavity did not reveal any evidence of effusion, or subjective lymphadenomegaly. The Medial iliac nodes appear normal and there was no evidence of a caudal aortic thrombus at the bifurcation. The omentum is of normal uniform echogenicity.

PRIMARY FINDINGS

- Bilateral adrenomegaly with irregular shaped adrenal glands – The size, shape and appearance of the adrenals is relatively similar to the previous scan 14 months ago.
- Questionable early vascular invasion of the right adrenal gland – The appearance of this lesion is subtle and not reproducible in all views. Recommend contrast CT scan or continued monitoring with ultrasound.
- Heterogeneous liver – The diffuse hepatic changes are non-specific and could be consistent with vacuolar hepatopathy, nodular hyperplasia, inflammatory/immune-mediated disease, fibrosis, extramedullary hematopoiesis, toxic hepatopathy (e.g., copper), infiltrative neoplasia (less likely) or other hepatopathy.
- Large distended gallbladder mucocele with mild surrounding inflammation – Findings are concerning for a borderline surgical gallbladder mucocele.

SECONDARY FINDINGS

- Decreased corticomedullary distinction in both kidneys – The bilateral renal findings are consistent with age-related change.
- Prominent, mottled pancreas – The pancreatic changes are most consistent with age-related parenchymal remodeling, potentially secondary to a prior inflammatory episode, early fibrosis or chronic pancreatitis.

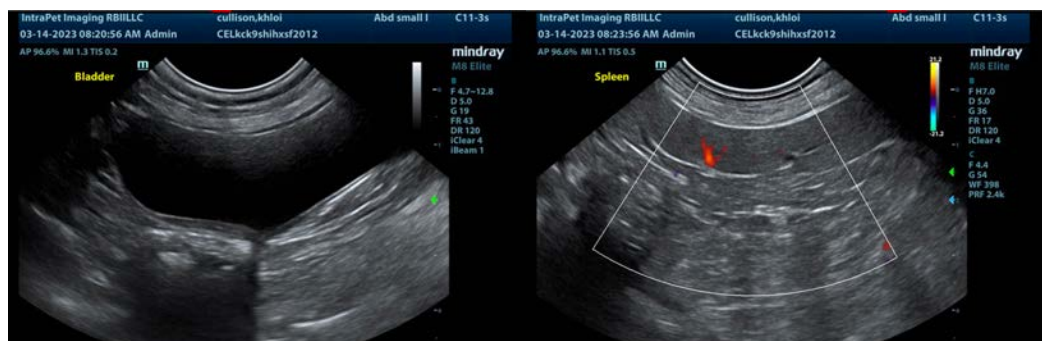
INTERPRETATION OF THE FINDINGS & FURTHER RECOMMENDATIONS

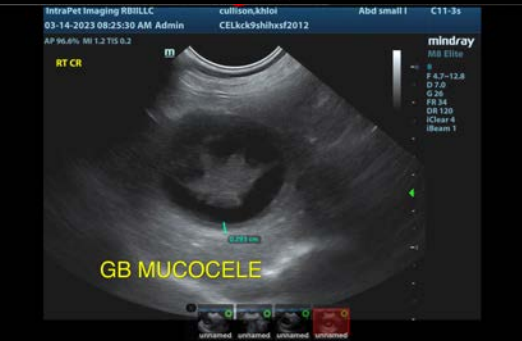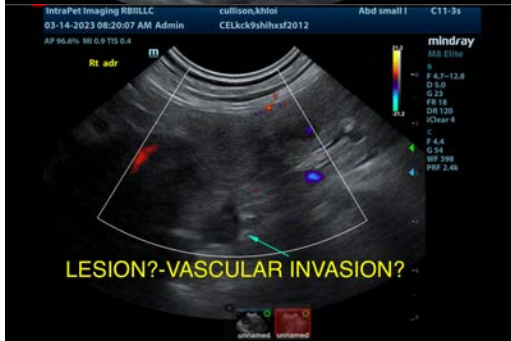
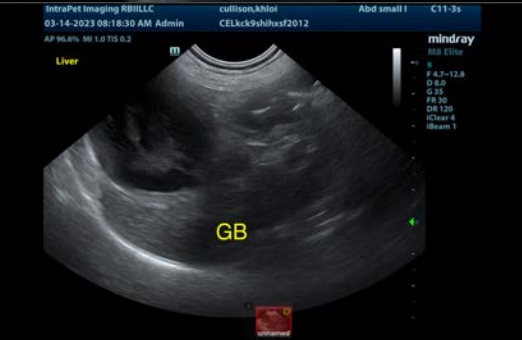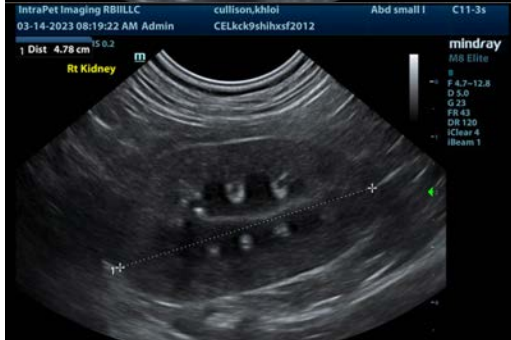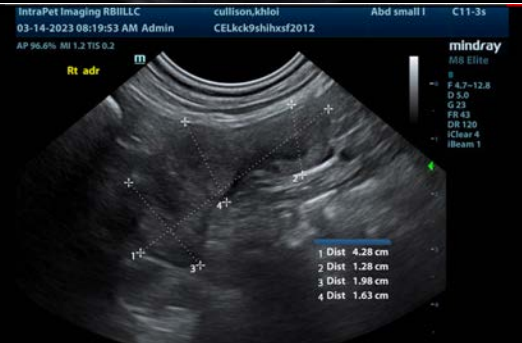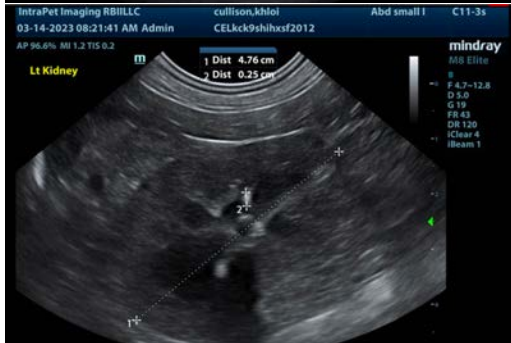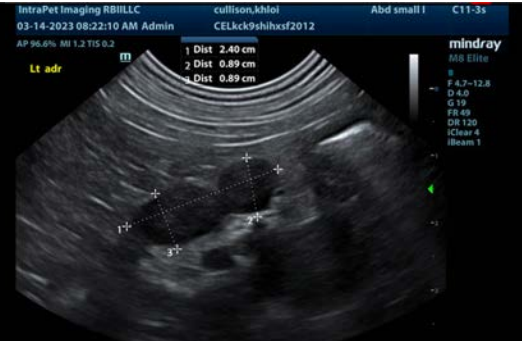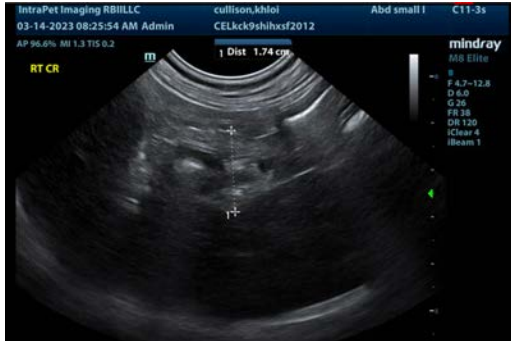The gallbladder appears distended with a mildly thickened, irregular gallbladder wall and changes consistent with a gallbladder mucocele. Additionally, the surrounding tissue mildly hyperechoic with no fluid visualized. These changes are concerning for acute cholecystitis and a gallbladder mucocele. Given the bloodwork changes and the patient's clinical status, this could represent a surgical lesion.

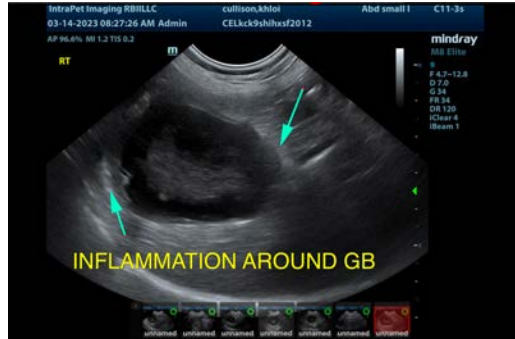
The majority of the other abnormalities described are stable from the previous exam from approximately 14 months ago. The only possible concern is an irregular structure visualized associated with the right adrenal gland. This could represent anatomic variation, imaging artifact, etc., but there is concern for the appearance of possible early vascular invasion. Options moving forward would include:

- In an ideal situation, a contrast CT scan of the abdomen would be performed to further evaluate the gallbladder and right adrenal prior to considering surgery.
- If a contrast CT scan is not possible, consider referral to a veterinary surgeon for likely cholecystectomy, liver biopsy, and possible gross evaluation of the right adrenal(?).
- If surgical intervention is not an option, consider medical management with antibiotics, pain medications, etc., and close monitoring with ultrasound (recheck in 24-48 hours).
- Recommend three view thoracic radiographs to evaluate for possible concurrent thoracic disease/involvement.
- If no further measures are taken to evaluate the right adrenal, consider recheck ultrasound in approximately two months.

It is not 100% certain if the symptoms described are secondary to the gallbladder changes, although the liver enzyme elevations are very suspicious. Consider an ACTH stimulation test to screen for low cortisol levels. If surgery is considered, a physiologic dose of steroids should be administered to help with the stress of illness and surgery.







The information and recommendations provided are based on the images presented by the referring veterinarian/sonographer. No evaluation can be communicated regarding pathology that was not visible in the image/video clips provided.

Thank you for this referral. If the clinical or image interpretation does not parallel your findings or if I can be of any further assistance please contact me.

Kathleen Sennello DVM,MS, Diplomate ACVIM (Small animal Internal Medicine)
kathleen.sennello@sonopath.com