


**DATE PRESENTING CLINICAL SIGNS**

3/13/26

**Patient History:** Started with yellow, mushy diarrhea Monday/Tuesday after eating other dogs' food in addition to his own - Progressed to vomiting blood Wednesday night - Anorexic yesterday and today, ate one milk bone treat today - Still playing with other dogs and going on walks - History of eating paper and tissues - Currently staying with client's daughter's two Jack Russell terriers (one 8-month-old puppy, one 12-year-old) - Seen by regular veterinarian today for blood work and x-rays - Regular veterinarian administered Cerenia injection and dispensed Cerenia and metronidazole; client has not yet given tonight's dose.

**PATIENT**

Murphy Mann

**SPECIES**

Canine

**Current Medications:** See above.

**Labwork Results:** Labwork attached, reported as: High Elevated Amylase (3605), Precision PSL (4900), Mild Elevation of ALP 147

**BREED**
Cavalier King Charles  
Spaniel x

**Date of Previous IntraPet Ultrasound:** No previous.

**Sedation:** Not required to complete full diagnostic ultrasound.

**Stat Report:** Not requested.

**Imaging Performed by:** Rachel Brillhart, RDMS.

**SEX**

Neutered Male

**ULTRASONOGRAPHIC EXAMINATION OF THE ABDOMEN**
**Urinary System**

The urinary bladder is moderately distended with anechoic urine. The Bladder wall, trigone, ureteral papillae and visible urethra (to a depth of 2cm) appear normal with no evidence of wall thickening, mucosal irregularities, masses or cystic calculi.

**AGE**

12/18/20

The prostate is normal in size (0.69 cm) and shape for this neutered male dog. The parenchyma is homogenous and the external margins are smooth. The prostatic urethra appears normal with no evidence of irregularity, invasion, mass effect or calculi.

**WEIGHT**

25 lbs

**INTERPRETED BY**
Kathleen Sennello DVM,  
MS, Diplomate ACVIM  
(Small Animal Internal  
Medicine)

The left kidney has a normal shape and size (4.69 cm). Overall echogenicity is normal with adequate corticomedullary distinction and a typical 1:3 cortex:medulla ratio. There is no evidence of focal perinephric inflammation or effusion. There is no evidence of pyelectasia, nephroliths, infarcts or hydronephrosis. Renal vasculature is normal.

**HOSPITAL NAME**
Animal Emergency  
Hospital

The right kidney has a normal shape and size (4.57 cm). Overall echogenicity is normal with adequate corticomedullary distinction and a typical 1:3 cortex:medulla ratio. There is no evidence of focal perinephric inflammation or effusion. There is no evidence of pyelectasia, nephroliths, infarcts or hydronephrosis. Renal vasculature is normal.

**REFERRING VET**

Dr. Campbell

**Adrenal Glands**

The left adrenal gland is normal in size measuring 0.62 cm at the cranial pole and 0.65 cm at the caudal pole. It is observed in its normal position cranial to the left renal artery. It is normal in appearance (uniformly hypoechoic) and shape with no evidence of a mass effect.

**INVOICE**

73663

The right adrenal gland is normal in size measuring 0.83 cm at the cranial pole and 0.57 cm at the caudal pole. It is observed in its normal position between the cranial aspect of the right kidney and the caudal vena cava. It is normal in appearance (uniformly hypoechoic) and shape with no evidence of a mass effect.

**Spleen**

The spleen is subjectively normal in size (1.33 cm in width at the level of the hilus), echotexture is homogenous, and the splenic capsule is smooth with no irregularities. The blood flow through the hilus and

splenic parenchyma appears normal. There is a hypoechoic mixed echogenicity nodule visualized towards the caudal aspect of the spleen measuring 1.03 cm x 0.87 cm.

### ***Liver***

The liver is subjectively normal in size, and echogenicity with smooth peripheral margins. The parenchyma is homogenous echotexture. The visible portions of the vasculature and biliary tract appear normal. No focal nodules or cystic lesions are observed.

The gall bladder lumen is moderately distended. The wall of the gall bladder is not thickened and has a smooth mucosal surface. Luminal contents are mild and likely incidental at this time. The cystic and common bile ducts are normal/not visible.

### ***Gastrointestinal***

The stomach contains mild fluid. It measures at a normal thickness of <0.7cm with some variability due to the presence of rugal folds. The distinction of the gastric wall layers is adequate and there is no impression of reduced peristaltic activity. No masses or focal lesions were observed.

The visualized areas of duodenum, jejunum and ileum have a relatively uniform diameter with minimal to mild fluid/gas distension. Wall thickness is normal. Bowel loops follow a curvilinear path with distinct wall layering maintaining the typical 1:3 muscularis:mucosa layer ratio. Duodenum wall measures 0.35 cm. Jejunum wall measures 0.23 cm. Visualized peristalsis appears appropriate. There were no focal lesions consistent with obstruction or a mass effect observed.

Sections of colon are visualized with a scant amount of non-formed fecal material and gas. The descending colon wall appears somewhat thickened, measuring 0.35 cm with intact wall layering.

### ***Pancreas***

The right limb of the pancreas is large and hypoechoic to surrounding mesentery. There is no evidence of nodules or cystic lesions. There is evidence of regional mesenteric inflammation. Consistent with moderate pancreatitis.

### ***Free Abdomen***

Evaluation of the peritoneal cavity did not reveal any evidence of effusion. No significant lymphadenopathy noted. The omentum is hyperechoic and reactive in the right cranial abdomen around the pancreas.

### ***Other***

The right auricle and pericardium were visualized and were unremarkable. No obvious pathology is visualized. If cardiac function evaluation is desired a full echocardiogram is warranted.

## **ULTRASONOGRAPHIC FINDINGS**

- Single hypoechoic, mixed echogenicity splenic nodule – There is a non-cavitated, hypoechoic splenic nodule visualized. Differentials include lymphoid hyperplasia, extramedullary hematopoiesis, infiltrative neoplasia, inflammation, other. Cytology or histopathology would be necessary to get a definitive diagnosis.
- Pancreatic changes most consistent with moderate pancreatitis, particularly in the right limb.
- Gastric and small intestinal changes most consistent with mild gastroenteritis.

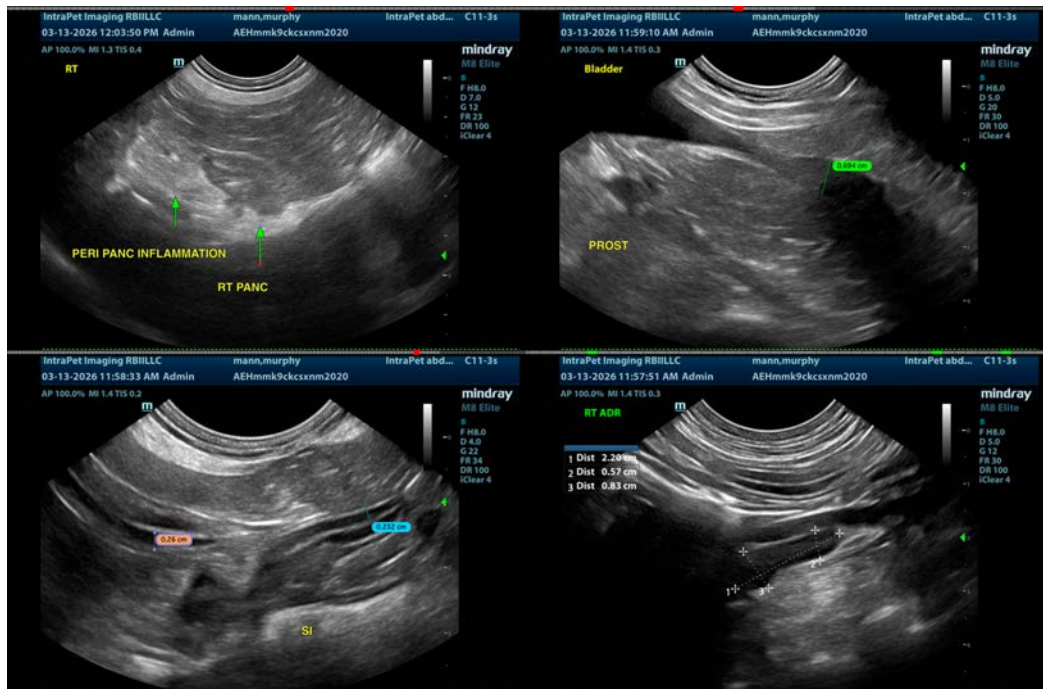
- Thickened descending colon wall with intact wall layering – Findings are most consistent with colitis. Neoplastic infiltration is much less likely.

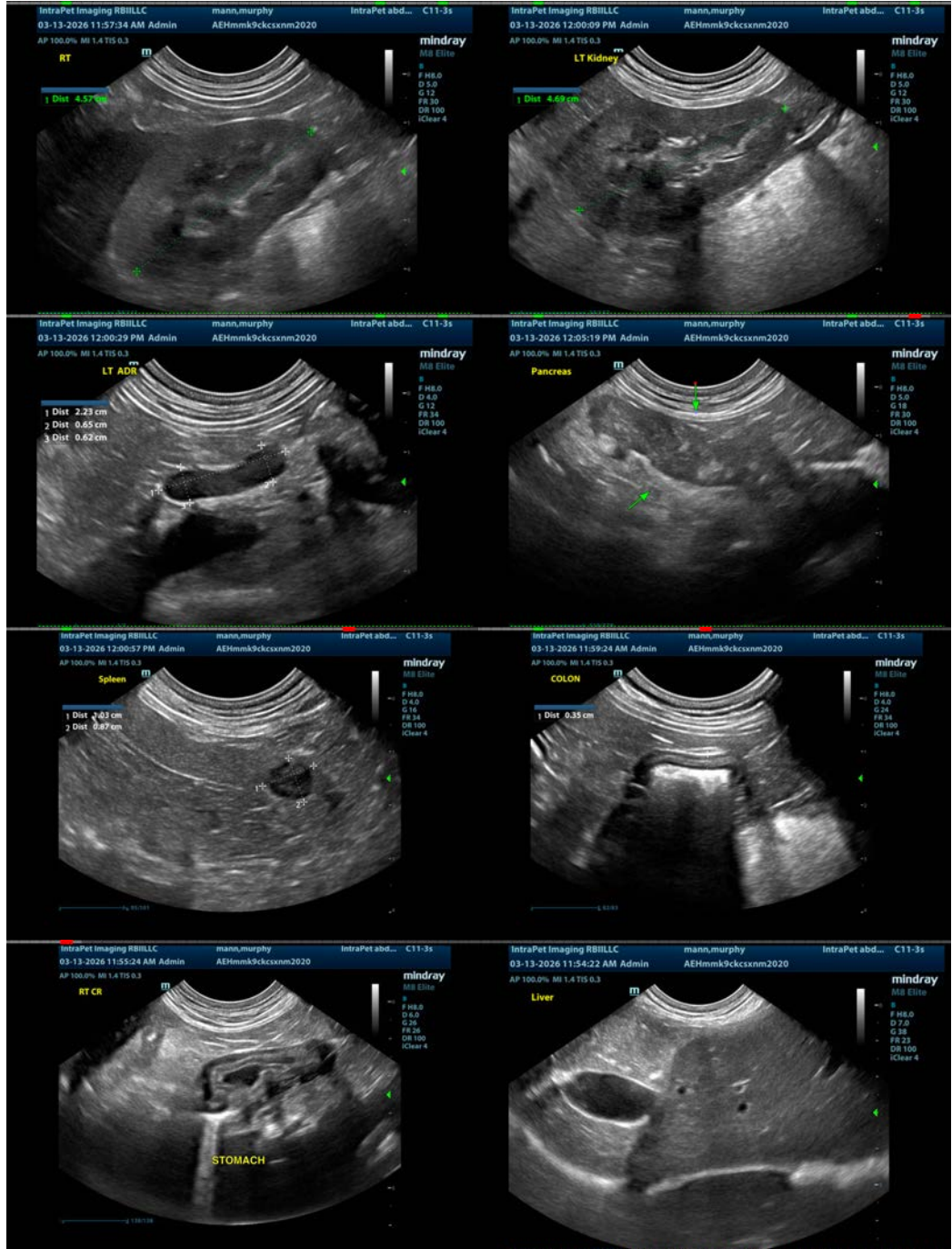
### INTERPRETATION OF THE FINDINGS & FURTHER RECOMMENDATIONS

The pancreas (particularly the right limb) is large and hypoechoic with surrounding reactive mesentery, most consistent with moderate pancreatitis. There is significant inflammation surrounding the pancreas and caudal to the stomach. There are mild gastric and small intestinal changes most consistent with secondary gastroenteritis. Recommend aggressive treatment for pancreatitis and subsequent gastroenterocolitis with close continued monitoring. If symptoms are persistent, consider repeat imaging, as partially obstructive foreign material associated with dietary indiscretion, etc. cannot be definitively ruled out.

There is a small hypo/mixed echogenicity nodule in the spleen. At this time this is likely incidental, but further evaluation is warranted. This could represent a benign or neoplastic lesion. Options moving forward would include a fine needle aspirate or continued monitoring with ultrasound.

Recommend three view thoracic radiographs to evaluate for possible concurrent thoracic disease/involvement (disregard if this has already been done).





**The information and recommendations provided are based on the images presented by the referring veterinarian/sonographer. No evaluation can be communicated regarding pathology that was not visible in the image/video clips provided.**

Thank you for this referral. If the clinical or image interpretation does not parallel your findings or if I can be of any further assistance please contact me.

Kathleen Sennello DVM,MS, Diplomate ACVIM (Small animal Internal Medicine)  
info@sonopath.com