



## PATIENT

Scooby Robertshaw

## SPECIES

Canine

## BREED

German Shepherd x

## SEX

Neutered Male

## AGE

3 Years

## WEIGHT

30 kg

## INTERPRETED BY

Kathleen Sennello DVM,  
MS, Diplomate ACVIM  
(Small Animal Internal  
Medicine)

## IMAGING PERFORMED BY

Dr. Sarah Barthelemy

## HOSPITAL NAME

Woodlands Veterinary  
Hospital

## REFERRING VET

Dr. Leboldus

## INVOICE

73595

## DATE

3/11/26

## PRESENTING CLINICAL SIGNS

Presented to ER over weekend for vomiting which included grass, passing grass in stool - outpatient care provided and improved dramatically. Vomiting has now acutely relapsed, vomiting through cerenia and ADR.

## ULTRASONOGRAPHIC EXAMINATION OF THE ABDOMEN

### Urinary System

The urinary bladder is moderately distended with anechoic urine. The Bladder wall, trigone, ureteral papillae and visible urethra (to a depth of 2cm) appear normal with no evidence of wall thickening, mucosal irregularities, masses or cystic calculi.

Prostate is normal in size (1.3 cm), echotexture and echogenicity for a neutered male.

The left kidney has a normal shape and size (6.92 cm). Overall echogenicity is normal with adequate corticomedullary distinction and a typical 1:3 cortex:medulla ratio. There is no evidence of focal perinephric inflammation or effusion. There is no evidence of pyelectasia, nephroliths, infarcts or hydroureter. Renal vasculature is normal.

The right kidney has a normal shape and size (6.53 cm). Overall echogenicity is normal with adequate corticomedullary distinction and a typical 1:3 cortex:medulla ratio. There is no evidence of focal perinephric inflammation or effusion. There is no evidence of pyelectasia, nephroliths, infarcts or hydroureter. Renal vasculature is normal.

### Adrenal Glands

The left adrenal gland is normal in size measuring 0.55 cm at the cranial pole and 0.66 cm at the caudal pole. It is observed in its normal position cranial to the left renal artery. It is normal in appearance (uniformly hypoechoic) and shape with no evidence of a mass effect.

The right adrenal gland is normal in size measuring 0.64 cm at the cranial pole and 0.74 cm at the caudal pole. It is observed in its normal position between the cranial aspect of the right kidney and the caudal vena cava. It is normal in appearance (uniformly hypoechoic) and shape with no evidence of a mass effect.

### Spleen

The spleen is subjectively normal in size (1.31 cm), echotexture is homogenous, and the splenic capsule is smooth with no irregularities. The blood flow through the hilus and splenic parenchyma appears normal. No focal parenchymal abnormalities are visualized.

### Liver

The liver is subjectively normal in size, and echogenicity with smooth peripheral margins. The parenchyma is homogenous echotexture. The visible portions of the vasculature and biliary tract appear normal. No focal nodules or cystic lesions are observed.

The gall bladder lumen is moderately distended. The wall of the gall bladder is not thickened and has a smooth mucosal surface. Luminal contents are mild and likely incidental at this time. The cystic and common bile ducts are normal/not visible.

**PATIENT**

Scooby Robertshaw

**SPECIES**

Canine

**BREED**

German Shepherd x

**SEX**

Neutered Male

**AGE**

3 Years

**WEIGHT**

30 kg

**INTERPRETED BY**

Kathleen Sennello DVM,  
MS, Diplomate ACVIM  
(Small Animal Internal  
Medicine)

**IMAGING  
PERFORMED BY**

Dr. Sarah Barthelemy

**HOSPITAL NAME**

Woodlands Veterinary  
Hospital

**REFERRING VET**

Dr. Leboldus

**INVOICE**

73595

**DATE**

3/11/26

***Gastrointestinal***

The stomach contains a large amount of shadowing ingesta. Some areas of the gastric wall appear normal. In the region of the pylorus the gastric wall appears thickened at 0.95 cm. The distinction of the gastric wall layers is adequate and there is no impression of reduced peristaltic activity. Shadowing ingesta interferes with full evaluation of the stomach. The pylorus appears patent with a thickened wall.

The visualized areas of duodenum, jejunum and ileum have a relatively uniform diameter with minimal fluid distension. Wall thickness is normal. Bowel loops follow a curvilinear path with distinct wall layering maintaining the typical 1:3 muscularis:mucosa layer ratio. Duodenum wall measures 0.54 cm. Jejunum wall measures 0.39 cm. Visualized peristalsis appears appropriate. There were no focal lesions consistent with obstruction or a mass effect observed.

The ileocecal junction was visualized and exhibited normal intact wall layering and is subjectively of normal thickness. Sections of colon are visualized with non-formed fecal material and gas shadowing distally. There is no observed focal or generalized colon wall thickening or loss of layering.

***Pancreas***

The pancreas is normal and isoechoic to surrounding mesentery. There is no evidence of nodules or cystic lesions. There is no evidence of regional mesenteric inflammation or fluid.

***Free Abdomen***

Evaluation of the peritoneal cavity did not reveal any evidence of effusion. No significant lymphadenopathy. A mesenteric lymph node is visualized measuring 0.38 cm. An iliac lymph node measures 0.45 cm. The omentum is hyperechoic around the pyloric region of the stomach.

**ULTRASONOGRAPHIC FINDINGS**

- Large, distended stomach with a large amount of shadowing ingesta, wall thickening, and inflammation at the level of the pylorus – Correlate with feeding history. If the patient was adequately fasted, this is concerning for possible ingested foreign material. A definitive obstruction is not visualized. The wall thickening is most consistent with gastritis, although early infiltrative change cannot be definitively ruled out.

**INTERPRETATION OF THE FINDINGS & FURTHER RECOMMENDATIONS**

The stomach is significantly distended with soft shadowing material, concerning for ingesta. In the region of the pylorus the gastric wall appears thickened and there is surrounding inflammation concerning for significant gastritis. Options at this time would include more aggressive supportive care and reevaluation of the stomach in 12-24 hours, looking for gradual improvement (radiographs, ultrasound, etc.), or you could consider upper GI endoscopy to further evaluate gastric contents and determine if surgery is warranted and if the contents can be removed. Consider reevaluation of the pyloric region of the stomach in the future to ensure that the gastric wall thickening resolves with resolution of the shadowing gastric material.



**PATIENT**

Scooby Robertshaw

**SPECIES**

Canine

**BREED**

German Shepherd x

**SEX**

Neutered Male

**AGE**

3 Years

**WEIGHT**

30 kg

**INTERPRETED BY**

Kathleen Sennello DVM,  
MS, Diplomate ACVIM  
(Small Animal Internal  
Medicine)

**IMAGING  
PERFORMED BY**

Dr. Sarah Barthelemy

**HOSPITAL NAME**

Woodlands Veterinary  
Hospital

**REFERRING VET**

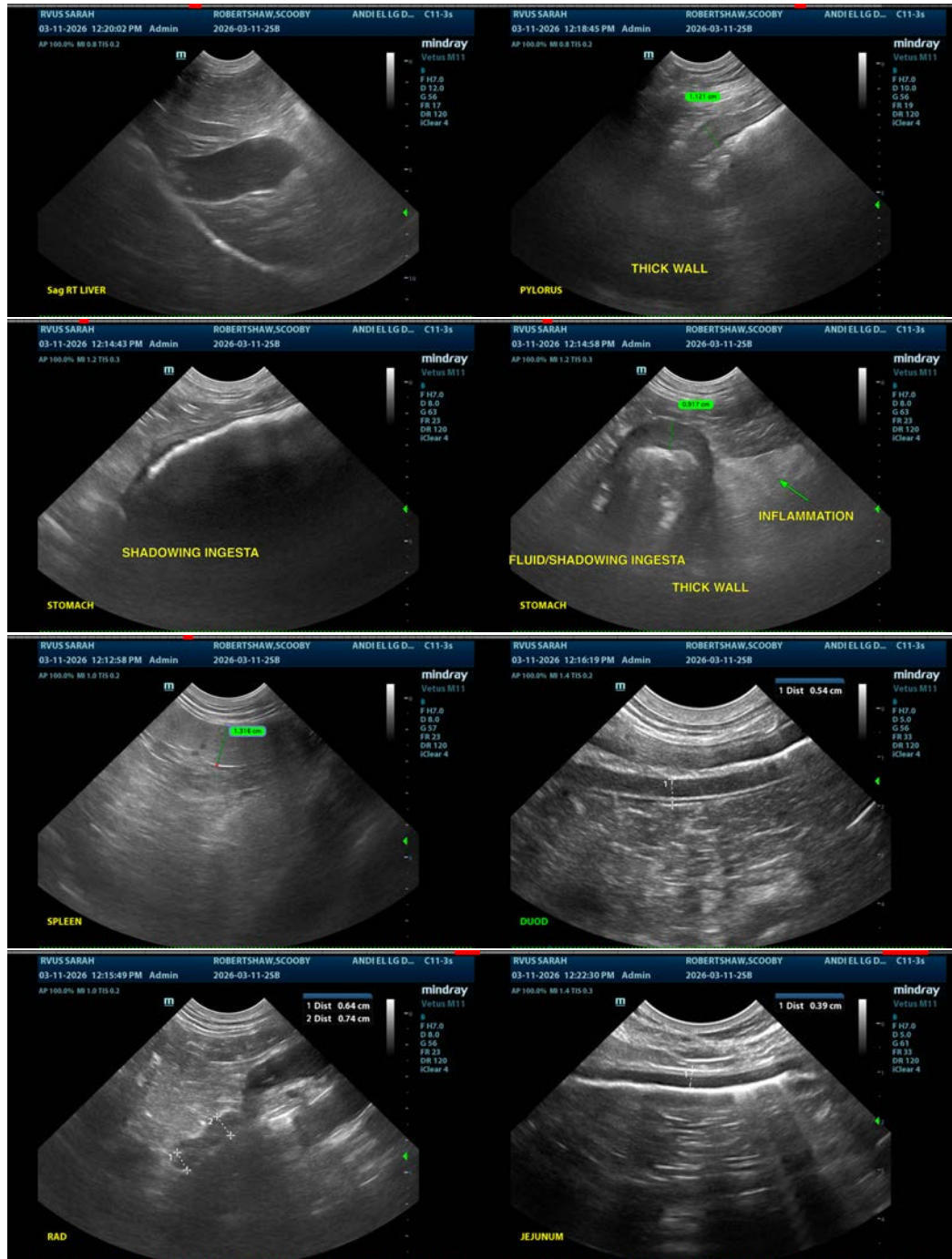
Dr. Leboldus

**INVOICE**

73595

**DATE**

3/11/26





## PATIENT

Scooby Robertshaw

## SPECIES

Canine

## BREED

German Shepherd x

## SEX

Neutered Male

## AGE

3 Years

## WEIGHT

30 kg

## INTERPRETED BY

Kathleen Sennello DVM,  
MS, Diplomate ACVIM  
(Small Animal Internal  
Medicine)

## IMAGING PERFORMED BY

Dr. Sarah Barthelemy

## HOSPITAL NAME

Woodlands Veterinary  
Hospital

## REFERRING VET

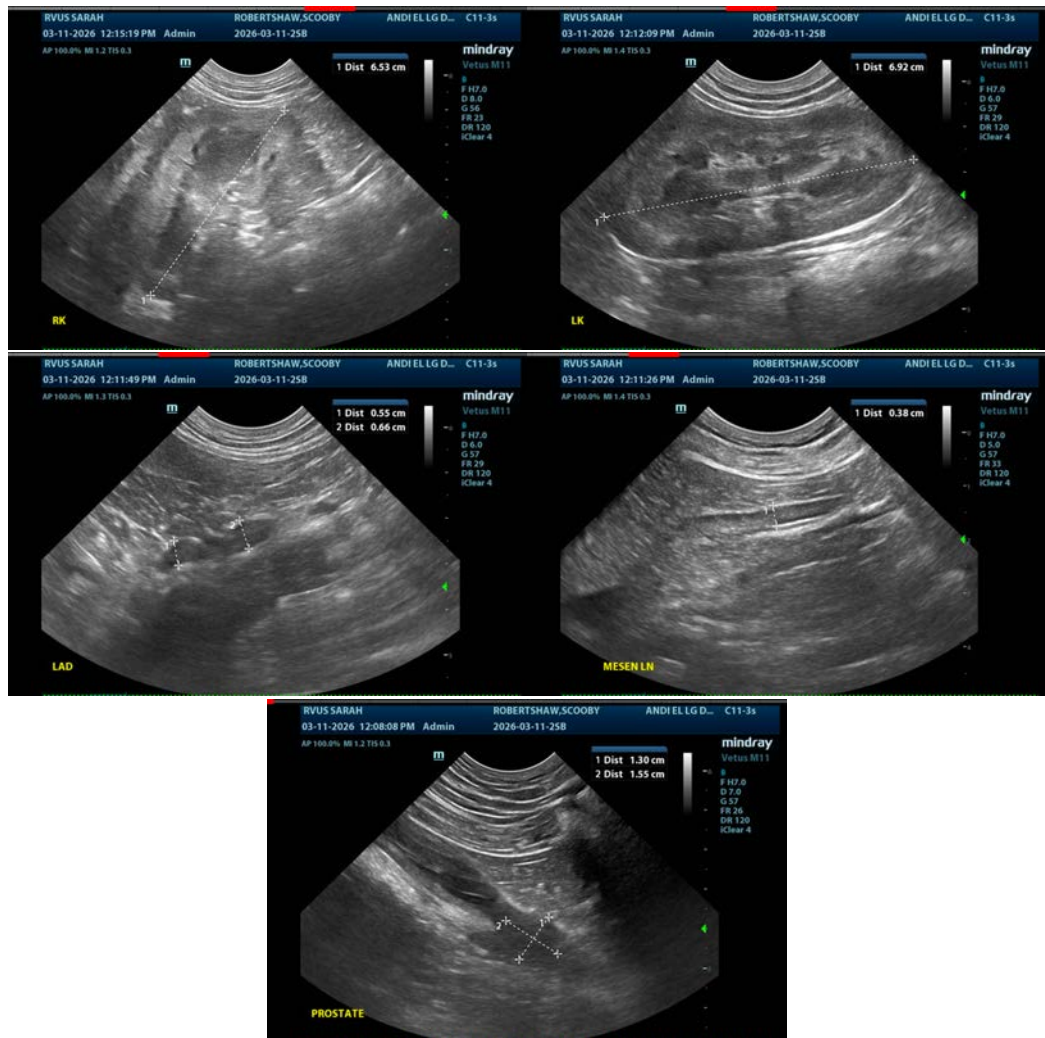
Dr. Leboldus

## INVOICE

73595

## DATE

3/11/26



The information and recommendations provided are based on the images presented by the referring veterinarian/sonographer. No evaluation can be communicated regarding pathology that was not visible in the image/video clips provided.

Thank you for this referral. If the clinical or image interpretation does not parallel your findings or if I can be of any further assistance please contact me.

Kathleen Sennello DVM,MS, Diplomate ACVIM (Small animal Internal Medicine)

info@sonopath.com