

**PATIENT**

Winston Prado

SPECIES

Feline

BREED

Domestic Shorthair

SEX

Intact Male

AGE

8 Months

WEIGHT

5.8 lbs

INTERPRETED BYKathleen Sennello DVM,
MS, Diplomate ACVIM
(Small Animal Internal
Medicine)**IMAGING
PERFORMED BY**

Gabriel Ferrer, DVM

HOSPITAL NAME

Pulse: Pet Ultrasound

REFERRING VET

Dr. Mario Roman

INVOICE

73537

DATE

3/10/26

PRESENTING CLINICAL SIGNS

Px presented as a referral for an abdominal ultrasound due to Hx of vomiting. Owner reports that Px had some episodes of diarrhea after the episodes of vomiting began. Px was hospitalized last week (March 1st) and is now discharged. Owner reports that Px is still vomiting. Owner reports that Px displays lethargic behavior until after they vomit, which is when Px becomes slightly more appetent

Abnormal PE/Chem/CBC/UA Results: Bloodwork attached below for your reference

ULTRASONOGRAPHIC EXAMINATION OF THE ABDOMEN**Urinary System**

The urinary bladder is moderately distended with anechoic urine. The Bladder wall, trigone, ureteral papillae and visible urethra (to a depth of 2cm) appear normal with no evidence of wall thickening, mucosal irregularities, masses or cystic calculi.

The left kidney has a normal shape and size (3.88 cm). Overall echogenicity is normal with adequate corticomedullary distinction and a typical 1:3 cortex:medulla ratio. There is a thin hyperechoic line separating the cortex and medulla, most consistent with medullary rim signs. There is no evidence of pyelectasia, nephroliths, infarcts or hydroureter. Renal vasculature is normal.

The right kidney has a normal shape and size (3.88 cm). Overall echogenicity is normal with adequate corticomedullary distinction and a typical 1:3 cortex:medulla ratio. There is a thin hyperechoic line separating the cortex and medulla, most consistent with medullary rim signs. There is no evidence of pyelectasia, nephroliths, infarcts or hydroureter. Renal vasculature is normal.

Adrenal Glands

The left adrenal gland is normal in size measuring 0.39 cm at the caudal pole. It is observed in its normal position cranial to the left renal artery. It is normal in appearance (uniformly hypoechoic) and shape with no evidence of a mass effect.

The right adrenal gland is normal in size measuring 0.35 cm at the caudal pole. It is observed in its normal position between the cranial aspect of the right kidney and the caudal vena cava. It is normal in appearance (uniformly hypoechoic) and shape with no evidence of a mass effect.

Spleen

The spleen is subjectively normal in size (0.90 cm), echotexture is homogenous, and the splenic capsule is smooth with no irregularities. The blood flow through the hilus and splenic parenchyma appears normal. No focal parenchymal abnormalities are visualized.

Liver

The liver is subjectively normal in size, and echogenicity with smooth peripheral margins. The parenchyma is homogenous echotexture. The visible portions of the vasculature and biliary tract appear normal. No focal nodules or cystic lesions are observed.

The gall bladder lumen is moderately distended. The wall of the gall bladder is not thickened and has a smooth mucosal surface. Luminal contents are mild and likely incidental at this time. The cystic and common bile ducts are normal/not visible.



PATIENT

Winston Prado

SPECIES

Feline

BREED

Domestic Shorthair

SEX

Intact Male

AGE

8 Months

WEIGHT

5.8 lbs

INTERPRETED BY

Kathleen Sennello DVM,
MS, Diplomate ACVIM
(Small Animal Internal
Medicine)

IMAGING PERFORMED BY

Gabriel Ferrer, DVM

HOSPITAL NAME

Pulse: Pet Ultrasound

REFERRING VET

Dr. Mario Roman

INVOICE

73537

DATE

3/10/26

Gastrointestinal

The stomach contains mild fluid. It measures at a normal thickness of <0.36cm with some variability due to the presence of rugal folds. The distinction of the gastric wall layers is adequate and there is no impression of reduced peristaltic activity. No masses or focal lesions were observed.

The visualized areas of duodenum, jejunum and ileum have a uniform diameter with minimal fluid distension. Wall thickness is normal to slightly increased. Bowel loops follow a typical curvilinear path with distinct wall layering, but some areas display a prominent muscularis layer which does not display the typical 1:3 muscularis:mucosa layer ratio. Duodenum wall measures 0.26 cm. Jejunum wall measures 0.24 cm. Visualized peristalsis appears appropriate. The muscularis layer of the small intestine appears diffusely mildly prominent.

Sections of colon are visualized with formed fecal material and gas shadowing distally. There is no observed focal or generalized colon wall thickening or loss of layering.

Pancreas

The area of the pancreas is visible/mildly mottled in the right limb. There is no evidence of nodules or cystic lesions. There is no evidence of regional mesenteric inflammation or fluid.

Free Abdomen

Evaluation of the peritoneal cavity did not reveal any evidence of effusion. There is a mild mesenteric lymphadenopathy with visible/mildly prominent mesenteric lymph nodes. Examples measure 0.23 cm and 0.27 cm. The right iliac lymph node measures 0.37 cm.

ULTRASONOGRAPHIC FINDINGS

- Corticomedullary rim sign visualized associated with both kidneys – Clinical significance uncertain, can be seen in normal patients and in cases of ethylene glycol toxicity, FIP, chronic interstitial nephritis, and leptospirosis.
- Visible/mildly mottled pancreas – The pancreatic changes are most consistent with age-related parenchymal remodeling, potentially secondary to a prior inflammatory episode, early fibrosis or chronic pancreatitis.
- Mildly fluid distended stomach – Correlate with feeding history. If the patient was adequately fasted, this could represent mild delayed gastric emptying/gastritis.
- Diffusely “ropey” small intestine with prominent muscularis – The small intestinal wall changes are most consistent with an inflammatory process (i.e., inflammatory bowel disease) with a low possibility of emerging lymphoma.
- Changes consistent with reactive lymphadenopathy.

INTERPRETATION OF THE FINDINGS & FURTHER RECOMMENDATIONS

The small intestine appears mildly diffusely ropey with a prominent muscularis layer, possibly consistent with inflammatory type change. This could be secondary to GI parasites, viral enteritis, food allergy/dietary sensitivities, etc. A neoplastic process seems much less likely.



PATIENT

Winston Prado

SPECIES

Feline

BREED

Domestic Shorthair

SEX

Intact Male

AGE

8 Months

WEIGHT

5.8 lbs

INTERPRETED BY

Kathleen Sennello DVM,
MS, Diplomate ACVIM
(Small Animal Internal
Medicine)

**IMAGING
PERFORMED BY**

Gabriel Ferrer, DVM

HOSPITAL NAME

Pulse: Pet Ultrasound

REFERRING VET

Dr. Mario Roman

INVOICE

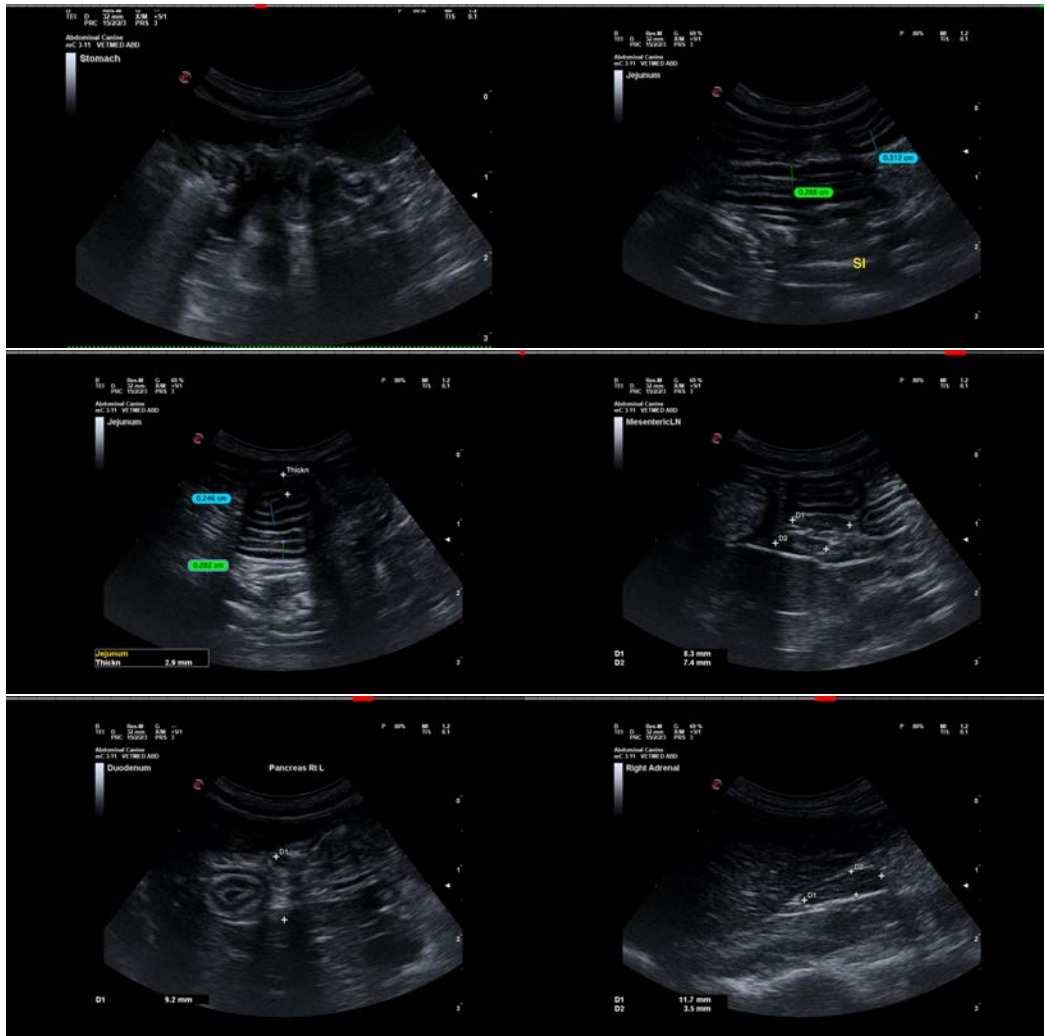
73537

DATE

3/10/26

- Consider a novel protein/hydrolyzed protein diet (exclusively at least 4-6 weeks).
- If not already done, recommend parasite screening and empirical deworming.
- Consider screening for infectious cause of diarrhea/viral enteritis.
- Consider a GI panel to Texas A&M for evaluation of B12 levels, folate, PLI/TLI etc.. to further evaluate for pancreatic/small intestinal disease.

If symptoms are persistent despite taking these measures, you could consider repeat imaging, looking for the development of a more pronounced focal lesion, as if symptoms are truly persistent, eventually biopsies of the GI tract may be warranted.





PATIENT

Winston Prado

SPECIES

Feline

BREED

Domestic Shorthair

SEX

Intact Male

AGE

8 Months

WEIGHT

5.8 lbs

INTERPRETED BY

Kathleen Sennello DVM,
MS, Diplomate ACVIM
(Small Animal Internal
Medicine)

IMAGING PERFORMED BY

Gabriel Ferrer, DVM

HOSPITAL NAME

Pulse: Pet Ultrasound

REFERRING VET

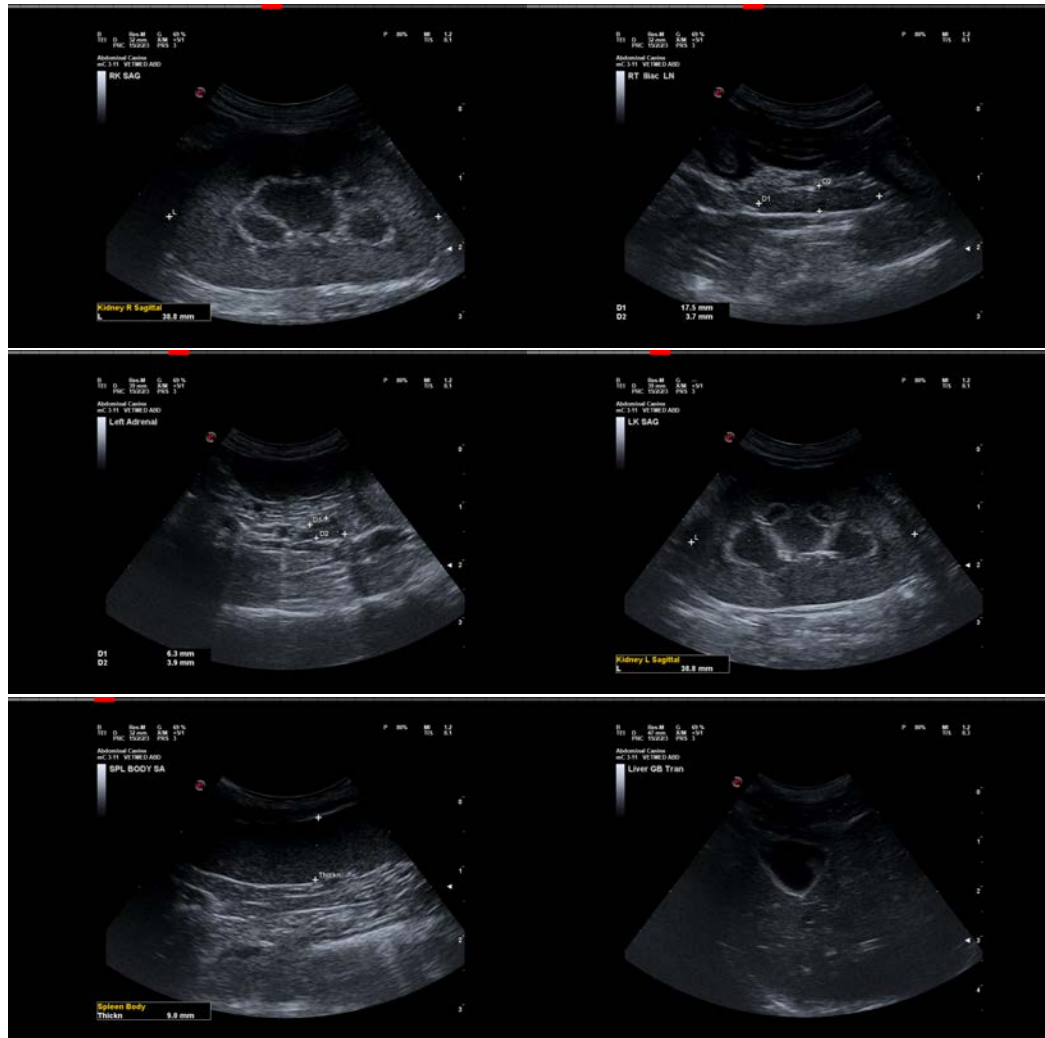
Dr. Mario Roman

INVOICE

73537

DATE

3/10/26



The information and recommendations provided are based on the images presented by the referring veterinarian/sonographer. No evaluation can be communicated regarding pathology that was not visible in the image/video clips provided.

Thank you for this referral. If the clinical or image interpretation does not parallel your findings or if I can be of any further assistance please contact me.

Kathleen Sennello DVM,MS, Diplomate ACVIM (Small animal Internal Medicine)

info@sonopath.com