



## PATIENT

Missy Carozza

## SPECIES

Canine

## BREED

Miniature Schnauzer

## SEX

Spayed Female

## AGE

8 Years

## WEIGHT

12.8

## INTERPRETED BY

Kathleen Sennello DVM,  
MS, Diplomate ACVIM  
(Small Animal Internal  
Medicine)

## IMAGING PERFORMED BY

Dr. Casper

## HOSPITAL NAME

Hometown Animal  
Hospital (Florida)

## REFERRING VET

Dr. AJ Basta

## INVOICE

73542

## DATE

3/10/26

## PRESENTING CLINICAL SIGNS

Presented for anesthetic dental preops on 1/23/26 - mild leukopenia and inc cystatin B, 1+ bilirubinuria, calcium crystals w/ normal UPC on UA. Abd rads showed splenomegaly. No clinical signs. Recheck UA today (3/10) urine changes resolved. Recheck senior panel pending

## ULTRASONOGRAPHIC EXAMINATION OF THE ABDOMEN

### Urinary System

The urinary bladder is moderately distended with mild suspended and dependent echogenic debris present. The Bladder wall, trigone, ureteral papillae and visible urethra (to a depth of 2cm) appear normal with no evidence of wall thickening, mucosal irregularities, masses or calculi. Echogenic debris of this type can be associated with small crystals, cellular debris and proteinaceous debris.

The left kidney has a normal shape and size (3.86 cm). Overall echogenicity is slightly hyperechoic with mildly reduced corticomedullary distinction and a typical 1:3 cortex:medulla ratio. There is no evidence of focal perinephric inflammation or effusion. There is no evidence of pyelectasia, nephroliths, infarcts or hydroureter. Renal vasculature is normal.

The right kidney has a normal shape and size (4.13 cm). Overall echogenicity is slightly hyperechoic with mildly reduced corticomedullary distinction and a typical 1:3 cortex:medulla ratio. There is no evidence of focal perinephric inflammation or effusion. There is no evidence of pyelectasia, nephroliths, infarcts or hydroureter. Renal vasculature is normal.

### Adrenal Glands

The left adrenal gland is normal in size measuring 0.47 cm at the cranial pole and 0.46 cm at the caudal pole. It is observed in its normal position cranial to the left renal artery. It is normal in appearance (uniformly hypoechoic) and shape with no evidence of a mass effect.

The right adrenal gland is normal in size measuring 0.44 cm at the caudal pole. It is observed in its normal position between the cranial aspect of the right kidney and the caudal vena cava. It is normal in appearance (uniformly hypoechoic) and shape with no evidence of a mass effect.

### Spleen

The spleen is subjectively normal in size (1.46 cm), echotexture is homogenous, and the splenic capsule is smooth with no irregularities. The blood flow through the hilus and splenic parenchyma appears normal. No focal parenchymal abnormalities are visualized.

### Liver

The liver is subjectively normal in size, and echogenicity with smooth peripheral margins. The parenchyma is mildly heterogenous in echotexture with subtle, indistinct focal mottling. The visible portions of the vasculature and biliary tract appear normal. No focal nodules or cystic lesions are observed.

The gall bladder lumen is moderately distended. The wall of the gall bladder is not thickened and has a smooth mucosal surface. Luminal contents are mild and likely incidental at this time. The cystic and common bile ducts are normal/not visible.



**PATIENT**

Missy Carozza

**SPECIES**

Canine

**BREED**

Miniature Schnauzer

**SEX**

Spayed Female

**AGE**

8 Years

**WEIGHT**

12.8

**INTERPRETED BY**

Kathleen Sennello DVM,  
MS, Diplomate ACVIM  
(Small Animal Internal  
Medicine)

**IMAGING  
PERFORMED BY**

Dr. Casper

**HOSPITAL NAME**

Hometown Animal  
Hospital (Florida)

**REFERRING VET**

Dr. AJ Basta

**INVOICE**

73542

**DATE**

3/10/26

**Gastrointestinal**

The stomach contains minimal luminal contents. It measures at a normal thickness of <0.7cm with some variability due to the presence of rugal folds. The distinction of the gastric wall layers is adequate and there is no impression of reduced peristaltic activity. No masses or focal lesions were observed.

The visualized areas of duodenum, jejunum and ileum have a relatively uniform diameter with minimal fluid distension. Wall thickness is normal. Bowel loops follow a curvilinear path with distinct wall layering maintaining the typical 1:3 muscularis:mucosa layer ratio. Jejunum wall measures 0.25 cm. Visualized peristalsis appears appropriate. There were no focal lesions consistent with obstruction or a mass effect observed.

Sections of colon are visualized with formed fecal material and gas shadowing distally. There is no observed focal or generalized colon wall thickening or loss of layering.

**Pancreas**

The area of the pancreas is normal and isoechoic to surrounding mesentery. There is no evidence of nodules or cystic lesions. There is no evidence of regional mesenteric inflammation or fluid.

**Free Abdomen**

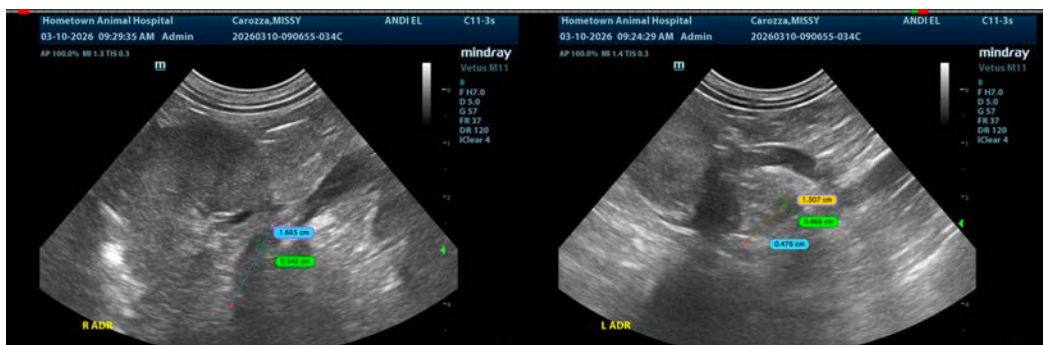
Evaluation of the peritoneal cavity did not reveal any evidence of effusion, or subjective lymphadenomegaly. The Medial iliac nodes appear normal and there was no evidence of a caudal aortic thrombus at the bifurcation. The omentum is of normal uniform echogenicity.

**ULTRASONOGRAPHIC FINDINGS**

- Mild suspended and dependent echogenic debris in the urinary bladder – The echogenic debris in the bladder lumen could be consistent with cells, crystals, and/or mucus.
- Age related changes visualized associated with both kidneys.
- Subjectively mildly heterogeneous liver – Findings could be normal for this individual or be consistent with a mild vacuolar hepatopathy.

**INTERPRETATION OF THE FINDINGS & FURTHER RECOMMENDATIONS**

No significant abnormalities are visualized associated with the spleen on today's exam. The remaining changes were mild and possibly normal for this individual. Recommend continued monitoring and reassess if concerns arise.





**PATIENT**

Missy Carozza

**SPECIES**

Canine

**BREED**

Miniature Schnauzer

**SEX**

Spayed Female

**AGE**

8 Years

**WEIGHT**

12.8

**INTERPRETED BY**

Kathleen Sennello DVM,  
MS, Diplomate ACVIM  
(Small Animal Internal  
Medicine)

**IMAGING  
PERFORMED BY**

Dr. Casper

**HOSPITAL NAME**

Hometown Animal  
Hospital (Florida)

**REFERRING VET**

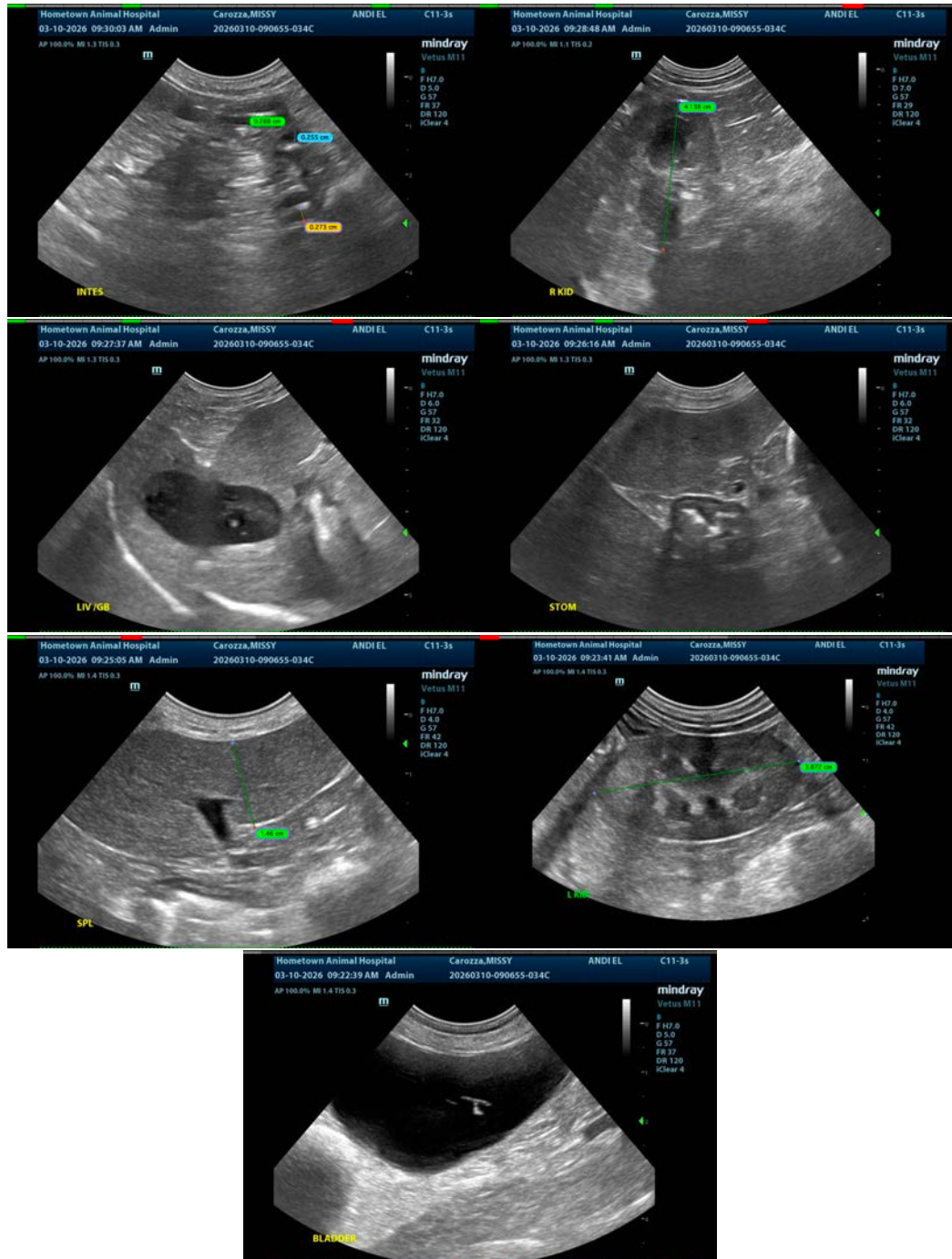
Dr. AJ Basta

**INVOICE**

73542

**DATE**

3/10/26





## PATIENT

Missy Carozza

## SPECIES

Canine

## BREED

Miniature Schnauzer

## SEX

Spayed Female

## AGE

8 Years

## WEIGHT

12.8

## INTERPRETED BY

Kathleen Sennello DVM,  
MS, Diplomate ACVIM  
(Small Animal Internal  
Medicine)

## IMAGING PERFORMED BY

Dr. Casper

## HOSPITAL NAME

Hometown Animal  
Hospital (Florida)

## REFERRING VET

Dr. AJ Basta

## INVOICE

73542

## DATE

3/10/26

The information and recommendations provided are based on the images presented by the referring veterinarian/sonographer. No evaluation can be communicated regarding pathology that was not visible in the image/video clips provided.

Thank you for this referral. If the clinical or image interpretation does not parallel your findings or if I can be of any further assistance please contact me.

Kathleen Sennello DVM,MS, Diplomate ACVIM (Small animal Internal Medicine)

info@sonopath.com