



PATIENT

Lilo Arvanites

SPECIES

Canine

BREED

Golden Doodle

SEX

Spayed Female

AGE

9 Years

WEIGHT

65 lbs

INTERPRETED BY

Kathleen Sennello DVM,
MS, Diplomate ACVIM
(Small Animal Internal
Medicine)

IMAGING PERFORMED BY

Dr. Elaina Petrone

HOSPITAL NAME

Long Branch Animal
Hospital

REFERRING VET

Dr. Elaina Petrone

INVOICE

73536

DATE

3/10/26

PRESENTING CLINICAL SIGNS

Pre-op AUS for mass removal. Elevated ALT: 270, ALP: 266, GGT: 35

ULTRASONOGRAPHIC EXAMINATION OF THE ABDOMEN

Urinary System

The urinary bladder is moderately distended with anechoic urine. The Bladder wall, trigone, ureteral papillae and visible urethra (to a depth of 2cm) appear normal with no evidence of wall thickening, mucosal irregularities, masses or cystic calculi.

The left kidney has a normal shape and size (6.77 cm). Overall echogenicity is normal with adequate corticomedullary distinction and a typical 1:3 cortex:medulla ratio. There is no evidence of focal perinephric inflammation or effusion. There is no evidence of pyelectasia, nephroliths, infarcts or hydroureter. Renal vasculature is normal.

The right kidney has a normal shape and size (7.44 cm). Overall echogenicity is normal with adequate corticomedullary distinction and a typical 1:3 cortex:medulla ratio. There is no evidence of focal perinephric inflammation or effusion. There is no evidence of pyelectasia, nephroliths, infarcts or hydroureter. Renal vasculature is normal.

Adrenal Glands

The left adrenal gland is normal in size measuring 0.77 cm at the cranial pole and 0.66 cm at the caudal pole. It is observed in its normal position cranial to the left renal artery. It is normal in appearance (uniformly hypoechoic) and shape with no evidence of a mass effect.

The right adrenal gland is "plump" measuring 1.19 cm at the caudal pole. It is observed in its normal position between the cranial aspect of the right kidney and the caudal vena cava. It is normal in appearance (uniformly hypoechoic) and shape with no evidence of a mass effect.

Spleen

The spleen is subjectively normal in size (1.48 cm), echotexture is homogenous, and the splenic capsule is smooth with no irregularities. The blood flow through the hilus and splenic parenchyma appears normal. No focal parenchymal abnormalities are visualized.

Liver

The liver is large in size, and hyperechoic with smooth peripheral margins. The parenchyma is heterogenous in echotexture with subtle, indistinct focal mottling. The visible portions of the vasculature and biliary tract appear normal. No focal nodules or cystic lesions are observed.

The gall bladder lumen is moderately distended. The wall of the gall bladder is not thickened and has a smooth mucosal surface. There is a moderate amount of non-organized echogenic debris. The cystic and common bile ducts are normal/not visible.

Gastrointestinal

The stomach contains minimal luminal contents. It measures at a normal thickness of <0.7cm with some variability due to the presence of rugal folds. The distinction of the gastric wall layers is adequate and there is no impression of reduced peristaltic activity. No masses or focal lesions were observed.



PATIENT

Lilo Arvanites

SPECIES

Canine

BREED

Golden Doodle

SEX

Spayed Female

AGE

9 Years

WEIGHT

65 lbs

INTERPRETED BY

Kathleen Sennello DVM,
MS, Diplomate ACVIM
(Small Animal Internal
Medicine)

IMAGING PERFORMED BY

Dr. Elaina Petrone

HOSPITAL NAME

Long Branch Animal
Hospital

REFERRING VET

Dr. Elaina Petrone

INVOICE

73536

DATE

3/10/26

The visualized areas of duodenum, jejunum and ileum have a relatively uniform diameter with minimal fluid distension. Wall thickness is normal. Bowel loops follow a curvilinear path with distinct wall layering maintaining the typical 1:3 muscularis:mucosa layer ratio. Duodenum wall measures 0.47 cm. Jejunum wall measures 0.47 cm. Visualized peristalsis appears appropriate. There were no focal lesions consistent with obstruction or a mass effect observed.

Sections of colon are visualized with formed fecal material and gas shadowing distally. There is no observed focal or generalized colon wall thickening or loss of layering.

Pancreas

The pancreas is normal and isoechoic to surrounding mesentery. There is no evidence of nodules or cystic lesions. There is no evidence of regional mesenteric inflammation or fluid.

Free Abdomen

Evaluation of the peritoneal cavity did not reveal any evidence of effusion, or subjective lymphadenomegaly. The Medial iliac nodes appear normal and there was no evidence of a caudal aortic thrombus at the bifurcation. The omentum is of normal uniform echogenicity.

ULTRASONOGRAPHIC FINDINGS

- Large, heterogeneous, hyperechoic liver – The diffuse hepatic changes are non-specific and could be consistent with vacuolar hepatopathy, nodular hyperplasia, inflammatory/immune-mediated disease, fibrosis, extramedullary hematopoiesis, toxic hepatopathy (e.g., copper), infiltrative neoplasia (less likely) or other hepatopathy.
- Moderate gallbladder debris – The significance of the aggregated gallbladder debris is unclear. This could represent an early mucocele, cholestasis, or may be secondary to fasting but seems unlikely to be causing a current issue. Recommend continued monitoring.
- Subjectively large right adrenal gland – Possible differentials could include anatomic variation, focal hyperplasia, less likely a mass effect (the cranial pole is difficult to clearly visualize).

INTERPRETATION OF THE FINDINGS & FURTHER RECOMMENDATIONS

No focal lesions are visualized associated with the liver, but it does subjectively appear large and somewhat hyperechoic and heterogeneous. These are non-specific findings. Further evaluation for a primary hepatopathy could involve pre- and post-prandial bile acids to evaluate liver function. Additionally, a fine needle aspirate could be considered. If liver function is abnormal and/or liver enzyme elevations are persistently elevated, eventually a biopsy of the liver may be warranted with samples for histopathology, culture and copper levels.

The gallbladder has a moderate amount of debris but no evidence of significant wall thickening at this time. You could also consider a course of Denamarin and antibiotics and reassessing lab work to see if there is significant improvement. Continued monitoring of the gallbladder is recommended long-term.

The right adrenal gland is subjectively large. The significance of this is uncertain as no focal lesion is observed. If signs of Cushing's are present, you could consider adrenal function testing. Additionally you could consider repeat evaluation of the right adrenal in 2-3 months, looking for significant changes.



PATIENT

Lilo Arvanites

SPECIES

Canine

BREED

Golden Doodle

SEX

Spayed Female

AGE

9 Years

WEIGHT

65 lbs

INTERPRETED BY

Kathleen Sennello DVM,
MS, Diplomate ACVIM
(Small Animal Internal
Medicine)

**IMAGING
PERFORMED BY**

Dr. Elaina Petrone

HOSPITAL NAME

Long Branch Animal
Hospital

REFERRING VET

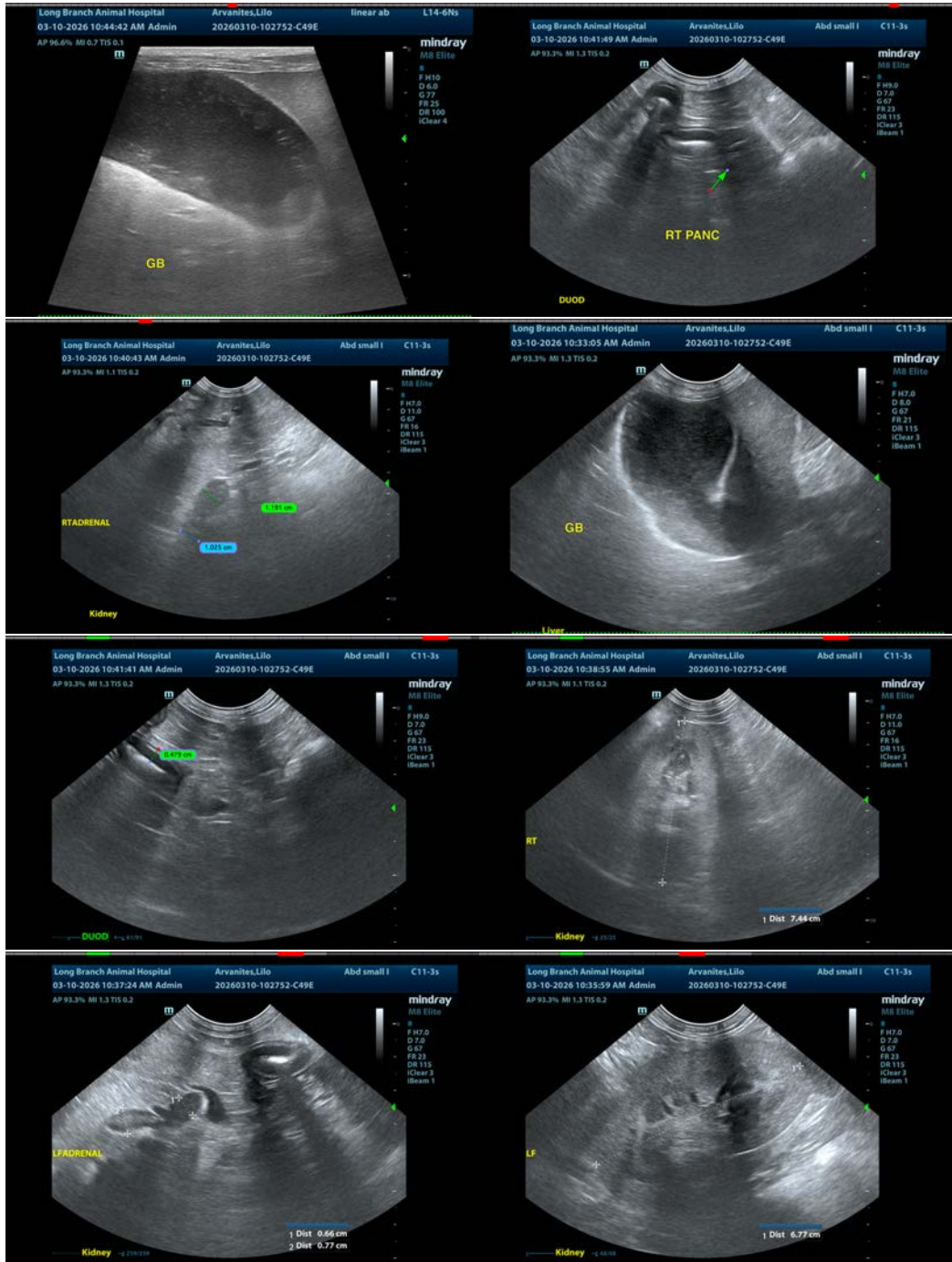
Dr. Elaina Petrone

INVOICE

73536

DATE

3/10/26





PATIENT

Lilo Arvanites

SPECIES

Canine

BREED

Golden Doodle

SEX

Spayed Female

AGE

9 Years

WEIGHT

65 lbs

INTERPRETED BY

Kathleen Sennello DVM,
MS, Diplomate ACVIM
(Small Animal Internal
Medicine)

IMAGING PERFORMED BY

Dr. Elaina Petrone

HOSPITAL NAME

Long Branch Animal
Hospital

REFERRING VET

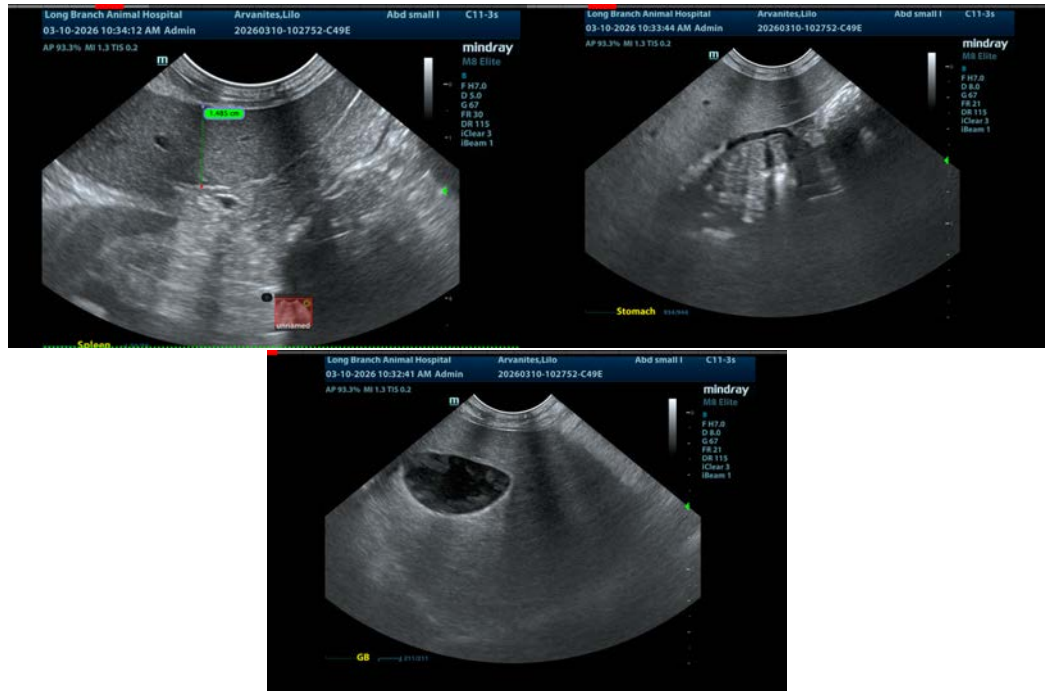
Dr. Elaina Petrone

INVOICE

73536

DATE

3/10/26



The information and recommendations provided are based on the images presented by the referring veterinarian/sonographer. No evaluation can be communicated regarding pathology that was not visible in the image/video clips provided.

Thank you for this referral. If the clinical or image interpretation does not parallel your findings or if I can be of any further assistance please contact me.

Kathleen Sennello DVM,MS, Diplomate ACVIM (Small animal Internal Medicine)

info@sonopath.com