



PATIENT

Roxie Labonte

SPECIES

Canine

BREED

Brittany Spaniel

SEX

Spayed Female

AGE

13 Years

WEIGHT

27 Pounds

INTERPRETED BY

Kathleen Sennello DVM,
MS, Diplomate ACVIM
(Small Animal Internal
Medicine)

IMAGING PERFORMED BY

Karen Ebersole, DVM,
DABVP (Canine/Feline
Practice)

HOSPITAL NAME

Scanvet

REFERRING VET

Dr. Chadbourne

INVOICE

45841

DATE

3/10/23

PRESENTING CLINICAL SIGNS

Elevated LE. No clinical signs. History of hypercalcemia since 11/2021, worked up previously. Asymptomatic per owner. Declined cervical US at the time.

Abnormal PE/Chem/CBC/UA Results: BW (2/25, liver panel): BUN 38, ALT 438, GGT 20. BW (11/2022): BUN 36, ALT 148, Ca 14.7, Phos 3.0 Hypercalcemia Panel (11/2021): PTH 15.7, iCa 1.79.

ULTRASONOGRAPHIC EXAMINATION OF THE ABDOMEN

Urinary System

The urinary bladder is moderately distended with anechoic urine. The Bladder wall, trigone, ureteral papillae and visible urethra (to a depth of 2cm) appear normal with no evidence of wall thickening, mucosal irregularities, masses or cystic calculi.

The left kidney has a normal shape and size (4.6 cm). Overall echogenicity is normal with adequate corticomedullary distinction and a typical 1:3 cortex:medulla ratio. There is no evidence of focal perinephric inflammation or effusion. There is no evidence of pyelectasia, nephroliths, infarcts or hydroureter. Renal vasculature is normal.

The right kidney has a normal shape and size (4.33 cm). Overall echogenicity is normal with adequate corticomedullary distinction and a typical 1:3 cortex:medulla ratio. There is no evidence of focal perinephric inflammation or effusion. There is no evidence of pyelectasia, nephroliths, infarcts or hydroureter. Renal vasculature is normal.

Adrenal Glands

The left adrenal gland is normal in size measuring 0.58 cm at the caudal pole. It is observed in its normal position cranial to the left renal artery. It is normal in appearance (uniformly hypoechoic) and shape with no evidence of a mass effect.

The right adrenal gland is normal in size measuring 0.60 cm at the caudal pole. It is observed in its normal position between the cranial aspect of the right kidney and the caudal vena cava. It is normal in appearance (uniformly hypoechoic) and shape with no evidence of a mass effect.

Spleen

The spleen is subjectively normal in size, echotexture is homogenous, and the splenic capsule is smooth with no irregularities. The blood flow through the hilus and splenic parenchyma appears normal. No focal parenchymal abnormalities are visualized.

Liver

The liver is subjectively normal in size but irregular. The parenchyma is heterogenous in echotexture with subtle, indistinct focal mottling. The visible portions of the vasculature and biliary tract appear normal. There are numerous variably sized subtle nodules visualized within the parenchyma.

The gallbladder lumen is moderately distended. The wall of the gall bladder is not thickened and has a smooth mucosal surface. Luminal contents are mild and primarily anechoic. The cystic and common bile ducts are normal/not visible.



PATIENT

Roxie Labonte

SPECIES

Canine

BREED

Brittany Spaniel

SEX

Spayed Female

AGE

13 Years

WEIGHT

27 Pounds

INTERPRETED BY

Kathleen Sennello DVM,
MS, Diplomate ACVIM
(Small Animal Internal
Medicine)

**IMAGING
PERFORMED BY**

Karen Ebersole, DVM,
DABVP (Canine/Feline
Practice)

HOSPITAL NAME

Scanvet

REFERRING VET

Dr. Chadbourne

INVOICE

45841

DATE

3/10/23

Gastrointestinal

The stomach contains minimal luminal contents. It measures at a normal thickness of <0.7cm with some variability due to the presence of rugal folds. The distinction of the gastric wall layers is adequate and there is no impression of reduced peristaltic activity. No masses or focal lesions were observed.

The visualized areas of duodenum, jejunum and ileum have a relatively uniform diameter with minimal fluid distension. Wall thickness is normal. Bowel loops follow a curvilinear path with distinct wall layering maintaining the typical 1:3 muscularis:mucosa layer ratio. The duodenum measured as normal (between 0.3-0.5cm in wall thickness) and the jejunum measured as normal (between 0.2-0.47cm.) Visualized peristalsis appears appropriate. There were no focal lesions consistent with obstruction or a mass effect observed.

The ileocecal junction was visualized and exhibited normal intact wall layering and is subjectively of normal thickness. Sections of colon are visualized with formed fecal material and gas shadowing distally. There is no observed focal or generalized colon wall thickening or loss of layering.

Pancreas

The pancreas is normal and isoechoic to surrounding mesentery. There is no evidence of nodules or cystic lesions. There is no evidence of regional mesenteric inflammation or fluid.

Free Abdomen

Evaluation of the peritoneal cavity did not reveal any evidence of effusion, or subjective lymphadenomegaly. The Medial iliac nodes appear normal and there was no evidence of a caudal aortic thrombus at the bifurcation. The omentum is of normal uniform echogenicity.

ULTRASONOGRAPHIC FINDINGS

- Heterogeneous with ill-defined hypoechoic nodules – The diffuse hepatic changes are non-specific and could be consistent with vacuolar hepatopathy, nodular hyperplasia, inflammatory/immune-mediated disease, fibrosis, extramedullary hematopoiesis, toxic hepatopathy (e.g., copper), infiltrative neoplasia (less likely) or other hepatopathy. The nodules observed trend toward a more benign process but underlying neoplasia cannot be ruled out.

INTERPRETATION OF THE FINDINGS & FURTHER RECOMMENDATIONS

The abnormalities visualized associated with the liver are diffuse with no large focal mass lesions, etc. Additionally, the gallbladder appears relatively normal. Findings are consistent with a primary hepatopathy. Consider the following steps:

- Consider close evaluation of history for possible toxic changes examine medications, diet, dietary indiscretion etc...
- Consider PCR on urine/serum for leptospirosis (if not on antibiotics)/serology if recent antibiotic history
- If not already done, consider pre and post prandial bile acids to evaluate liver function
- Consider Fine needle aspirate if round cell neoplasia is on your differential list (25 g needle, normal coags)
- If no response to supportive care (Denamarin, fluids, antibiotics, +/- ursodiol etc.) Consider liver biopsy with samples obtained for histopathology, culture, and copper levels.



PATIENT

Roxie Labonte

A fine needle aspirate can be helpful in ruling out round cell neoplasia in these patients, but in order to determine a true diagnosis of other hepatopathies, typically a liver biopsy with histopathology and copper levels will be required.

SPECIES

Canine

Consider reevaluation of ionized calcium and PTH levels. I suspect the previous measurements are consistent with primary hyperparathyroidism (normals not included).

BREED

Brittany Spaniel

SEX

Spayed Female

AGE

13 Years

WEIGHT

27 Pounds

INTERPRETED BY

Kathleen Sennello DVM, MS, Diplomate ACVIM (Small Animal Internal Medicine)

IMAGING PERFORMED BY

Karen Ebersole, DVM, DABVP (Canine/Feline Practice)

HOSPITAL NAME

Scanvet

REFERRING VET

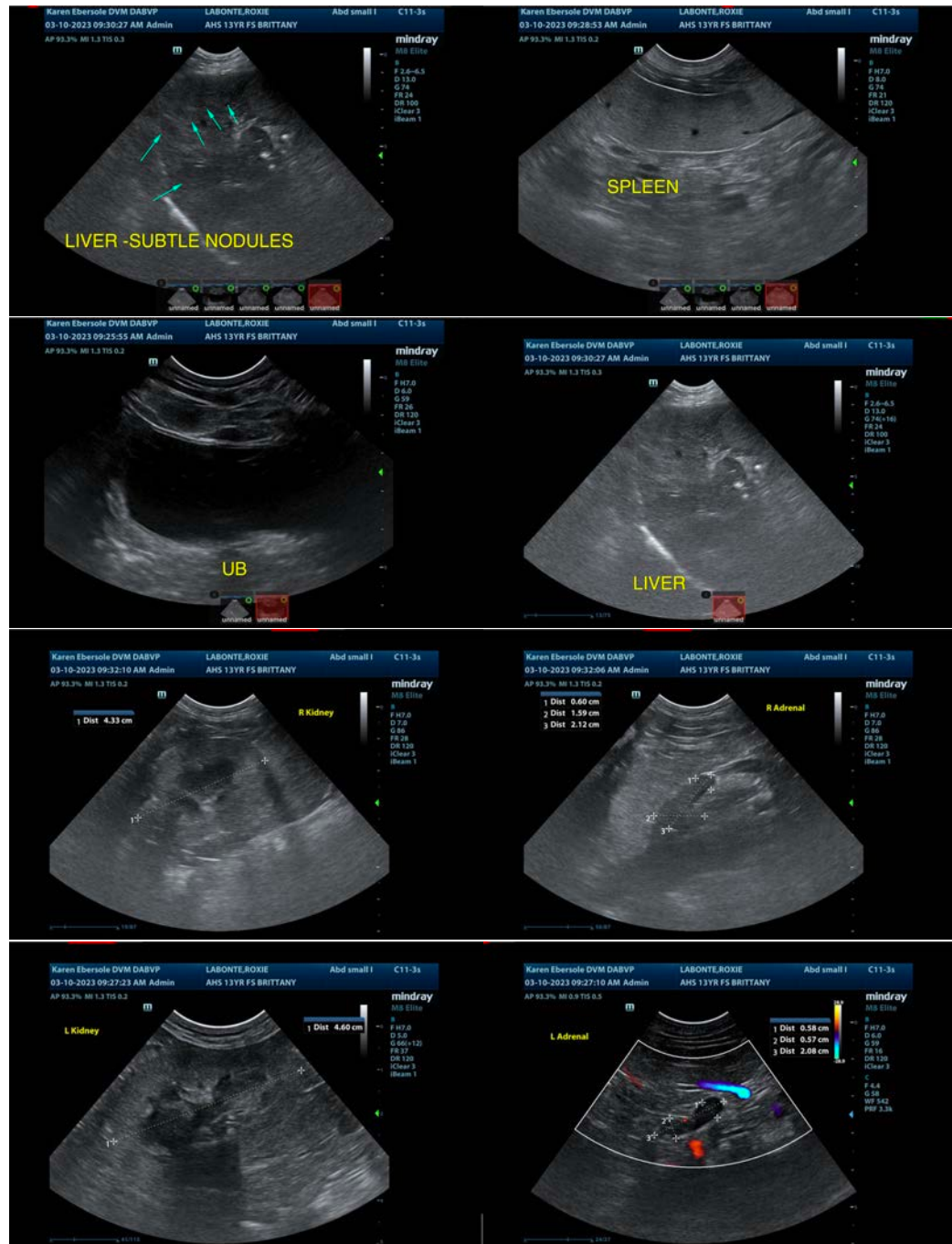
Dr. Chadbourne

INVOICE

45841

DATE

3/10/23





PATIENT

Roxie Labonte

SPECIES

Canine

BREED

Brittany Spaniel

SEX

Spayed Female

AGE

13 Years

WEIGHT

27 Pounds

INTERPRETED BY

Kathleen Sennello DVM,
MS, Diplomate ACVIM
(Small Animal Internal
Medicine)

**IMAGING
PERFORMED BY**

Karen Ebersole, DVM,
DABVP (Canine/Feline
Practice)

HOSPITAL NAME

Scanvet

REFERRING VET

Dr. Chadbourne

INVOICE

45841

DATE

3/10/23

The information and recommendations provided are based on the images presented by the referring veterinarian/sonographer. No evaluation can be communicated regarding pathology that was not visible in the image/video clips provided.

Thank you for this referral. If the clinical or image interpretation does not parallel your findings or if I can be of any further assistance please contact me.

Kathleen Sennello DVM,MS, Diplomate ACVIM (Small animal Internal Medicine)

kathleen.sennello@sonopath.com