SonoPath
Clinical Sonography & Telecytology
EDUCATIONAL TELECONSULTATION SERVICES™
1-800-838-4268 info@sonopath.com SonoPath.com

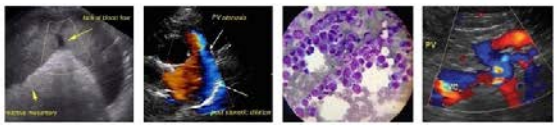

THE FOCAL ZONE
IMAGING PERFORMED BY
289-808-2608 info@thefocalzone.com

**PATIENT**
Suzy Nesbitt

**SPECIES**
Canine

**BREED**
Bichon Frise

**SEX**
Spayed Female

**AGE**
13 Years

**WEIGHT**
11.5 kg

**INTERPRETED BY**
Kathleen Sennello DVM, MS, Diplomate ACVIM (Small Animal Internal Medicine)

**IMAGING PERFORMED BY**
Crystal Hill

**HOSPITAL NAME**
Lynden Animal Clinic

**REFERRING VET**
Dr. Babcock

**INVOICE**
45003

**DATE**
2/9/23

## PRESENTING CLINICAL SIGNS

Weight loss, suffering from gastric reflux, increased harsh cough that is worsening. Started on Furosemide, Fortekor and Gabapentin and Sucralfate. No real improvement.

Abnormal PE/Chem/CBC/UA Results: X-rays suggestive of enlarged heart and concern for splenic mass.

## ULTRASONOGRAPHIC EXAMINATION OF THE ABDOMEN

### *Urinary System*

The urinary bladder is moderately distended with anechoic urine. The Bladder wall, trigone, ureteral papillae and visible urethra (to a depth of 2cm) appear normal with no evidence of wall thickening, mucosal irregularities, masses or cystic calculi.

The left kidney has a normal shape and size (4.15 cm) with a very large cortical cyst arising from the caudal pole measuring 5.82 cm x 5.81 cm. Overall echogenicity is slightly hyperechoic with poor corticomedullary distinction and a typical 1:3 cortex:medulla ratio. There is no evidence of focal perinephric inflammation or effusion. There is no evidence of pyelectasia, nephroliths, infarcts or hydroureter. Renal vasculature is normal.

The right kidney has a normal shape and size (4.74 cm). Overall echogenicity is slightly hyperechoic with poor corticomedullary distinction and a typical 1:3 cortex:medulla ratio. There is no evidence of focal perinephric inflammation or effusion. There is no evidence of pyelectasia, nephroliths, infarcts or hydroureter. Renal vasculature is normal.

### *Adrenal Glands*

The left adrenal gland is normal in size measuring 0.55 cm at the caudal pole. It is observed in its normal position cranial to the left renal artery. It is normal in appearance (uniformly hypoechoic) and shape with no evidence of a mass effect.

The right adrenal gland is normal in size measuring 0.61 cm at the caudal pole. It is observed in its normal position between the cranial aspect of the right kidney and the caudal vena cava. It is normal in appearance (uniformly hypoechoic) and shape with no evidence of a mass effect.

### *Spleen*

The spleen is subjectively normal in size, echotexture is homogenous, and the splenic capsule is smooth with no irregularities. The blood flow through the hilus and splenic parenchyma appears normal. There are multiple distinct small hyperechoic nodules visualized in the parenchyma, most consistent with benign myelolipomas, measuring 0.41 cm and 0.48 cm.

### *Liver*

The liver is subjectively normal in size, and echogenicity with smooth peripheral margins. The parenchyma is homogenous echotexture. The visible portions of the vasculature and biliary tract appear normal. No focal nodules or cystic lesions are observed.

The gallbladder lumen is moderately distended. The wall of the gall bladder is not thickened and has a smooth mucosal surface. Luminal contents are mild and primarily anechoic. The cystic and common bile ducts are normal/not visible.

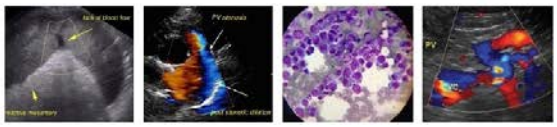



**PATIENT**
Suzy Nesbitt

**SPECIES**
Canine

**BREED**
Bichon Frise

**SEX**
Spayed Female

**AGE**
13 Years

**WEIGHT**
11.5 kg

**INTERPRETED BY**
Kathleen Sennello DVM, MS, Diplomate ACVIM (Small Animal Internal Medicine)

**IMAGING PERFORMED BY**
Crystal Hill

**HOSPITAL NAME**
Lynden Animal Clinic

**REFERRING VET**
Dr. Babcock

**INVOICE**
45003

**DATE**
2/9/23

### *Gastrointestinal*

The stomach contains minimal luminal contents. It measures at a normal thickness of <0.7cm with some variability due to the presence of rugal folds. The distinction of the gastric wall layers is adequate and there is no impression of reduced peristaltic activity. No masses or focal lesions were observed.

The visualized areas of duodenum, jejunum and ileum have a relatively uniform diameter with minimal fluid distension. Wall thickness is normal. Bowel loops follow a curvilinear path with distinct wall layering maintaining the typical 1:3 muscularis:mucosa layer ratio. Duodenum wall measures 0.41 cm. Jejunum wall measures 0.36 cm. Visualized peristalsis appears appropriate. There were no focal lesions consistent with obstruction or a mass effect observed.

The ileocecal junction was visualized and exhibited normal intact wall layering and is subjectively of normal thickness. Sections of colon are visualized with formed fecal material and gas shadowing distally. There is no observed focal or generalized colon wall thickening or loss of layering.

### *Pancreas*

The pancreas is normal and isoechoic to surrounding mesentery. There is no evidence of nodules or cystic lesions. There is no evidence of regional mesenteric inflammation or fluid.

### *Free Abdomen*

Evaluation of the peritoneal cavity did not reveal any evidence of effusion, or subjective lymphadenomegaly. The Medial iliac nodes appear normal and there was no evidence of a caudal aortic thrombus at the bifurcation. The omentum is of normal uniform echogenicity.

### ULTRASONOGRAPHIC FINDINGS

- Decreased corticomedullary distinction in both kidneys with a large cortical cyst in the left kidney
- Hyperechoic foci/nodules within the splenic parenchyma – Findings are most consistent with benign myelolipomas.

### INTERPRETATION OF THE FINDINGS & FURTHER RECOMMENDATIONS

Both kidneys have decreased corticomedullary distinction. These findings are consistent with chronic age-related renal disease. Consider a blood pressure, urinalysis and culture. Additionally, there is a very large cystic structure arising from the left kidney. This is likely a benign renal cyst and could be incidental. If this is uncomfortable for the patient, you could consider drainage, but often these cysts communicate with the renal pelvis and refill rapidly. Additionally, there is risk for urine leakage into the abdomen.

The hyperechoic foci in the spleen are most consistent with benign myelolipomas. Recommend continued monitoring.

SonoPath
Clinical Sonography & Telecytology
EDUCATIONAL TELECONSULTATION SERVICES™
1-800-838-4268 info@sonopath.com SonoPath.com

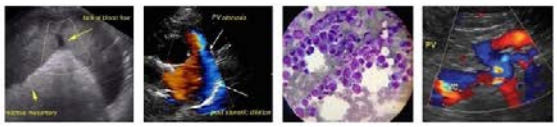

THE FOCAL ZONE
IMAGING PERFORMED BY
289-808-2608 info@thefocalzone.com

**PATIENT**

Suzy Nesbitt

**SPECIES**

Canine

**BREED**

Bichon Frise

**SEX**

Spayed Female

**AGE**

13 Years

**WEIGHT**

11.5 kg

**INTERPRETED BY**

Kathleen Sennello DVM, MS, Diplomate ACVIM (Small Animal Internal Medicine)

**IMAGING PERFORMED BY**

Crystal Hill

**HOSPITAL NAME**

Lynden Animal Clinic

**REFERRING VET**

Dr. Babcock

**INVOICE**

45003

**DATE**

2/9/23

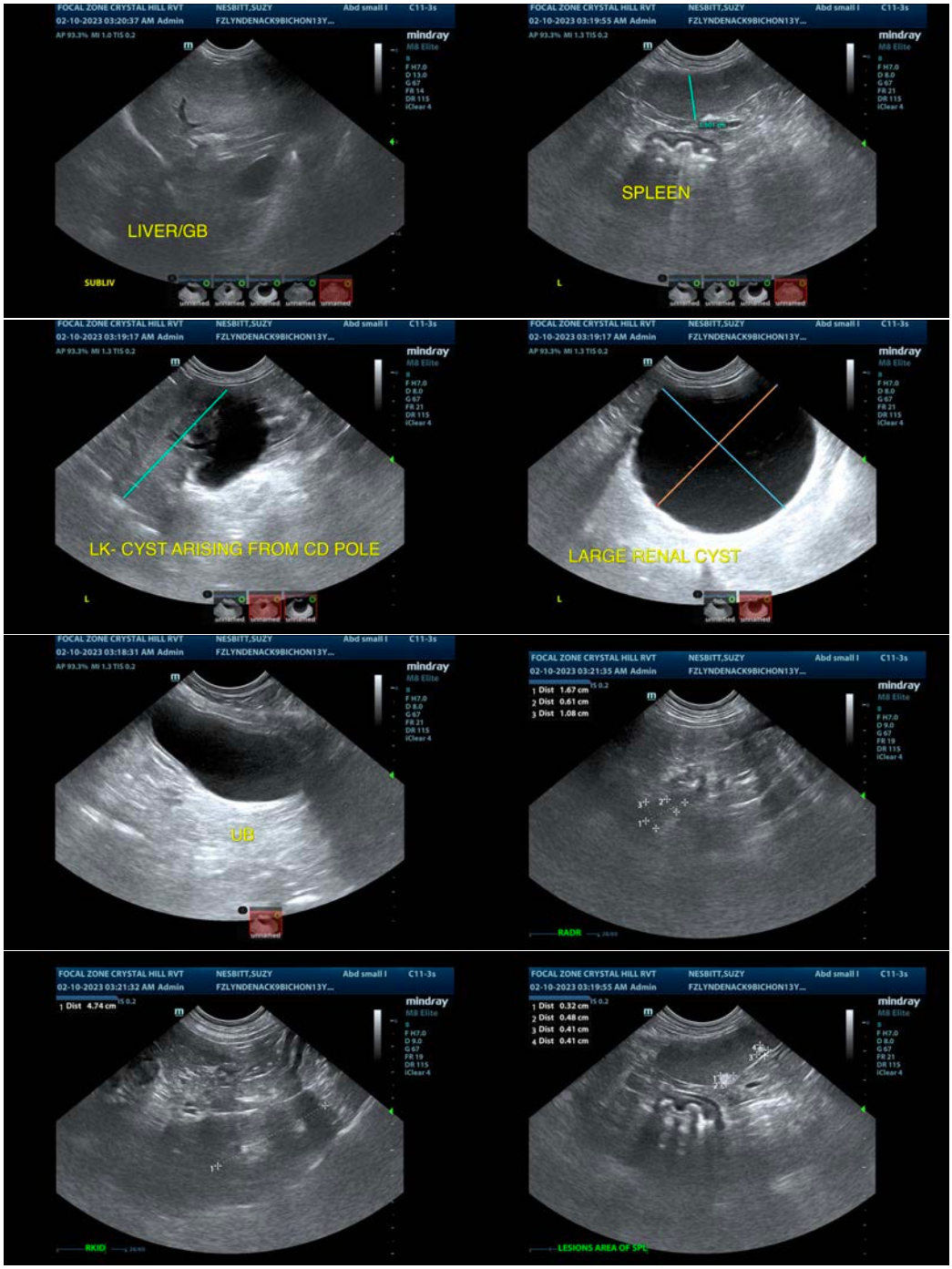

SonoPath
Clinical Sonography & Telecytology
EDUCATIONAL TELECONSULTATION SERVICES™
1-800-838-4268 info@sonopath.com SonoPath.com

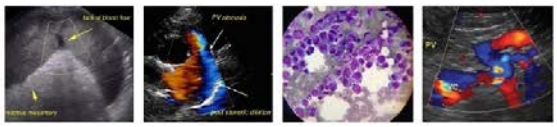

THE FOCAL ZONE
IMAGING PERFORMED BY
289-808-2608 info@thefocalzone.com

**PATIENT**

Suzy Nesbitt

**SPECIES**

Canine

**BREED**

Bichon Frise

**SEX**

Spayed Female

**AGE**

13 Years

**WEIGHT**

11.5 kg

**INTERPRETED BY**

Kathleen Sennello DVM, MS, Diplomate ACVIM (Small Animal Internal Medicine)

**IMAGING PERFORMED BY**

Crystal Hill

**HOSPITAL NAME**

Lynden Animal Clinic

**REFERRING VET**

Dr. Babcock

**INVOICE**

45003

**DATE**

2/9/23

**The information and recommendations provided are based on the images presented by the referring veterinarian/sonographer. No evaluation can be communicated regarding pathology that was not visible in the image/video clips provided.**

Thank you for this referral. If the clinical or image interpretation does not parallel your findings or if I can be of any further assistance please contact me.

Kathleen Sennello DVM,MS, Diplomate ACVIM (Small animal Internal Medicine)

kathleen.sennello@sonopath.com