



DATE PRESENTING CLINICAL SIGNS

2/9/23 Pet presented for annual exam. Historically elevated ALP. Previous Aus: If a cause for the ALP elevation is not identified: I recommend recheck general blood work every 6 months, ultrasound once per year. ALP was repeated and has doubled from 182 last year to 384 this year. Pet clinically normal.

PATIENT

Ruxin Kalmanovich

Current Medications: None.
Lab Results: ALP- 384 (5-131) prev 182
Date of Previous IntraPet Ultrasound: 4/5/22. See attached.
Sedation: Not required to complete full diagnostic ultrasound.
Stat Report: Not requested.
Imaging Performed By: Andi Parkinson, BS, RDMS.

SPECIES

Canine

BREED

Mixed

SEX

Neutered Male

AGE

7/19/09

WEIGHT

17.7 Pounds

INTERPRETED BY

Kathleen Sennello DVM,
MS, Diplomate ACVIM
(Small Animal Internal
Medicine)

HOSPITAL NAME

Fullerton AH

REFERRING VET

Dr. Unger

INVOICE

45010

ULTRASONOGRAPHIC EXAMINATION OF THE ABDOMEN

Urinary System

The urinary bladder is moderately distended with anechoic urine. The Bladder wall, trigone, ureteral papillae and visible urethra (to a depth of 2cm) appear normal with no evidence of wall thickening, mucosal irregularities, masses or cystic calculi.

The prostate is normal in size (0.95 cm) and shape for this neutered male dog. The parenchyma is homogenous and the external margins are smooth. The prostatic urethra appears normal with no evidence of irregularity, invasion, mass effect or calculi.

The left kidney has a normal shape and size (4.18 cm). Overall echogenicity is normal with adequate corticomedullary distinction and a typical 1:3 cortex:medulla ratio. There is no evidence of focal perinephric inflammation or effusion. There is no evidence of pyelectasia, nephroliths, infarcts or hydroureter. Renal vasculature is normal.

The right kidney has a normal shape and size (4.26 cm). Overall echogenicity is normal with adequate corticomedullary distinction and a typical 1:3 cortex:medulla ratio. There is no evidence of focal perinephric inflammation or effusion. There is no evidence of pyelectasia, nephroliths, infarcts or hydroureter. Renal vasculature is normal.

Adrenal Glands

The left adrenal gland is normal in size measuring 0.64 cm at the caudal pole. It is observed in its normal position cranial to the left renal artery. It is normal in appearance (uniformly hypoechoic) and shape with no evidence of a mass effect.

The right adrenal gland is normal in size measuring 0.40 cm at the caudal pole. It is observed in its normal position between the cranial aspect of the right kidney and the caudal vena cava. It is normal in appearance (uniformly hypoechoic) and shape with no evidence of a mass effect.

Spleen

The spleen is subjectively normal in size and the echotexture is homogenous. The splenic capsule is smooth with no visible irregularities. Rare discrete focal hyperechoic, perivascular parenchymal abnormalities are present. The appearance of these lesions is most consistent with benign splenic myelolipomas. The blood flow through the hilus and splenic parenchyma appears normal.

Liver

The liver is borderline large with smooth peripheral margins. The parenchyma is hyperechoic and homogenous in echotexture. The visible portions of the vasculature and biliary tract appear normal. No focal nodules or cystic lesions are observed.

The gallbladder lumen is moderately distended. The wall of the gall bladder is not thickened and has a smooth mucosal surface. Luminal contents are mild and primarily anechoic. The cystic and common bile ducts are normal/not visible.

Gastrointestinal

The stomach contains minimal luminal contents. It measures at a normal thickness of <0.7cm with some variability due to the presence of rugal folds. The distinction of the gastric wall layers is adequate and there is no impression of reduced peristaltic activity. No masses or focal lesions were observed.

The visualized areas of duodenum, jejunum and ileum have a relatively uniform diameter with minimal fluid distension. Wall thickness is normal. Bowel loops follow a curvilinear path with distinct wall layering maintaining the typical 1:3 muscularis:mucosa layer ratio. Duodenum wall measures 0.51 cm. Jejunum wall measures 0.36 cm. Visualized peristalsis appears appropriate. There were no focal lesions consistent with obstruction or a mass effect observed.

The ileocecal junction was visualized and exhibited normal intact wall layering and is subjectively of normal thickness. Sections of colon are visualized with formed fecal material and gas shadowing distally. There is no observed focal or generalized colon wall thickening or loss of layering.

Pancreas

The pancreas is normal and isoechoic to surrounding mesentery. There is no evidence of nodules or cystic lesions. There is no evidence of regional mesenteric inflammation or fluid.

Free Abdomen

Evaluation of the peritoneal cavity did not reveal any evidence of effusion, or subjective lymphadenomegaly. The Medial iliac nodes appear normal and there was no evidence of a caudal aortic thrombus at the bifurcation. The omentum is of normal uniform echogenicity.

Other

There is a slightly hypoechoic, rounded mass effect visualized in the right flank region, which appears likely intraabdominal and does not show significant vascularity on power doppler, possibly consistent with a lipoma. The lesion measures 2.52 cm x 1.85 cm.

PRIMARY FINDINGS

- Hyperechoic liver – The diffuse hepatic changes are non-specific and can be seen with vacuolar hepatopathy, reactive change, nodular hyperplasia or, less likely, inflammatory/immune-mediated disease, infiltrative neoplasia, or other hepatopathy.
- Hypoechoic avascular mass lesion visualized in the right flank region – Findings are most consistent with a lipoma, but recommend a fine needle aspirate.

SECONDARY FINDINGS

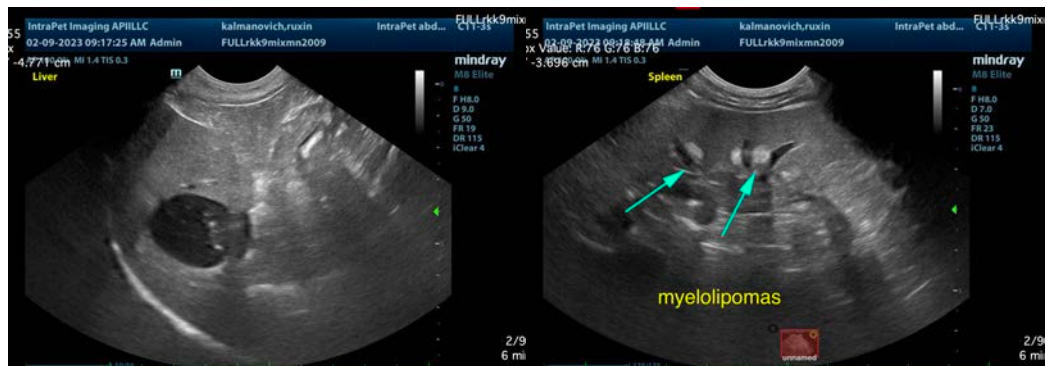
- Hyperechoic foci near the hilus of the spleen – Findings are most consistent with benign myelolipomas.

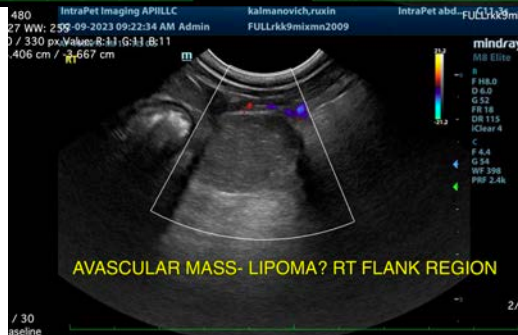
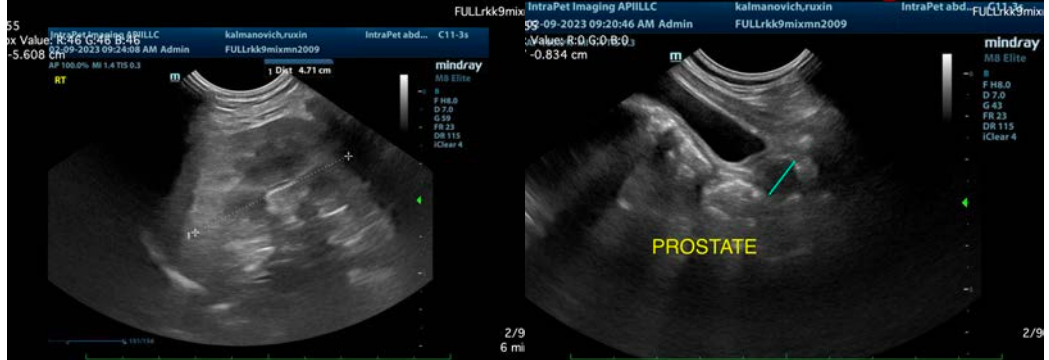
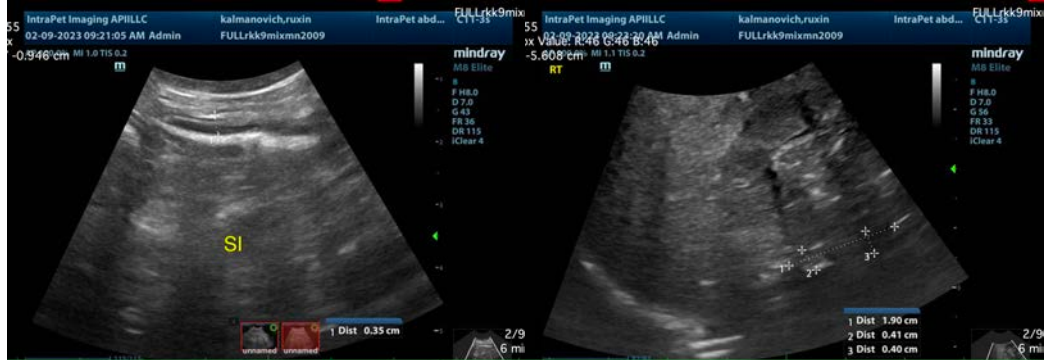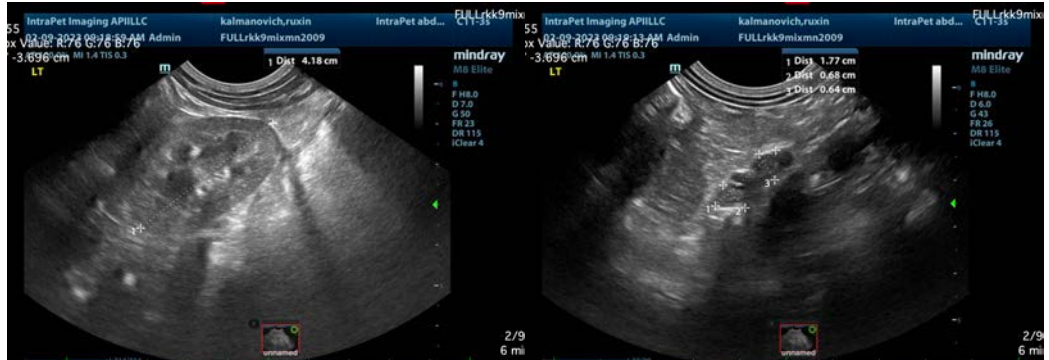INTERPRETATION OF THE FINDINGS & FURTHER RECOMMENDATIONS

The liver appears diffusely hyperechoic. No focal lesions are visualized, and the biliary tract appears normal. A cause for the recent increased ALP is not apparent. Findings are most consistent with a primary hepatopathy. These are my recommendations for further evaluation and monitoring of a primary ALP elevation. (These are the same recommendations given previously- reconsider Cushing's evaluation if clinically relevant or a liver function test if not already done.)

- Induction phenomena are the most common cause for an elevation in ALP. These are systemic illnesses that 'turn on' the liver enzyme. Causes of this include Cushing's disease, dental disease, arthritis, and numerous others. In many cases the exact cause is unclear but as long as ultrasound and bile acids tests are normal most patients do not have progressive changes in their liver. While liver biopsy is not routinely performed, vacuolar hepatopathy, is noted on most biopsies. This is often non-progressive but in rare cases can be more severe and lead to liver failure.
- If signs of Cushing's disease are present recommend endocrine function testing to evaluate for Cushing's disease.
- Consider fine needle aspirate to rule out round cell neoplasia -if this is a concern.
- If a cause for the ALP elevation is not identified: I recommend recheck general blood work every 6 months, ultrasound once per year, and bile acids test every 1-2 years based on other results. If the ALP continues to climb a biopsy could be considered.
- Consider long term use of denamarin, and monitoring for the signs of Cushing's developing.
- A primary vacuolar hepatopathy can be breed related and is seen in Scottish Terriers, Schnauzers, Cocker spaniels etc..

There is a slightly hypoechoic mass lesion visualized in the flank region, which appears to be in the abdomen. This lesion appears fairly avascular and could be consistent with a lipoma, although it is slightly more hypoechoic than a typical lipoma. Recommend a fine needle aspirate and continued monitoring of this lesion.





The information and recommendations provided are based on the images presented by the referring veterinarian/sonographer. No evaluation can be communicated regarding pathology that was not visible in the image/video clips provided.

Thank you for this referral. If the clinical or image interpretation does not parallel your findings or if I can be of any further assistance please contact me.

Kathleen Sennello DVM,MS, Diplomate ACVIM (Small animal Internal Medicine)
kathleen.sennello@sonopath.com