

PATIENT PRESENTING CLINICAL SIGNS

Bailey Lee

Sedation 0.1ml Dex/Torb IV- Concern for abdominal mass and specifically splenic mass but cannot rule out congested spleen or displaced. Also possible mass from other organs in that area or possible pancreatitis. Suspect vomiting brought on by dietary indiscretion but may also be related to a possible splenic mass.

SPECIES

Canine

BREED

Golden Retriever

Abnormal PE/Chem/CBC/UA Results: Urinalysis: Decreased specific gravity and increased pH. A: Hyposthenuric. DDX: Open. Renal values and hepatic values are normal. Possible metabolic versus neoplastic disease. Chemistry screen: Slight increased albumin and slight decrease phosphorus. Also slight decreased globulin. CPL snap test: Normal

SEX

Neutered Male

ULTRASONOGRAPHIC EXAMINATION OF THE ABDOMEN

Urinary System

AGE

10 Years

The urinary bladder is moderately distended with anechoic urine. The Bladder wall, trigone, ureteral papillae and visible urethra (to a depth of 2cm) appear normal with no evidence of wall thickening, mucosal irregularities, masses or cystic calculi.

WEIGHT

73.4 Pounds

The prostate is normal in size (1.2 cm) and shape for this neutered male dog. The parenchyma is homogenous and the external margins are smooth. The prostatic urethra appears normal with no evidence of irregularity, invasion, mass effect or calculi.

INTERPRETED BY

Kathleen Sennello DVM,
MS, Diplomate ACVIM
(Small Animal Internal
Medicine)

The left kidney has a normal shape and size (7.9 cm). Overall echogenicity is normal with adequate corticomedullary distinction and a typical 1:3 cortex:medulla ratio. There is no evidence of focal perinephric inflammation or effusion. There is no evidence of pyelectasia, nephroliths, infarcts or hydroureter. Renal vasculature is normal.

IMAGING PERFORMED BY

Loetitia Saint-Jacques,
LVT

The right kidney has a normal shape and size (7.31 cm). Overall echogenicity is normal with adequate corticomedullary distinction and a typical 1:3 cortex:medulla ratio. There is no evidence of focal perinephric inflammation or effusion. There is no evidence of pyelectasia, nephroliths, infarcts or hydroureter. Renal vasculature is normal.

Adrenal Glands

HOSPITAL NAME

SouthReno VH

The left adrenal gland is normal in size measuring 0.87 cm at the caudal pole. It is observed in its normal position cranial to the left renal artery. It is normal in appearance (uniformly hypoechoic) and shape with no evidence of a mass effect.

REFERRING VET

Dr. Schmitt

The right adrenal gland is normal in size measuring 0.79 cm at the caudal pole. It is observed in its normal position between the cranial aspect of the right kidney and the caudal vena cava. It is normal in appearance (uniformly hypoechoic) and shape with no evidence of a mass effect.

INVOICE

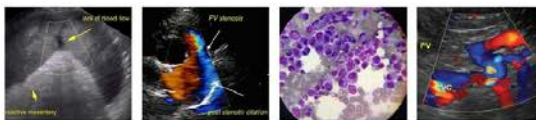
45017

Spleen

DATE

2/9/23

The spleen is subjectively normal in size, echotexture is homogenous, and the splenic capsule is smooth with no irregularities. The blood flow through the hilus and splenic parenchyma appears normal. No focal parenchymal abnormalities are visualized.



PATIENT *Liver*

SPECIES
Canine

BREED
Golden Retriever

SEX
Neutered Male

AGE
10 Years

WEIGHT
73.4 Pounds

The liver is subjectively normal in size, and echogenicity with smooth peripheral margins. The parenchyma is heterogenous in echotexture with subtle, indistinct focal mottling. The visible portions of the vasculature and biliary tract appear normal. In the right side of the liver, there are some hypoechoic lesions including two hypoechoic nodules measuring 1.06, 0.78, and 1.34 cm. Additionally, there is a larger mass effect/nodule measuring 3.56 cm. Additionally there are two hyperechoic nodules measuring 2.5 cm and 1.11 cm in diameter.

The gallbladder lumen is moderately distended. The wall of the gall bladder is not thickened and has a smooth mucosal surface. Luminal contents are mild and primarily anechoic. The cystic and common bile ducts are normal/not visible.

Gastrointestinal

The stomach contains minimal luminal contents. It measures at a normal thickness of <0.7cm with some variability due to the presence of rugal folds. The distinction of the gastric wall layers is adequate and there is no impression of reduced peristaltic activity. No masses or focal lesions were observed.

The visualized areas of duodenum, jejunum and ileum have a relatively uniform diameter with minimal fluid distension. Wall thickness is normal. Bowel loops follow a curvilinear path with distinct wall layering maintaining the typical 1:3 muscularis:mucosa layer ratio. The duodenum measured as normal (between 0.3-0.5cm in wall thickness) and the jejunum measured as normal (between 0.2-0.47cm.) Visualized peristalsis appears appropriate. There were no focal lesions consistent with obstruction or a mass effect observed.

The ileocecal junction was visualized and exhibited normal intact wall layering and is subjectively of normal thickness. Sections of colon are visualized with formed fecal material and gas shadowing distally. There is no observed focal or generalized colon wall thickening or loss of layering.

Pancreas

The pancreas is normal and isoechoic to surrounding mesentery. There is no evidence of nodules or cystic lesions. There is no evidence of regional mesenteric inflammation or fluid.

Free Abdomen

Evaluation of the peritoneal cavity did not reveal any evidence of effusion, or subjective lymphadenomegaly. The Medial iliac nodes appear normal and there was no evidence of a caudal aortic thrombus at the bifurcation. The omentum is of normal uniform echogenicity.

ULTRASONOGRAPHIC FINDINGS

- Heterogeneous liver with hypoechoic nodules and a hypoechoic mass effect – The diffuse hepatic changes are non-specific and could be consistent with vacuolar hepatopathy, nodular hyperplasia, inflammatory/immune-mediated disease, fibrosis, extramedullary hematopoiesis, toxic hepatopathy (e.g., copper), infiltrative neoplasia (less likely) or other hepatopathy. The visualized nodules could represent a benign or neoplastic process. Recommend sampling.

INTERPRETATION OF THE FINDINGS & FURTHER RECOMMENDATIONS

Today's scan is relatively normal aside from some hypo- and hyperechoic nodules in the liver. The hyperechoic nodules have characteristics most consistent with benign lesions, but some of the

INTERPRETED BY

Kathleen Sennello DVM,
MS, Diplomate ACVIM
(Small Animal Internal
Medicine)

IMAGING PERFORMED BY

Loetitia Saint-Jacques,
LVT

HOSPITAL NAME

SouthReno VH

REFERRING VET

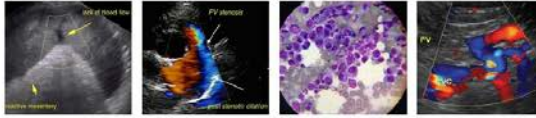
Dr. Schmitt

INVOICE

45017

DATE

2/9/23



PATIENT

Bailey Lee

SPECIES

Canine

BREED

Golden Retriever

SEX

Neutered Male

AGE

10 Years

WEIGHT

73.4 Pounds

INTERPRETED BY

Kathleen Sennello DVM,
MS, Diplomate ACVIM
(Small Animal Internal
Medicine)

IMAGING PERFORMED BY

Loetitia Saint-Jacques,
LVT

HOSPITAL NAME

SouthReno VH

REFERRING VET

Dr. Schmitt

INVOICE

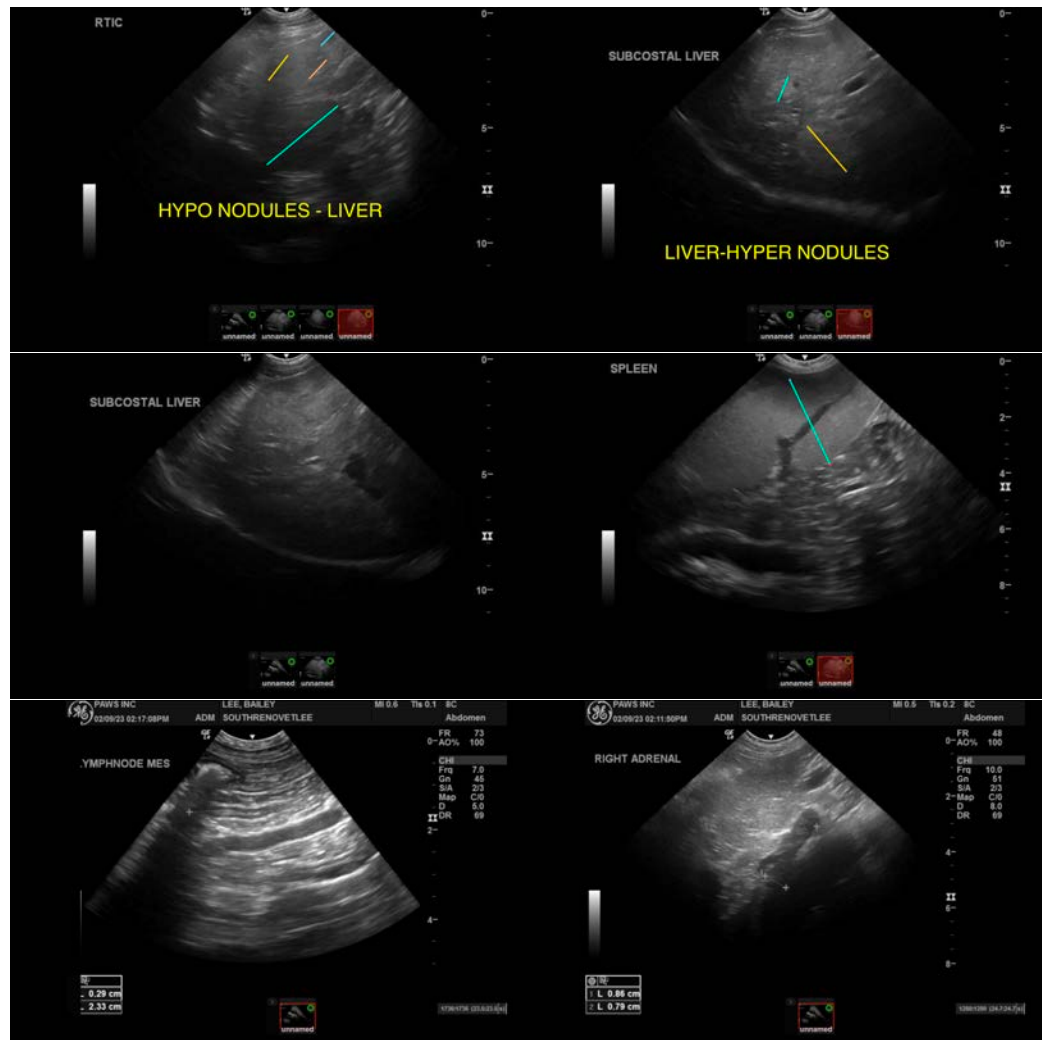
45017

DATE

2/9/23

hypoechoic nodules do deform the hepatic margins somewhat and are more concerning. Consider a fine needle aspirate of any of the lesions that are within reach. Additionally, you could consider a contrast CT scan to evaluate the larger lesion and evaluate for possible surgical intervention if cytology is not possible or definitive.

Recommend three view thoracic radiographs to evaluate for possible concurrent thoracic disease/involvement.





PATIENT

Bailey Lee

SPECIES

Canine

BREED

Golden Retriever

SEX

Neutered Male

AGE

10 Years

WEIGHT

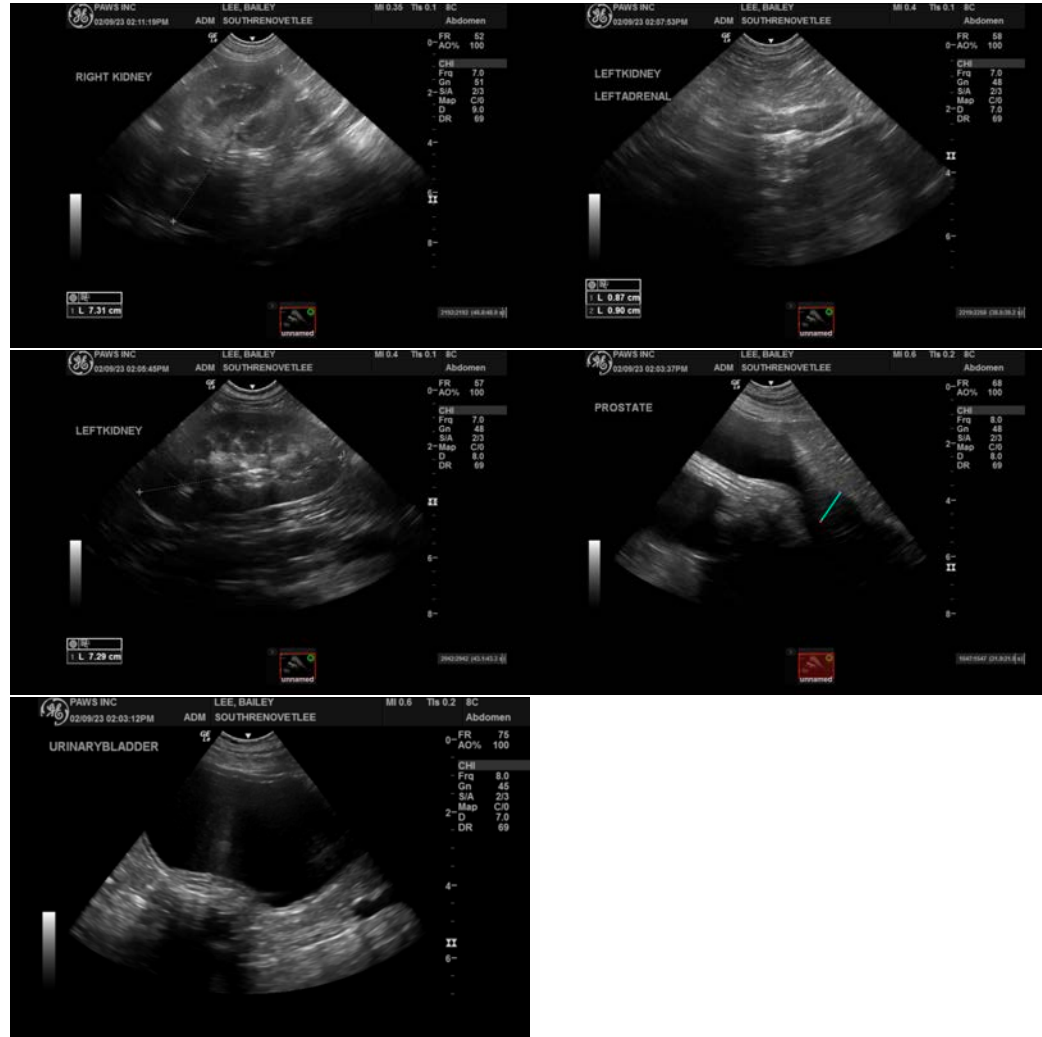
73.4 Pounds

INTERPRETED BY

Kathleen Sennello DVM,
MS, Diplomate ACVIM
(Small Animal Internal
Medicine)

**IMAGING
PERFORMED BY**

Loetitia Saint-Jacques,
LVT



HOSPITAL NAME

SouthReno VH

REFERRING VET

Dr. Schmitt

INVOICE

45017

DATE

2/9/23

The information and recommendations provided are based on the images presented by the referring veterinarian/sonographer. No evaluation can be communicated regarding pathology that was not visible in the image/video clips provided.

Thank you for this referral. If the clinical or image interpretation does not parallel your findings or if I can be of any further assistance please contact me.

Kathleen Sennello DVM,MS, Diplomate ACVIM (Small animal Internal Medicine)

kathleen.sennello@sonopath.com