

PATIENT

Teeka Rutter

SPECIES

Canine

BREED

Chihuahua

SEX

Spayed Female

AGE

11 years

WEIGHT

4.8 lbs

INTERPRETED BY

Kathleen Sennello
DVM, MS, Diplomate
ACVIM (Small Animal
Internal Medicine)

IMAGING PERFORMED BY

Jack Reese

HOSPITAL NAME

Willow Run VC

REFERRING VET

Dr. Leppien

INVOICE

95937

DATE

2/9/22

PRESENTING CLINICAL SIGNS

Evaluated 2/4/22 for pre-dental exam, heavy tartar noted. Pre-operative bloodwork revealed changes concerning for liver disease. Recommended abdominal U/S as next step in workup.
Abnormal PE/Chem/CBC/UA Results: SDMA - 16 (0-14) CRE - 0.6 BUN - 21 TP - 7.6 (5.5-7.5) Glob - 4.6 (2.4-4.0) ALT - 2,102 (18-121) AST - 207 (16-55) ALP - 2,001 (5-160) GGT - 21 (0-13) Chol - 430 (337-1,469) CK - 278 (10-200) T4 - 2.0 (1.0-4.0) 4dx - neg x 4

ULTRASONOGRAPHIC EXAMINATION OF THE ABDOMEN

Urinary System

The urinary bladder is moderately distended with anechoic urine. The Bladder wall, trigone, ureteral papillae and visible urethra (to a depth of 2cm) appear normal with no evidence of wall thickening, mucosal irregularities, masses or cystic calculi.

The left kidney has a normal shape and size (2.93 cm). Overall echogenicity is normal with adequate corticomedullary distinction and a typical 1:3 cortex:medulla ratio. There is no evidence of perinephric inflammation or effusion. There is no evidence of pyelectasia, nephroliths, infarcts or hydroureter. Renal vasculature is normal.

The right kidney has a normal shape and size (3.07 cm). Overall echogenicity is normal with adequate corticomedullary distinction and a typical 1:3 cortex:medulla ratio. There is no evidence of perinephric inflammation or effusion. There is no evidence of pyelectasia, nephroliths, infarcts or hydroureter. Renal vasculature is normal.

Adrenal Glands

The left adrenal gland is normal in size measuring 0.37 cm at the caudal pole It is observed in its normal position cranial to the left renal artery. It is normal in appearance (uniformly hypoechoic) and shape with no evidence of a mass effect.

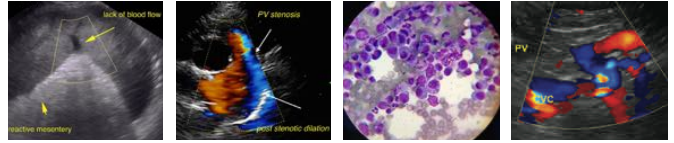
The right adrenal gland is normal in size measuring 0.37 cm at the caudal pole It is observed in its normal position between the cranial aspect of the right kidney and the caudal vena cava. It is normal in appearance (uniformly hypoechoic) and shape with no evidence of a mass effect.

Spleen

The spleen is subjectively normal in size, echotexture is homogenous, and the splenic capsule is smooth with no irregularities. The blood flow through the hilus and splenic parenchyma appears normal. No focal parenchymal abnormalities are visualized.

Liver

The liver is subjectively normal in size, and echogenicity with smooth peripheral margins. The parenchyma is heterogenous in echotexture with subtle, indistinct focal mottling. The visible portions of the vasculature and biliary tract appear normal. No focal nodules or cystic lesions are observed. The gallbladder lumen is moderately distended. The wall of the gallbladder is not thickened and has a



PATIENT

smooth mucosal surface. Luminal contents are primarily anechoic. The cystic and common bile ducts are normal/not visible.

Teeka Rutter

SPECIES

Gastrointestinal

Canine

The stomach contains minimal luminal contents. It measures at a normal thickness of <0.7cm with some variability due to the presence of rugal folds. The distinction of the gastric wall layers is adequate and there is no impression of reduced peristaltic activity. No masses or focal lesions were observed.

BREED

Chihuahua

The visualized areas of duodenum, jejunum and ileum have a relatively uniform diameter with minimal fluid distension. Wall thickness is normal. Bowel loops follow a curvilinear path with distinct wall layering maintaining the typical 1:3 muscularis:mucosa layer ratio. The duodenum measured as normal (between 0.3-0.5cm in wall thickness) and the jejunum measured as normal (between 0.2-0.47cm.)

SEX

Spayed Female

Visualized peristalsis appears appropriate. There were no focal lesions consistent with obstruction or a mass effect observed.

AGE

11 years

The ileocecal junction was visualized and exhibited normal intact wall layering and is subjectively of normal thickness. Sections of colon are visualized with formed fecal material and gas shadowing distally. There is no observed focal or generalized colon wall thickening or loss of layering.

WEIGHT

4.8 lbs

Pancreas

The pancreas is normal and isoechoic to surrounding mesentery. There is no evidence of nodules or cystic lesions. There is no evidence of regional mesenteric inflammation or fluid.

INTERPRETED BY

Kathleen Sennello
DVM, MS, Diplomate
ACVIM (Small Animal
Internal Medicine)

Free Abdomen

Evaluation of the peritoneal cavity did not reveal any evidence of effusion, or subjective lymphadenomegaly. The Medial iliac nodes appear normal and there was no evidence of a caudal aortic thrombus at the bifurcation. The omentum is of normal uniform echogenicity.

IMAGING PERFORMED BY

Jack Reese

ULTRASONOGRAPHIC FINDINGS

PRIMARY FINDINGS:

- Mildly heterogenous liver. The diffuse hepatic changes are non-specific and could be consistent with vacuolar hepatopathy, nodular hyperplasia, inflammatory/immune-mediated disease, fibrosis, extramedullary hematopoiesis, toxic hepatopathy (e.g., copper), infiltrative neoplasia (less likely) or other hepatopathy.

HOSPITAL NAME

Willow Run VC

REFERRING VET

Dr. Leppien

INTERPRETATION OF THE FINDINGS & FURTHER RECOMMENDATIONS

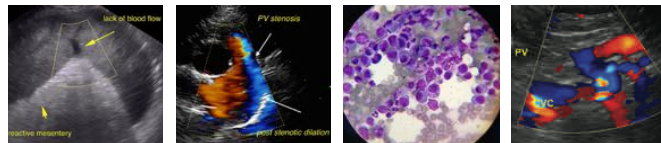
INVOICE

95937

The ultrasonographic changes in the liver were relatively mild. Unfortunately, the sonographic changes do not always reflect the severity or cause of the hepatopathy. The scan today supports a primary hepatopathy as no severe biliary changes were observed.

DATE

2/9/22



PATIENT

Teeka Rutter

SPECIES

Canine

BREED

Chihuahua

SEX

Spayed Female

AGE

11 years

WEIGHT

4.8 lbs

INTERPRETED BY

Kathleen Sennello
DVM, MS, Diplomate
ACVIM (Small Animal
Internal Medicine)

IMAGING PERFORMED BY

Jack Reese

HOSPITAL NAME

Willow Run VC

REFERRING VET

Dr. Leppien

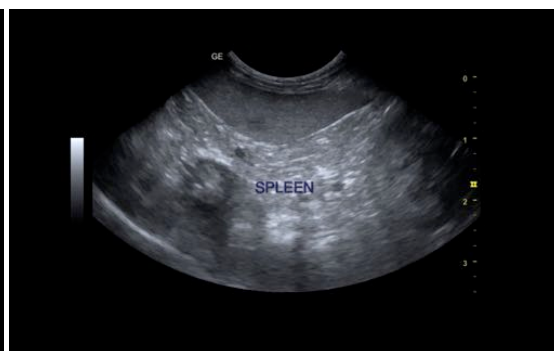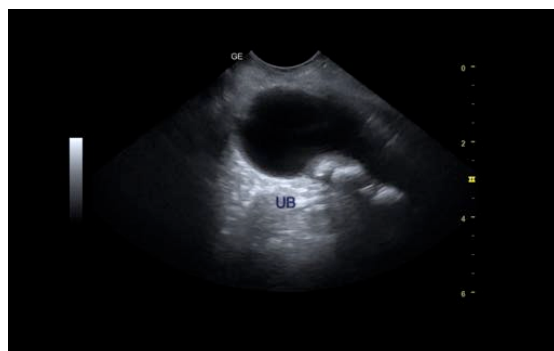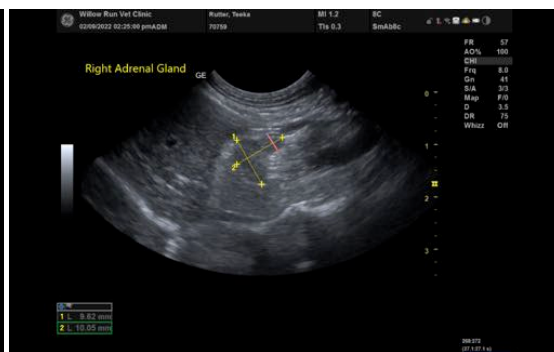
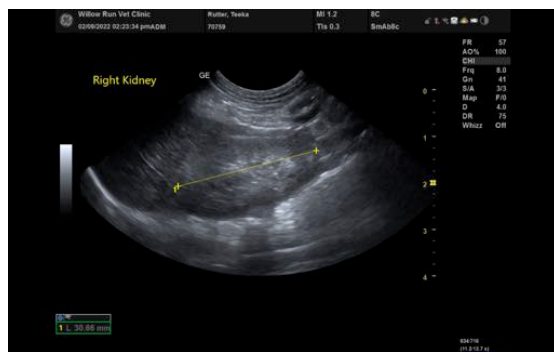
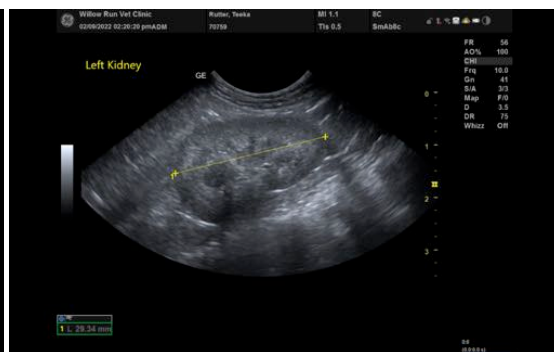
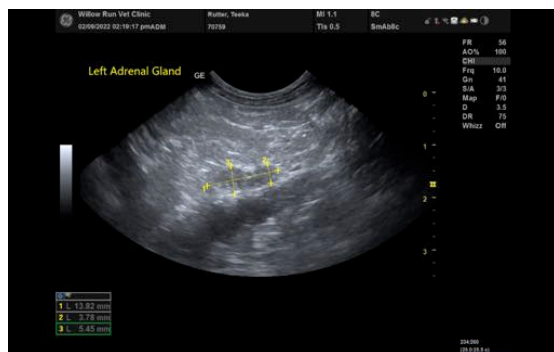
INVOICE

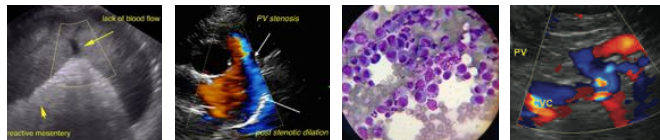
95937

DATE

2/9/22

- Consider close evaluation of history for possible toxic changes examine medications, diet, dietary indiscretion etc...
- Consider PCR on urine/serum for leptospirosis (if not on antibiotics)/serology if recent antibiotic history
- If not already done, consider pre and post prandial bile acids to evaluate liver function
- If the ALP is significantly elevated relative to the ALT and symptoms consistent with Cushing's are present, consider adrenal function testing (ACTH stim)
- Consider Fine needle aspirate if round cell neoplasia is on your differentia list (25 g needle, normal coags)
- If no response to medical therapy (Denamarin, antibiotics,+/- ursodiol etc...) Consider liver biopsy with samples obtained for histopathology, culture, and copper levels.





PATIENT

Teeka Rutter

SPECIES

Canine

BREED

Chihuahua

SEX

Spayed Female

AGE

11 years

WEIGHT

4.8 lbs

INTERPRETED BY

Kathleen Sennello
DVM, MS, Diplomate
ACVIM (Small Animal
Internal Medicine)

**IMAGING
PERFORMED BY**

Jack Reese

HOSPITAL NAME

Willow Run VC

REFERRING VET

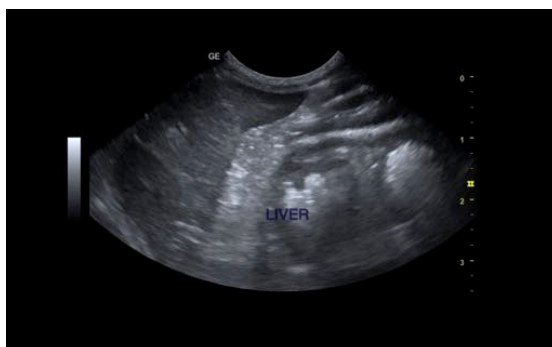Dr. Leppien

INVOICE

95937

DATE

2/9/22



The information and recommendations provided are based on the images presented by the referring veterinarian/sonographer. No evaluation can be communicated regarding pathology that was not visible in the image/video clips provided.

Thank you for this referral. If the clinical or image interpretation does not parallel your findings or if I can be of any further assistance please contact me.

Kathleen Sennello DVM,MS, Diplomate ACVIM (Small animal Internal Medicine)
kathleen.sennello@sonopath.com