



PATIENT

Rocky Proudfoot

PRESENTING CLINICAL SIGNS

Maintenance scan - has proteinuria, enlarged left adrenal gland on last ultrasound, elevated liver values. Abnormal PE/Chem/CBC/UA Results: No new labwork since last scan.

SPECIES

Canine

ULTRASONOGRAPHIC EXAMINATION OF THE ABDOMEN

BREED

Yorkie

Urinary System

The urinary bladder is moderately distended with anechoic urine. The bladder wall, trigone, ureteral papillae and visible urethra (to a depth of 2cm) appear normal with no evidence of wall thickening, mucosal irregularities or masses. There are two small piles of shadowing mineralized debris present. This is most consistent with a pile of small calculi. The appearance is similar to that of the previous scan.

SEX

Neutered male

The prostate is normal in size (0.64 cm) and shape for this neutered male dog. The parenchyma is homogenous and the external margins are smooth. The prostatic urethra appears normal with no evidence of irregularity, invasion, mass effect or calculi.

AGE

13 years

The left kidney has a normal shape and size (4.12 cm). Overall echogenicity is slightly hyperechoic with poor corticomedullary distinction and a typical 1:3 cortex:medulla ratio. There is no evidence of perinephric inflammation or effusion. Small, non-obstructive nephroliths were noted. There is no evidence of pyelectasia, infarcts or hydroureter. Renal vasculature is normal.

WEIGHT

12.5 lbs

The right kidney has a normal shape and size (4.09 cm). Overall echogenicity is slightly hyperechoic with poor corticomedullary distinction and a typical 1:3 cortex:medulla ratio. There is no evidence of perinephric inflammation or effusion. Small, non-obstructive nephroliths were noted. There is no evidence of pyelectasia, infarcts or hydroureter. Renal vasculature is normal.

INTERPRETED BY

Kathleen Sennello
DVM, MS, Diplomate
ACVIM (Small Animal
Internal Medicine)

Adrenal Glands

The left adrenal gland is large in size measuring 0.31 cm at the cranial pole, 1.16 cm at the caudal pole with a length of 1.5 cm. It is observed in its normal position cranial to the left renal artery. It is abnormal in appearance in that there is a large nodule in the caudal pole of the left adrenal measuring 1.16 x 1.1 cm (previous measurement on 11/3/21 was 0.98 x 1.05 cm).

IMAGING PERFORMED BY

Chaley Hunt LVT

The right adrenal gland is normal in size measuring 0.61 cm at the caudal pole. It is observed in its normal position between the cranial aspect of the right kidney and the caudal vena cava. It is normal in appearance (uniformly hypoechoic) and shape with no evidence of a mass effect.

HOSPITAL NAME

Columbia AC

Spleen

The spleen is subjectively normal in size, echotexture is homogenous, and the splenic capsule is smooth with no irregularities. The blood flow through the hilus and splenic parenchyma appears normal. No focal parenchymal abnormalities are visualized.

REFERRING VET

Dr. Baker

INVOICE

95936

Liver

The liver is subjectively large in size, and echogenicity with smooth peripheral margins. The parenchyma is heterogenous in echotexture with subtle, indistinct focal mottling. The visible portions of the

DATE

2/9/22



PATIENT

Rocky Proudfoot

SPECIES

Canine

BREED

Yorkie

SEX

Neutered male

AGE

13 years

WEIGHT

12.5 lbs

INTERPRETED BY

Kathleen Sennello
DVM, MS, Diplomate
ACVIM (Small Animal
Internal Medicine)

IMAGING PERFORMED BY

Chaley Hunt LVT

HOSPITAL NAME

Columbia AC

REFERRING VET

Dr. Baker

INVOICE

95936

DATE

2/9/22

vasculature and biliary tract appear normal. No focal nodules or cystic lesions are observed. The gallbladder lumen is moderately distended. The wall of the gallbladder is not thickened and has a smooth mucosal surface. Luminal contents are primarily anechoic, but there is a focal, hyperechoic, mildly shadowing structure near the junction of the bile duct measuring 0.99 x 0.72 cm. This is most consistent with echogenic debris or a soft tissue lesion (previous measurement on 11/3/21 was 0.86 x 0.73 cm). The lesion appears stable from previous exam. The cystic and common bile ducts are normal/not visible.

Gastrointestinal

The stomach contains minimal luminal contents. It measures at a normal thickness of <0.7cm with some variability due to the presence of rugal folds. The distinction of the gastric wall layers is adequate and there is no impression of reduced peristaltic activity. No masses or focal lesions were observed.

The visualized areas of duodenum, jejunum and ileum have a uniform diameter with minimal fluid distension. Wall appears subjectively, mildly increased. Bowel loops follow a typical curvilinear path with distinct wall layering. The duodenum measured 0.44 cm and the jejunum measured 0.34 cm. Visualized peristalsis appears appropriate. There were no focal lesions consistent with obstruction or a mass effect observed.

The ileocecal junction was visualized and exhibited normal intact wall layering and is subjectively of normal thickness. Sections of colon are visualized with formed fecal material and gas shadowing distally. There is no observed focal or generalized colon wall thickening or loss of layering.

Pancreas

The pancreas is normal and isoechoic to surrounding mesentery. There is no evidence of nodules or cystic lesions. There is no evidence of regional mesenteric inflammation or fluid.

Free Abdomen

Evaluation of the peritoneal cavity did not reveal any evidence of effusion, or subjective lymphadenomegaly. The Medial iliac nodes appear normal and there was no evidence of a caudal aortic thrombus at the bifurcation. The omentum is of normal uniform echogenicity.

ULTRASONOGRAPHIC FINDINGS

PRIMARY FINDINGS:

- Nodule in the caudal pole of the left adrenal gland. This nodule is prominent and slightly larger than previous measurements, but subjectively there has been no significant change.
- Dependent debris/calculi in the urinary bladder. The findings are most consistent with sand debris or small calculi. Correlate with abdominal radiographs, urinalysis and culture findings.
- Decreased corticomedullary distinction in both kidneys with non-obstructive nephroliths. The bilateral renal findings are consistent with age-related change. The hyperechoic mineralized foci observed at the corticomedullary junction of the left/right kidney are consistent with small, non-obstructive nephroliths.



PATIENT

Rocky Proudfoot

- Large heterogenous liver. The diffuse hepatic changes are non-specific and could be consistent with vacuolar hepatopathy, nodular hyperplasia, inflammatory/immune-mediated disease, fibrosis, extramedullary hematopoiesis, toxic hepatopathy (e.g., copper), infiltrative neoplasia (less likely) or other hepatopathy.

SPECIES

Canine

- Rounded shadowing structure visualized within the gallbladder. This could represent a mass, polyp or organized debris. This lesion appears unchanged from the previous exam on 11/3/21.

BREED

Yorkie

- Mildly thickened small intestine. The mild small intestinal wall changes may be a normal variant in this patient or could be consistent with an inflammatory process (e.g., inflammatory bowel disease).

SEX

Neutered male

INTERPRETATION OF THE FINDINGS & FURTHER RECOMMENDATIONS

Today's scan appears relatively similar to the previous scan on 11/3/21. The left adrenal gland may be subtle more prominent, but there has not been any significant change. Additionally the lesions associated with the bladder, kidneys, liver and gallbladder all appear relatively static. The findings should be correlated with blood work and urine protein to creatinine ratio levels, etc. as lab values will be more sensitive parameter to follow. There is no significant change in recommendations other than I am less concerned about a very aggressive adrenal mass and the lesion in the gallbladder is more likely benign and incidental.

AGE

13 years

WEIGHT

12.5 lbs

- Consider blood pressure evaluation, three view thoracic radiographs and if further therapy is desired for the adrenal nodule a CT scan and adrenal function testing is recommended.
- Consider urinalysis and urine culture periodically to evaluate the calculi present and to evaluate the suspected underlying renal disease.

INTERPRETED BY

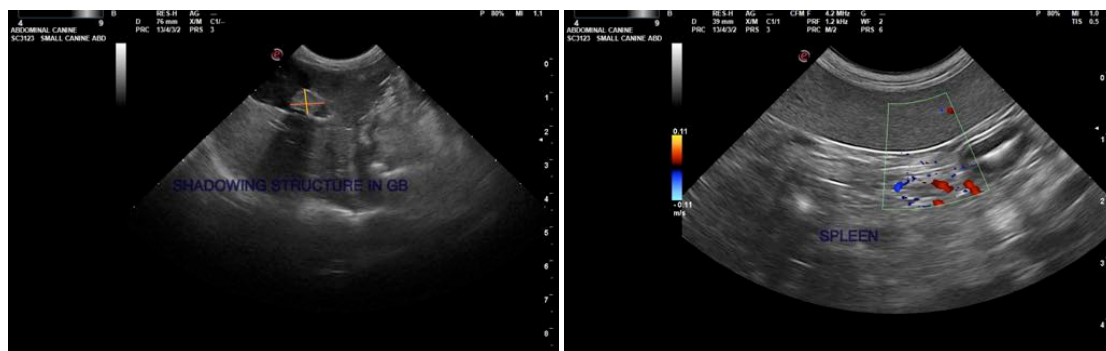
Kathleen Sennello
DVM, MS, Diplomate
ACVIM (Small Animal
Internal Medicine)

IMAGING PERFORMED BY

Chaley Hunt LVT

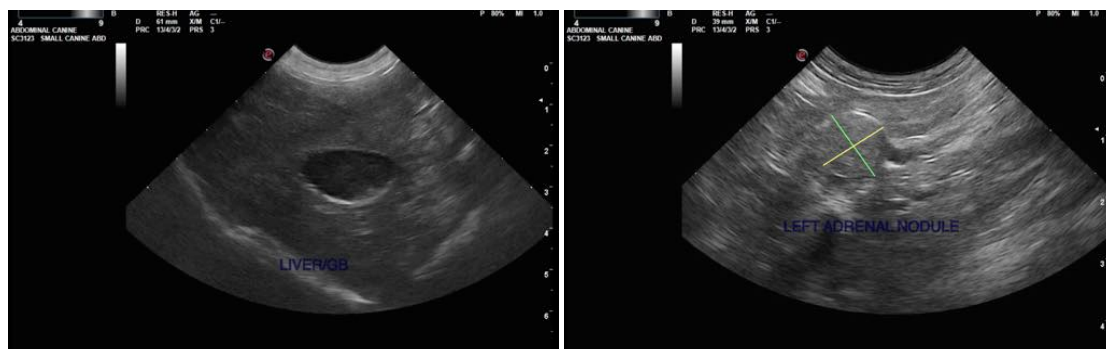HOSPITAL NAME

Columbia AC



REFERRING VET

Dr. Baker



INVOICE

95936

DATE

2/9/22



PATIENT

Rocky Proudfoot

SPECIES

Canine

BREED

Yorkie

SEX

Neutered male

AGE

13 years

WEIGHT

12.5 lbs

INTERPRETED BY

Kathleen Sennello
DVM, MS, Diplomate
ACVIM (Small Animal
Internal Medicine)

IMAGING PERFORMED BY

Chaley Hunt LVT

HOSPITAL NAME

Columbia AC

REFERRING VET

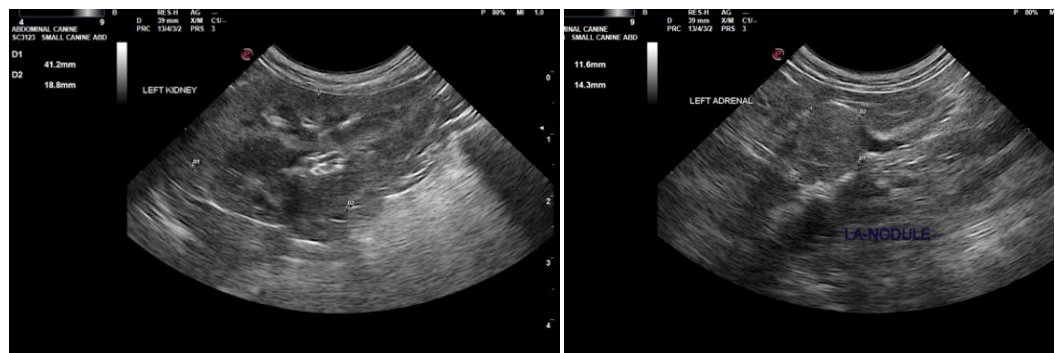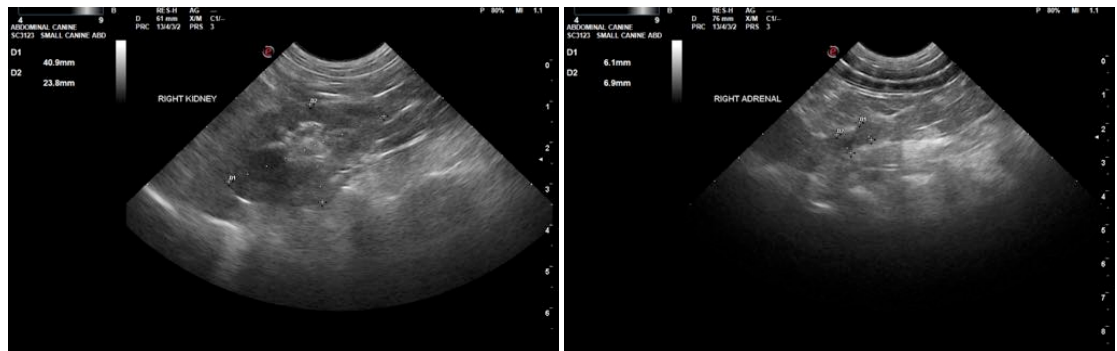
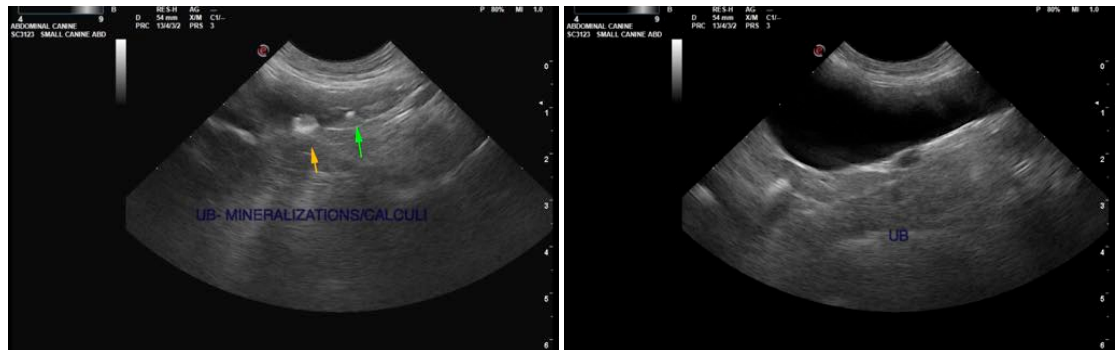Dr. Baker

INVOICE

95936

DATE

2/9/22



The information and recommendations provided are based on the images presented by the referring veterinarian/sonographer. No evaluation can be communicated regarding pathology that was not visible in the image/video clips provided.

Thank you for this referral. If the clinical or image interpretation does not parallel your findings or if I can be of any further assistance please contact me.

Kathleen Sennello DVM,MS, Diplomate ACVIM (Small animal Internal Medicine)
kathleen.sennello@sonopath.com