

**DATE**

2/9/22

PRESENTING CLINICAL SIGNS

History: Concern for a possible bowel mass on US last April. Owner opted not to move forward with biopsies and wanted to do comfort care. Pet was started on prednisolone and has responded OK since. Pet has had a waxing and waning appetite with steady, slight weight loss throughout. Pet was recently seen for routine senior exam and a new heart murmur was appreciated. Recheck abdominal US and an echocardiogram were recommended. Grade 2-3/6 murmur.

PATIENT

Losey Olvera

Current Medications: Elura 9mg PO SID trial started 1/11/22. Prednisolone 2mg PO EOD-medication originally started 04/21 but has been tapered since. SQ fluid administration twice weekly. Ondansetron 0.5mg given SQ as needed (last dose 12/22/21).

SPECIES

Feline

Date of Previous IntraPet Ultrasound: 4-14-21.

Sedation: Not required to complete full diagnostic ultrasound.

Stat Report: Not requested.

BREED

Domestic Shorthair

Imaging Performed By:

ULTRASONOGRAPHIC EXAMINATION OF THE ABDOMEN**SEX**

Spayed Female

Urinary System

The urinary bladder is moderately distended with anechoic urine. The bladder wall, trigone, ureteral papillae and visible urethra (to a depth of 2cm) appear normal with no evidence of wall thickening, mucosal irregularities, masses or cystic calculi.

AGE

5/1/08

The left kidney has a normal shape and size (3.58 cm). Overall echogenicity is slightly hyperechoic with poor corticomedullary distinction and a typical 1:3 cortex:medulla ratio. There is no evidence of perinephric inflammation or effusion. It is somewhat irregular with evidence of a previous infarct. There is no evidence of pyelectasia, nephroliths, infarcts or hydroureter. Renal vasculature is normal.

WEIGHT

10.06 lbs

The right kidney has a normal shape and size (3.6 cm). Overall echogenicity is slightly hyperechoic with poor corticomedullary distinction and a typical 1:3 cortex:medulla ratio. There is no evidence of perinephric inflammation or effusion. There is no evidence of pyelectasia, nephroliths, infarcts or hydroureter. Renal vasculature is normal.

INTERPRETED BY

Kathleen Sennello
DVM, MS, Diplomate
ACVIM (Small Animal
Internal Medicine)

Adrenal Glands

The region of left adrenal (Cranial to left renal artery) is unremarkable but the adrenal is not distinctly visualized. No evidence of a mass effect.

HOSPITAL NAME

Westminster VH

The region of the right adrenal (between right cranial kidney and vena cava) is unremarkable, but the adrenal is not distinctly visualized. No evidence of a mass effect.

Spleen**REFERRING VET**

Dr. Hall

The spleen is subjectively normal in size, echotexture is homogenous, and the splenic capsule is smooth with no irregularities. The blood flow through the hilus and splenic parenchyma appears normal. No focal parenchymal abnormalities are visualized.

INVOICE

95943

Liver

The liver is subjectively normal in size, and echogenicity with smooth peripheral margins. The parenchyma is homogenous echotexture. The visible portions of the vasculature and biliary tract appear normal. No focal nodules or cystic lesions are observed. The gallbladder lumen is moderately distended. The wall of the gallbladder is not thickened and has a smooth mucosal surface. Luminal contents are primarily anechoic. The cystic and common bile ducts are normal/not visible.

Gastrointestinal

The stomach contains minimal luminal contents. It measures at a normal thickness of <0.36cm with some variability due to the presence of rugal folds. The distinction of the gastric wall layers is adequate and there is no impression of reduced peristaltic activity. No masses or focal lesions were observed.

The visualized areas of duodenum, jejunum and ileum have a uniform diameter with minimal fluid distension. Wall thickness is normal to slightly increased. The jejunum measured 0.32 cm. Bowel loops follow a typical curvilinear path with distinct wall layering, but some areas display a prominent muscularis layer which does not display the typical 1:3 muscularis:mucosa layer ratio. Visualized peristalsis appears appropriate. There is a persistent section of small intestine, which has a complete loss of layering a thick, hypoechoic wall. The wall measurement varies from 0.32-0.4 cm in thickness. This is likely the same lesion visualized for 4/14/21. Subjectively it is similar, yet slightly more extensive.

The ileocecal junction was visualized and exhibited normal intact wall layering and is subjectively of normal thickness. Sections of colon are visualized with formed fecal material and gas shadowing distally. There is no observed focal or generalized colon wall thickening or loss of layering.

Pancreas

The pancreas is prominent and hypoechoic as compared to the surrounding isoechoic mesentery. There is no evidence of nodules or cystic lesions. There is no evidence of regional mesenteric inflammation or fluid.

Free Abdomen

There is a cluster of prominent mesenteric lymph nodes surrounded by hyperechoic mesentery in the area of the ileocecal junction. The lymph nodes in this area measure 0.23 cm and 0.27 cm. The omentum is of normal uniform echogenicity.

ULTRASONOGRAPHIC FINDINGS

PRIMARY FINDINGS:

- Persistent focal area of small intestine with complete loss of layering and intestinal wall thickening. This is most consistent with a focal bowel mass.
- Mild mesenteric lymphadenopathy. The prominent abdominal lymph nodes are most consistent with reactive lymphadenitis or lymphoid hyperplasia. Neoplastic infiltration is considered less likely.

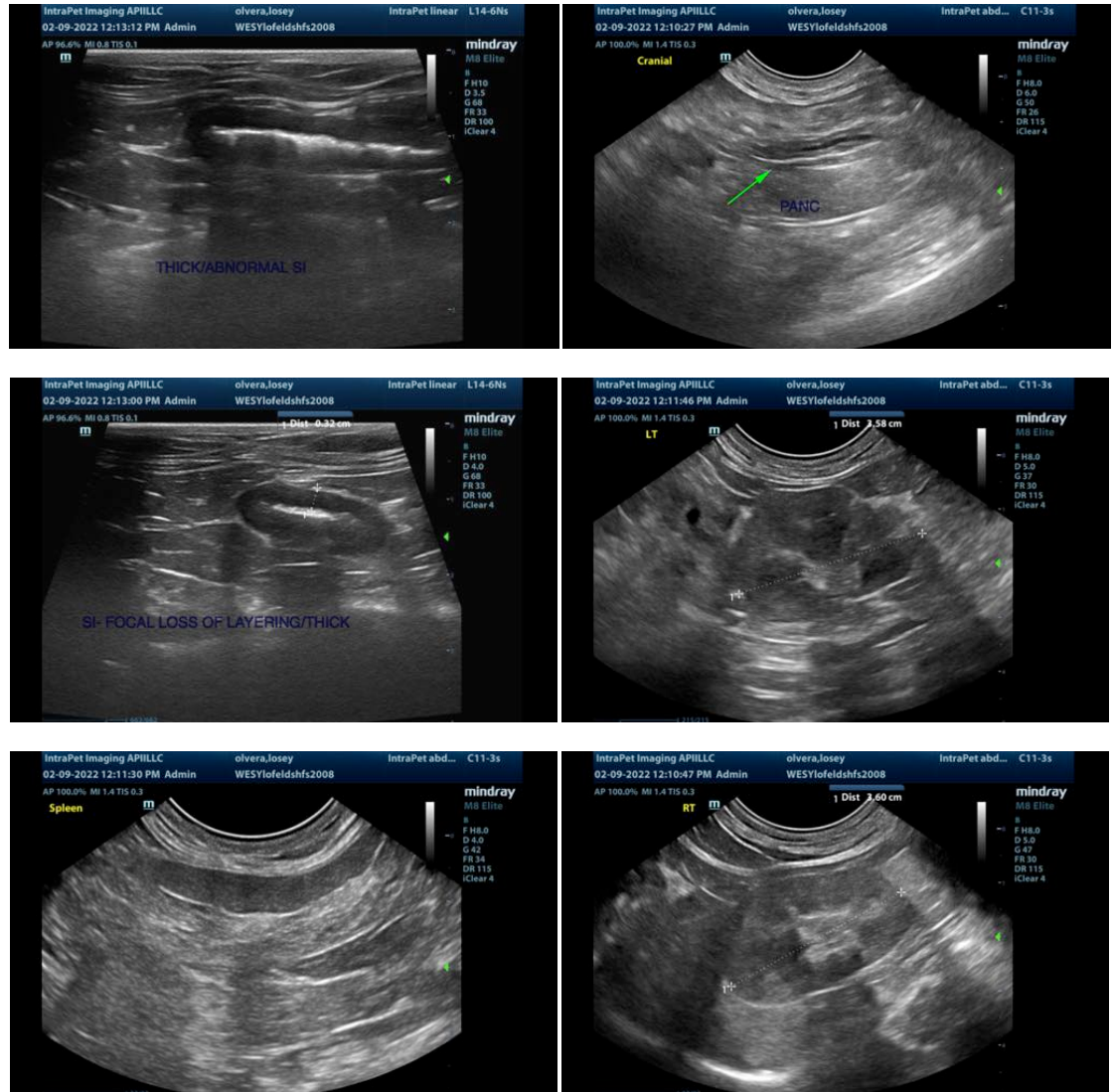
SECONDARY FINDINGS:

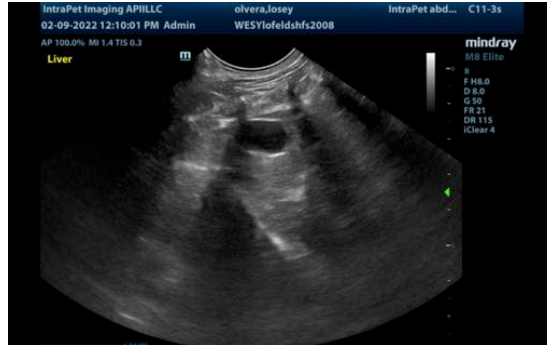- Hypoechoic prominent pancreas. The pancreatic changes are most consistent with age-related parenchymal remodeling, potentially secondary to a prior inflammatory episode, early fibrosis or chronic pancreatitis.
- Mildly reduced corticomedullary distinction in both kidneys. The bilateral renal findings are consistent with age-related change.

INTERPRETATION OF THE FINDINGS & FURTHER RECOMMENDATIONS

The changes previously visualized in the small intestine on 4/14/21 are persistent and subjectively appear to involve a greater length of small intestine. The most likely differential at this time would be round cell neoplasia although severe IBD, carcinoma, etc. are also possibilities. I suspect steroid therapy has been slowing progression of this process. If a diagnosis is desired at this time you can consider a FNA of the bowel wall or surgical biopsies although steroid use could partially impair the ability to get a definitive diagnosis. There is no evidence of obstruction at this time and you are doing a good job with symptomatic therapy.

Often these patients are B12 deficient so you may consider a GI panel or at least B12 levels to determine if supplementation could be helpful. Consider three view thoracic radiographs to look for any concurrent intrathoracic disease.





The information and recommendations provided are based on the images presented by the referring veterinarian. No evaluation can be communicated regarding pathology that was not visible in the image/video clips provided.

Thank you for this referral. If the clinical or image interpretation does not parallel your findings or if I can be of any further assistance please contact me.

Kathleen Sennello DVM,MS, Diplomate ACVIM (Small animal Internal Medicine)
kathleen.sennello@sonopath.com