

**DATE**

2/9/2022

PRESENTING CLINICAL SIGNS

History: heavy breathing worsening; uncomfortable; clingy. Previous radiographs reveal hepatomegaly and splenomegaly. Pu/pd w/ negative LDDs 8/2021.

Current Medications: Gabapentin 300mg q12hrs, Denamarin advanced q 24 hrs.

Lab Results: labs pasted into form inadmissible. full labwork is pending from clinic,

Radiographs: Attached separately.

Date of Previous IntraPet Ultrasound: No previous IntraPet scans.

Sedation: DECLINED.

Stat Report: Not requested.

Imaging Performed By:

PATIENT

Leon Johnson

SPECIES

Canine

BREED

Pitbull Terrier

SEX

Neutered male

AGE

6/9/09

WEIGHT

67 lbs

ULTRASONOGRAPHIC EXAMINATION OF THE ABDOMEN

*****Patient evaluation was negatively impacted by lack of sedation (this was declined) and lack of fasting.**

Urinary System

The urinary bladder is moderately distended with anechoic urine. The Bladder wall, trigone, ureteral papillae and visible urethra (to a depth of 2cm) appear normal with no evidence of wall thickening, mucosal irregularities, masses or cystic calculi.

The visualized areas of prostate and surrounding tissue appear normal. Unfortunately, the prostate is not fully visualized likely due to its intrapelvic location. Correlate with rectal exam findings.

The left kidney has a normal shape and size (7.5 cm). Overall echogenicity is slightly hyperechoic with poor corticomedullary distinction and a typical 1:3 cortex:medulla ratio. There is no evidence of perinephric inflammation or effusion. There is no evidence of pyelectasia, nephroliths, infarcts or hydroureter. Renal vasculature is normal.

The right kidney has a normal shape and size (7.66 cm). Overall echogenicity is slightly hyperechoic with poor corticomedullary distinction and a typical 1:3 cortex:medulla ratio. There is no evidence of perinephric inflammation or effusion. There is no evidence of pyelectasia, nephroliths, infarcts or hydroureter. Renal vasculature is normal.

Adrenal Glands

The left adrenal gland is borderline large in size measuring 1.0 cm at the caudal pole It is observed in its normal position cranial to the left renal artery. It is normal in appearance (uniformly hypoechoic) and shape with no evidence of a mass effect.

The right adrenal gland is difficult to see due to lack of penetration and patient discomfort. Sedation was offered at the time of scan, but declined. There is suggestion of an enlarged right adrenal gland, but the images are not clear.

INVOICE

95944

Spleen

The spleen is subjectively large in size. The spleen is nodular with a very heterogenous echotexture and numerous hyperechoic foci. The spleen echotexture is heterogenous and mottled, the splenic capsule is smooth with no irregularities. The blood flow through the hilus and splenic parenchyma appears normal. No focal parenchymal abnormalities are visualized.

INTERPRETED BY

Kathleen Sennello
DVM, MS, Diplomate
ACVIM (Small Animal
Internal Medicine)

HOSPITAL NAME

Eldersburg VH

REFERRING VET

Dr. James

Liver

The liver is subjectively large in size, and echogenicity with smooth peripheral margins. The parenchyma is heterogenous in echotexture with subtle, indistinct focal mottling. The visible portions of the vasculature and biliary tract appear normal. There is a well defined, mixed echogenic, somewhat cystic mass effect towards the medial aspect of the liver measuring 3.1 x 2.83 cm. The gallbladder lumen is moderately distended. The wall of the gallbladder is hyperechoic and irregular due to adherent debris. There is not a lot of non-adherent intraluminal debris present and there was no surrounding inflammation. The cystic and common bile ducts are normal/not visible.

Gastrointestinal

The stomach is moderately dilated with fluid and irregular shadowing material most consistent with normal ingesta and gas. It measures at a normal thickness of <0.7cm with some variability due to the presence of rugal folds. The distinction of the gastric wall layering is adequate and there is no impression of reduced peristaltic activity. No masses or focal lesions were observed.

The visualized areas of duodenum, jejunum and ileum have a relatively uniform diameter with minimal fluid distension. Wall thickness is normal. Bowel loops follow a curvilinear path with distinct wall layering maintaining the typical 1:3 muscularis:mucosa layer ratio. The duodenum measured as normal (between 0.3-0.5cm in wall thickness) and the jejunum measured as normal (between 0.2-0.47cm.) Visualized peristalsis appears appropriate. There were no focal lesions consistent with obstruction or a mass effect observed.

The ileocecal junction was visualized and exhibited normal intact wall layering and is subjectively of normal thickness. Sections of colon are visualized with formed fecal material and gas shadowing distally. There is no observed focal or generalized colon wall thickening or loss of layering.

Pancreas

The region pancreas is normal and isoechoic to surrounding mesentery. There is no evidence of nodules or cystic lesions. There is no evidence of regional mesenteric inflammation or fluid.

Free Abdomen

Evaluation of the peritoneal cavity did not reveal any evidence of effusion, or subjective lymphadenomegaly. The Medial iliac nodes appear normal and there was no evidence of a caudal aortic thrombus at the bifurcation. The omentum is of normal uniform echogenicity.

Heart

Several brief views of the heart were submitted and there appears to be a lesion at the heart base that is most consistent with a heart base mass measuring 2.7 x 2.9 cm.

ULTRASONOGRAPHIC FINDINGS

PRIMARY FINDINGS:

- Large, severely mottled spleen. The diffuse splenic changes are non-specific and could be consistent with lymphoid hyperplasia, extramedullary hematopoiesis, infiltrative neoplasia, inflammation, other. Cytology or histopathology would be necessary to get a definitive diagnosis.
- Large heterogenous liver with mixed echogenic cystic mass effect. The diffuse hepatic changes are non-specific and could be consistent with vacuolar hepatopathy, nodular hyperplasia, inflammatory/immune-mediated disease, fibrosis, extramedullary hematopoiesis, toxic hepatopathy

(e.g., copper), infiltrative neoplasia (less likely) or other hepatopathy.

- Borderline large left adrenal gland with the suspicion of an abnormal right adrenal gland.
- Strongly suspect heart base. Recommend cardiac ultrasound.

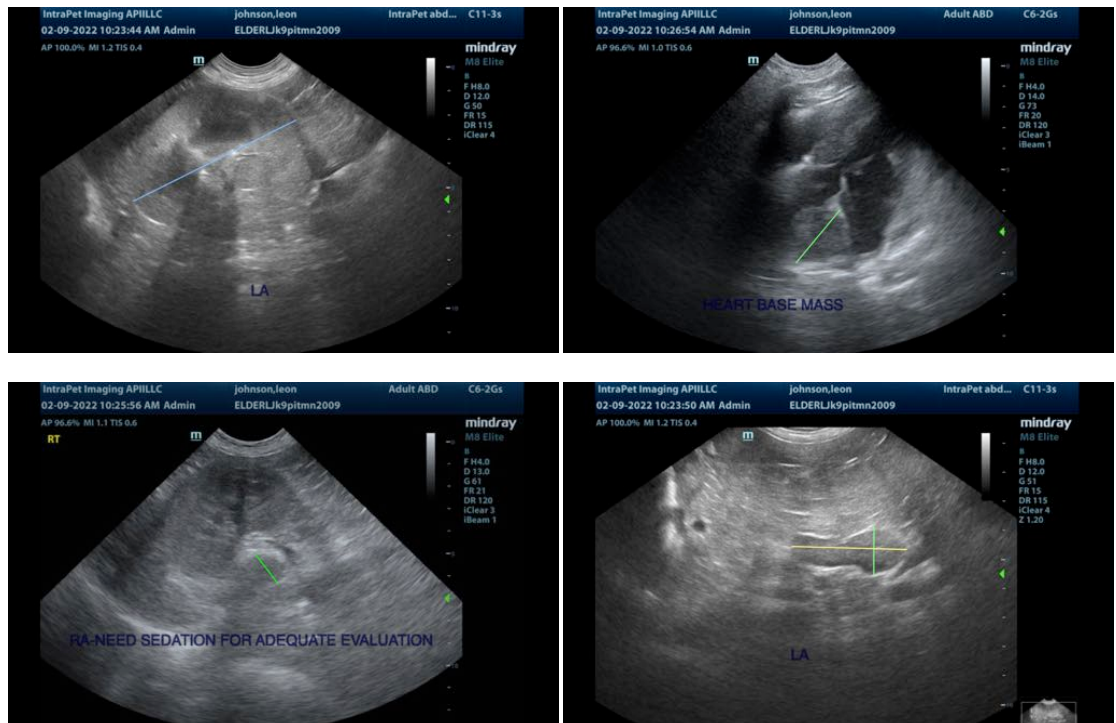
SECONDARY FINDINGS:

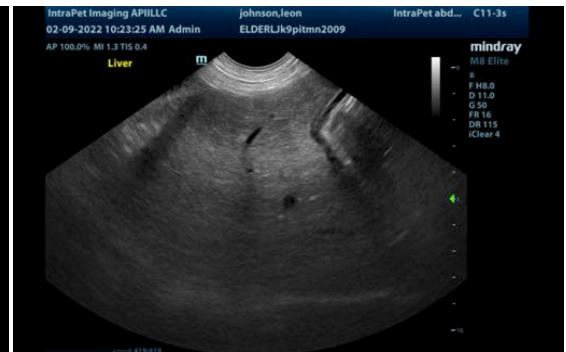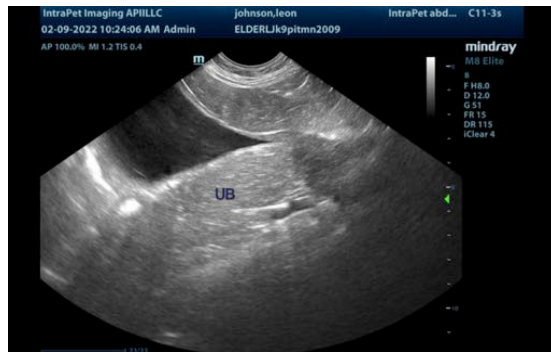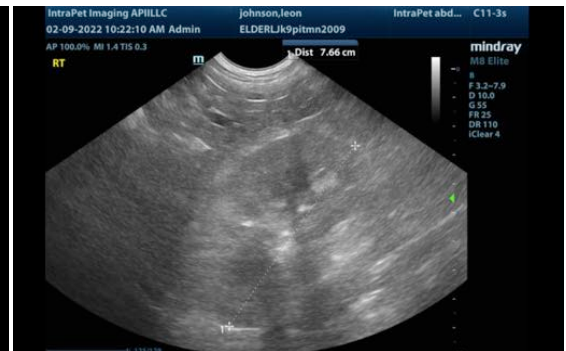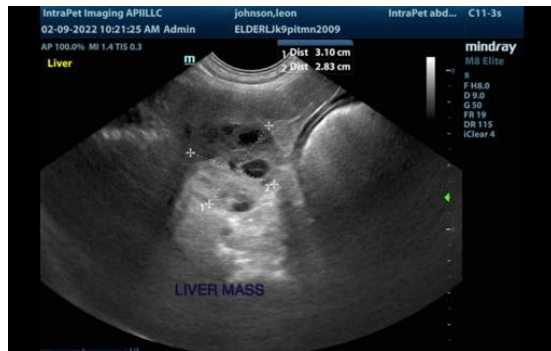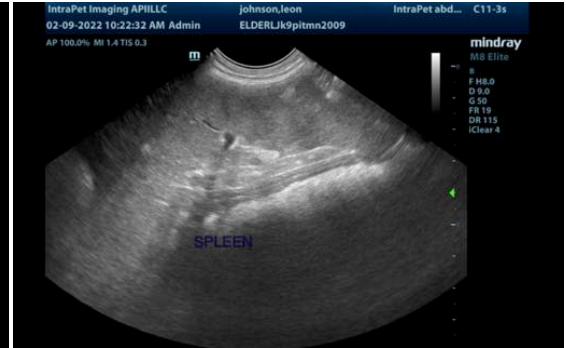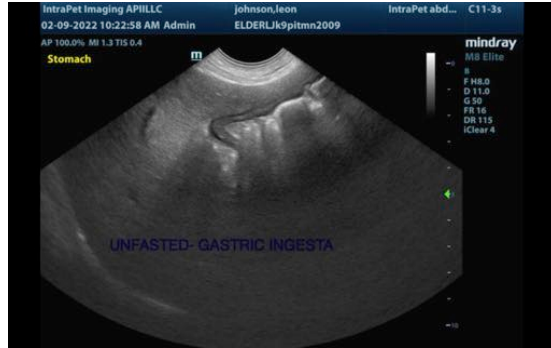- Decreased corticomedullary distinction in both kidneys. The bilateral renal findings are consistent with age-related change.
- Adherent debris in the gallbladder wall. There is no evidence of surrounding inflammation. I recommend continued monitoring.
- Large ingesta within the gastric lumen. The patient was not adequately fasted.

INTERPRETATION OF THE FINDINGS & FURTHER RECOMMENDATIONS

The combination of the liver mass, mottled spleen and suspected heart base mass is concerning for a possible underlying neoplastic disease process. I recommend a FNA of the spleen and three view thoracic radiographs. Additionally recommend a cardiac ultrasound to further evaluate the heart. If a diagnosis cannot be obtained based on cytology. Options would include an abdominal CT scan to further evaluate the extent of the disease process or exploratory surgery to biopsy/remove the spleen, biopsy the liver mass, etc. The prognosis is guarded due to the diffuse nature of these lesions.

Re-evaluation with sedation would be necessary to adequately evaluate the liver, kidneys and adrenal glands





The information and recommendations provided are based on the images presented by the referring veterinarian. No evaluation can be communicated regarding pathology that was not visible in the image/video clips provided.

Thank you for this referral. If the clinical or image interpretation does not parallel your findings or if I can be of any further assistance please contact me.

Kathleen Sennello DVM,MS, Diplomate ACVIM (Small animal Internal Medicine)
kathleen.sennello@sonopath.com