



PATIENT

Millie Jakala

SPECIES

Canine

BREED

Cairn Terrier

SEX

Spayed Female

AGE

11 Years

WEIGHT

15.2

INTERPRETED BY

Kathleen Sennello DVM,
MS, Diplomate ACVIM
(Small Animal Internal
Medicine)

IMAGING PERFORMED BY

A. Murphy, CVT

HOSPITAL NAME

Wauwatosa Vet

REFERRING VET

Dr. Ericka Haynes

INVOICE

44943

DATE

2/8/23

PRESENTING CLINICAL SIGNS

6 week history of decreased appetite. Lethargy, occasional loose stool. Symptoms coincided with loss of patient's house mate. No significant abnormalities present on CBC/chem panel. Pyuria and bacteria present on urinalysis. Patient treated for urinary tract infection, but no improvement with symptoms. Screening for abdominal visceral pathology.

ULTRASONOGRAPHIC EXAMINATION OF THE ABDOMEN

Urinary System

The urinary bladder is moderately distended with anechoic urine. The Bladder wall, trigone, ureteral papillae and visible urethra (to a depth of 2cm) appear normal with no evidence of wall thickening, mucosal irregularities, masses or cystic calculi.

The left kidney has a normal shape and size (4.27 cm). Overall echogenicity is normal with adequate corticomedullary distinction and a typical 1:3 cortex:medulla ratio. There is no evidence of focal perinephric inflammation or effusion. There is no evidence of pyelectasia, nephroliths, infarcts or hydroureter. Renal vasculature is normal.

The right kidney has a normal shape and size (4.39 cm). Overall echogenicity is normal with adequate corticomedullary distinction and a typical 1:3 cortex:medulla ratio. There is no evidence of focal perinephric inflammation or effusion. There is no evidence of pyelectasia, nephroliths, infarcts or hydroureter. Renal vasculature is normal.

Adrenal Glands

The left adrenal gland is normal in size measuring 0.56 cm at the caudal pole. It is observed in its normal position cranial to the left renal artery. It is normal in appearance (uniformly hypoechoic) and shape with no evidence of a mass effect.

The region of the right adrenal (between right cranial kidney and vena cava) is unremarkable, but the adrenal is not distinctly visualized. No evidence of a mass effect is visualized.

Spleen

The spleen is subjectively normal in size, echotexture is homogenous, and the splenic capsule is smooth with no irregularities. The blood flow through the hilus and splenic parenchyma appears normal. No focal parenchymal abnormalities are visualized.

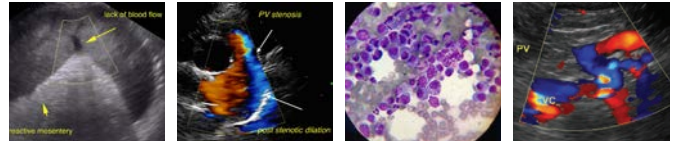
Liver

The liver is large in size, and normal in echogenicity with smooth peripheral margins. The parenchyma is heterogenous in echotexture with subtle, indistinct focal mottling. The visible portions of the vasculature and biliary tract appear normal. No focal nodules or cystic lesions are observed.

The gallbladder lumen is moderately distended. The wall of the gall bladder is not thickened and has a smooth mucosal surface. Luminal contents are mild and primarily anechoic. The cystic and common bile ducts are normal/not visible.

Gastrointestinal

The stomach contains minimal luminal contents. It measures at a normal thickness of <0.7cm with some variability due to the presence of rugal folds. The distinction of the gastric wall layers is adequate and there is no impression of reduced peristaltic activity. No masses or focal lesions were observed.



PATIENT

Millie Jakala

SPECIES

Canine

BREED

Cairn Terrier

SEX

Spayed Female

AGE

11 Years

WEIGHT

15.2

INTERPRETED BY

Kathleen Sennello DVM,
MS, Diplomate ACVIM
(Small Animal Internal
Medicine)

IMAGING PERFORMED BY

A. Murphy, CVT

HOSPITAL NAME

Wauwatosa Vet

REFERRING VET

Dr. Ericka Haynes

INVOICE

44943

DATE

2/8/23

The visualized areas of duodenum, jejunum and ileum have a relatively uniform diameter with minimal fluid distension. Wall thickness is normal. Bowel loops follow a curvilinear path with distinct wall layering maintaining the typical 1:3 muscularis:mucosa layer ratio. Duodenum wall measures 0.42 cm. Jejunum wall measures 0.34 cm. Visualized peristalsis appears appropriate. There were no focal lesions consistent with obstruction or a mass effect observed.

The ileocecal junction was visualized and exhibited normal intact wall layering and is subjectively of normal thickness. Sections of colon are visualized with formed fecal material and gas shadowing distally. There is no observed focal or generalized colon wall thickening or loss of layering.

Pancreas

The pancreas is prominent and hypoechoic as compared to the surrounding isoechoic mesentery. There is no evidence of nodules or cystic lesions. There is no evidence of regional mesenteric inflammation or fluid.

Free Abdomen

Evaluation of the peritoneal cavity did not reveal any evidence of effusion, or subjective lymphadenomegaly. The Medial iliac nodes appear normal and there was no evidence of a caudal aortic thrombus at the bifurcation. The omentum is of normal uniform echogenicity.

ULTRASONOGRAPHIC FINDINGS

- Prominent, hypoechoic pancreas – The pancreatic changes are most consistent with age-related parenchymal remodeling, potentially secondary to a prior inflammatory episode, early fibrosis or chronic pancreatitis.
- Large, heterogeneous liver – The diffuse hepatic changes are non-specific and could be consistent with vacuolar hepatopathy, nodular hyperplasia, inflammatory/immune-mediated disease, fibrosis, extramedullary hematopoiesis, toxic hepatopathy (e.g., copper), infiltrative neoplasia (less likely) or other hepatopathy. In the absence of liver enzyme elevations, the significance of this is unclear.

INTERPRETATION OF THE FINDINGS & FURTHER RECOMMENDATIONS

The abnormalities described on today's scan are relatively mild. An obvious source for the decreased appetite, lethargy, etc. is not visualized. The liver appears somewhat large and heterogeneous. This could be associated with age related remodeling. The significance of this is unclear if there are no significant liver enzyme elevations on bloodwork.

Additionally, the pancreas is slightly prominent, particularly caudal to the stomach, but does not appear overtly inflamed. Correlate these findings with a quantitative PLI level. If you think the diarrhea is significant and are concerned for the possibility of gastrointestinal disease, this can sometimes have minimal ultrasonographic changes associated with it. You could consider changing to a novel protein/hydrolyzed protein prescription diet and probiotics, and performing a GI panel to Texas A&M for a qualitative PLI, TLI, cobalamin and folate, looking for further evidence of possible gastrointestinal disease and the need for further gastrointestinal workup.

Recommend three view thoracic radiographs to evaluate for possible concurrent thoracic disease/involvement.



PATIENT

Millie Jakala

SPECIES

Canine

BREED

Cairn Terrier

SEX

Spayed Female

AGE

11 Years

WEIGHT

15.2

INTERPRETED BY

Kathleen Sennello DVM,
MS, Diplomate ACVIM
(Small Animal Internal
Medicine)

**IMAGING
PERFORMED BY**

A. Murphy, CVT

HOSPITAL NAME

Wauwatosa Vet

REFERRING VET

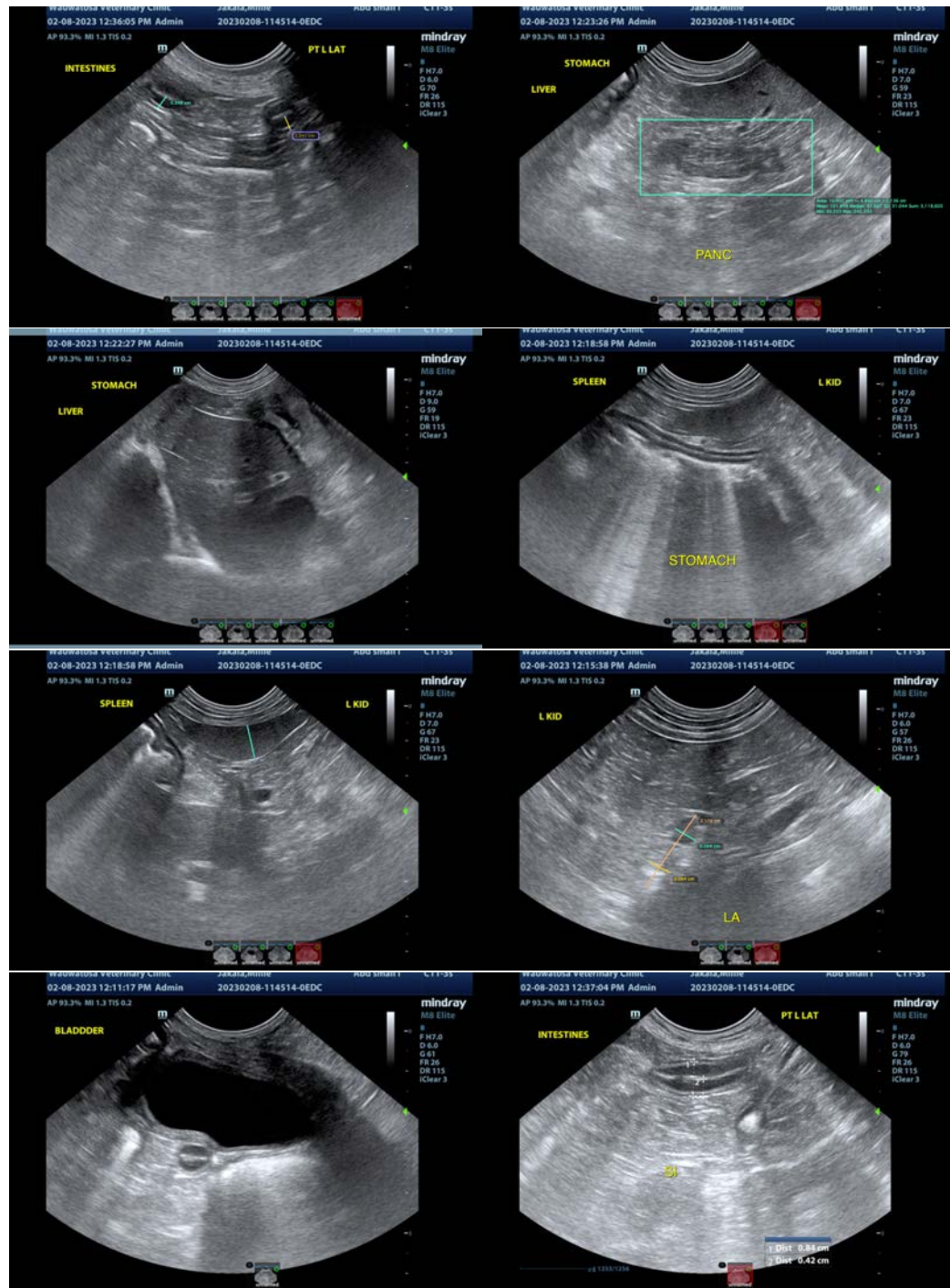
Dr. Ericka Haynes

INVOICE

44943

DATE

2/8/23





PATIENT

Millie Jakala

SPECIES

Canine

BREED

Cairn Terrier

SEX

Spayed Female

AGE

11 Years

WEIGHT

15.2

INTERPRETED BY

Kathleen Sennello DVM,
MS, Diplomate ACVIM
(Small Animal Internal
Medicine)

**IMAGING
PERFORMED BY**

A. Murphy, CVT

HOSPITAL NAME

Wauwatosa Vet

REFERRING VET

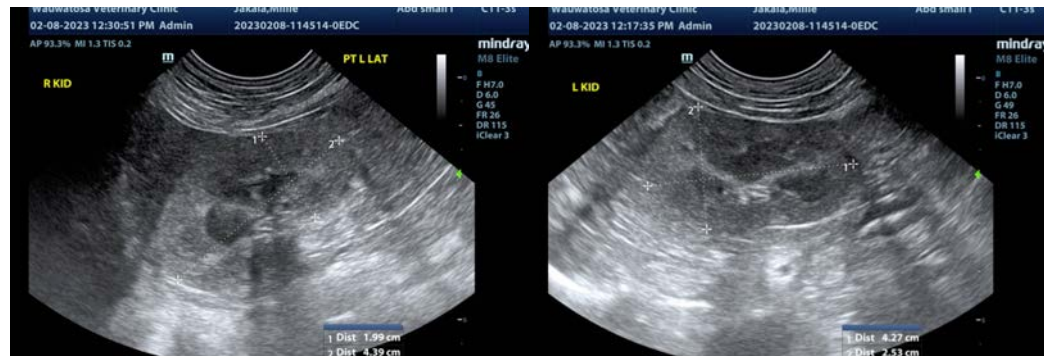
Dr. Ericka Haynes

INVOICE

44943

DATE

2/8/23



The information and recommendations provided are based on the images presented by the referring veterinarian/sonographer. No evaluation can be communicated regarding pathology that was not visible in the image/video clips provided.

Thank you for this referral. If the clinical or image interpretation does not parallel your findings or if I can be of any further assistance please contact me.

Kathleen Sennello DVM,MS, Diplomate ACVIM (Small animal Internal Medicine)

kathleen.sennello@sonopath.com