



**PATIENT**

Lexi Fowler

**SPECIES**

Canine

**BREED**

Scotty

**SEX**

Spayed Female

**AGE**

8 Years

**WEIGHT**

25

**INTERPRETED BY**

Kathleen Sennello DVM,  
MS, Diplomate ACVIM  
(Small Animal Internal  
Medicine)

**IMAGING  
PERFORMED BY**

Dr. James Hornbuckle

**HOSPITAL NAME**

Golden Isles AH

**REFERRING VET**

Dr. James Hornbuckle

**INVOICE**

44839

**DATE**

2/8/23

**PRESENTING CLINICAL SIGNS**

P has been on Galliprant for 6+ months, P came in for CBC chem and had abnormal results followed up with bile acids test also had abnormal results, Owner elected for AUS. No other current symptoms

**ULTRASONOGRAPHIC EXAMINATION OF THE ABDOMEN**

**Urinary System**

The urinary bladder is moderately distended with anechoic urine. The Bladder wall, trigone, ureteral papillae and visible urethra (to a depth of 2cm) appear normal with no evidence of wall thickening, mucosal irregularities, masses or cystic calculi.

The left kidney has a normal shape and size. Overall echogenicity is normal with mildly reduced corticomedullary distinction and a typical 1:3 cortex:medulla ratio. There is no evidence of focal perinephric inflammation or effusion. Small mineralizations and mild pyelectasia (0.26 cm) noted. There is no evidence of infarcts or hydroureter. Renal vasculature is normal.

The right kidney has a normal shape and size (6.06 cm) with small mineralizations and mild pyelectasia at 0.36 cm. Overall echogenicity is normal with mildly reduced corticomedullary distinction and a typical 1:3 cortex:medulla ratio. There is no evidence of focal perinephric inflammation or effusion. There is no evidence of infarcts or hydroureter. Renal vasculature is normal.

**Adrenal Glands**

The left adrenal gland is normal in size measuring 0.53 cm at the caudal pole. It is observed in its normal position cranial to the left renal artery. It is normal in appearance (uniformly hypoechoic) and shape with no evidence of a mass effect.

The right adrenal gland is normal in size measuring 0.54 cm at the caudal pole. It is observed in its normal position between the cranial aspect of the right kidney and the caudal vena cava. It is normal in appearance (uniformly hypoechoic) and shape with no evidence of a mass effect.

**Spleen**

The spleen is subjectively normal in size, echotexture is homogenous, and the splenic capsule is smooth with no irregularities. The blood flow through the hilus and splenic parenchyma appears normal. No focal parenchymal abnormalities are visualized.

**Liver**

The liver is large in size, and hyperechoic with smooth peripheral margins. The parenchyma is heterogenous in echotexture with subtle, indistinct focal mottling. The visible portions of the vasculature and biliary tract appear normal. No focal nodules or cystic lesions are observed.

The gallbladder lumen is moderately distended. The wall of the gall bladder is not thickened and has a smooth mucosal surface. Luminal contents are mild and primarily anechoic. The cystic and common bile ducts are normal/not visible.

**Gastrointestinal**

The stomach contains minimal luminal contents. It measures at a normal thickness of <0.7cm with some variability due to the presence of rugal folds. The distinction of the gastric wall layers is adequate and there is no impression of reduced peristaltic activity. No masses or focal lesions were observed.



**PATIENT**

Lexi Fowler

**SPECIES**

Canine

**BREED**

Scotty

**SEX**

Spayed Female

**AGE**

8 Years

**WEIGHT**

25

**INTERPRETED BY**

Kathleen Sennello DVM,  
MS, Diplomate ACVIM  
(Small Animal Internal  
Medicine)

**IMAGING PERFORMED BY**

Dr. James Hornbuckle

**HOSPITAL NAME**

Golden Isles AH

**REFERRING VET**

Dr. James Hornbuckle

**INVOICE**

44839

**DATE**

2/8/23

The visualized areas of duodenum, jejunum and ileum have a relatively uniform diameter with minimal fluid distension. Wall thickness is normal. Bowel loops follow a curvilinear path with distinct wall layering maintaining the typical 1:3 muscularis:mucosa layer ratio. Jejunum wall measures 0.38 cm. Visualized peristalsis appears appropriate. There were no focal lesions consistent with obstruction or a mass effect observed.

The ileocecal junction was visualized and exhibited normal intact wall layering and is subjectively of normal thickness. Sections of colon are visualized with formed fecal material and gas shadowing distally. There is no observed focal or generalized colon wall thickening or loss of layering.

**Pancreas**

The pancreas is normal and isoechoic to surrounding mesentery. There is no evidence of nodules or cystic lesions. There is no evidence of regional mesenteric inflammation or fluid.

**Free Abdomen**

Evaluation of the peritoneal cavity did not reveal any evidence of effusion, or subjective lymphadenomegaly. The Medial iliac nodes appear normal and there was no evidence of a caudal aortic thrombus at the bifurcation. The omentum is of normal uniform echogenicity.

**ULTRASONOGRAPHIC FINDINGS**

- Mildly reduced corticomedullary distinction in both kidneys with small mineralizations and bilateral mild pyelectasia – The bilateral renal findings are consistent with age-related change. Pyelectasia of the kidney(s) could be consistent with pyelonephritis, chronic renal disease, secondary to PU/PD or fluid therapy (if applicable), other.
- Large, heterogeneous, hyperechoic liver – The diffuse hepatic changes are non-specific and could be consistent with vacuolar hepatopathy, nodular hyperplasia, inflammatory/immune-mediated disease, fibrosis, extramedullary hematopoiesis, toxic hepatopathy (e.g., copper), infiltrative neoplasia (less likely) or other hepatopathy.

**INTERPRETATION OF THE FINDINGS & FURTHER RECOMMENDATIONS**

The liver appears large and heterogeneous with no focal lesions observed. These are non-specific findings. Given the breed, a vacuolar hepatopathy would be a concern, although many other inflammatory, infectious, and even neoplastic processes are possible. These are my recommendations or further evaluation, although a liver biopsy may be necessary to definitively diagnose this patient.

- Consider close evaluation of history for possible toxic changes examine medications, diet, dietary indiscretion etc...
- Consider PCR on urine/serum for leptospirosis (if not on antibiotics)/serology if recent antibiotic history
- If not already done, consider pre and post prandial bile acids to evaluate liver function
- If the ALP is significantly elevated relative to the ALT and symptoms consistent with Cushing's are present, consider adrenal function testing (ACTH stim)
- Consider Fine needle aspirate if round cell neoplasia is on your differential list (25 g needle, normal coags)
- If no response to supportive care (Denamarin, fluids, antibiotics, +/- ursodiol etc.) Consider liver biopsy with samples obtained for histopathology, culture, and copper levels.



**PATIENT**

Lexi Fowler

Recommend three view thoracic radiographs to evaluate for possible concurrent thoracic disease/involvement.

**SPECIES**

Canine

The renal changes observed are likely age associated. Consider a urinalysis, culture, and blood pressure evaluation as a baseline.

**BREED**

Scotty

**SEX**

Spayed Female

**AGE**

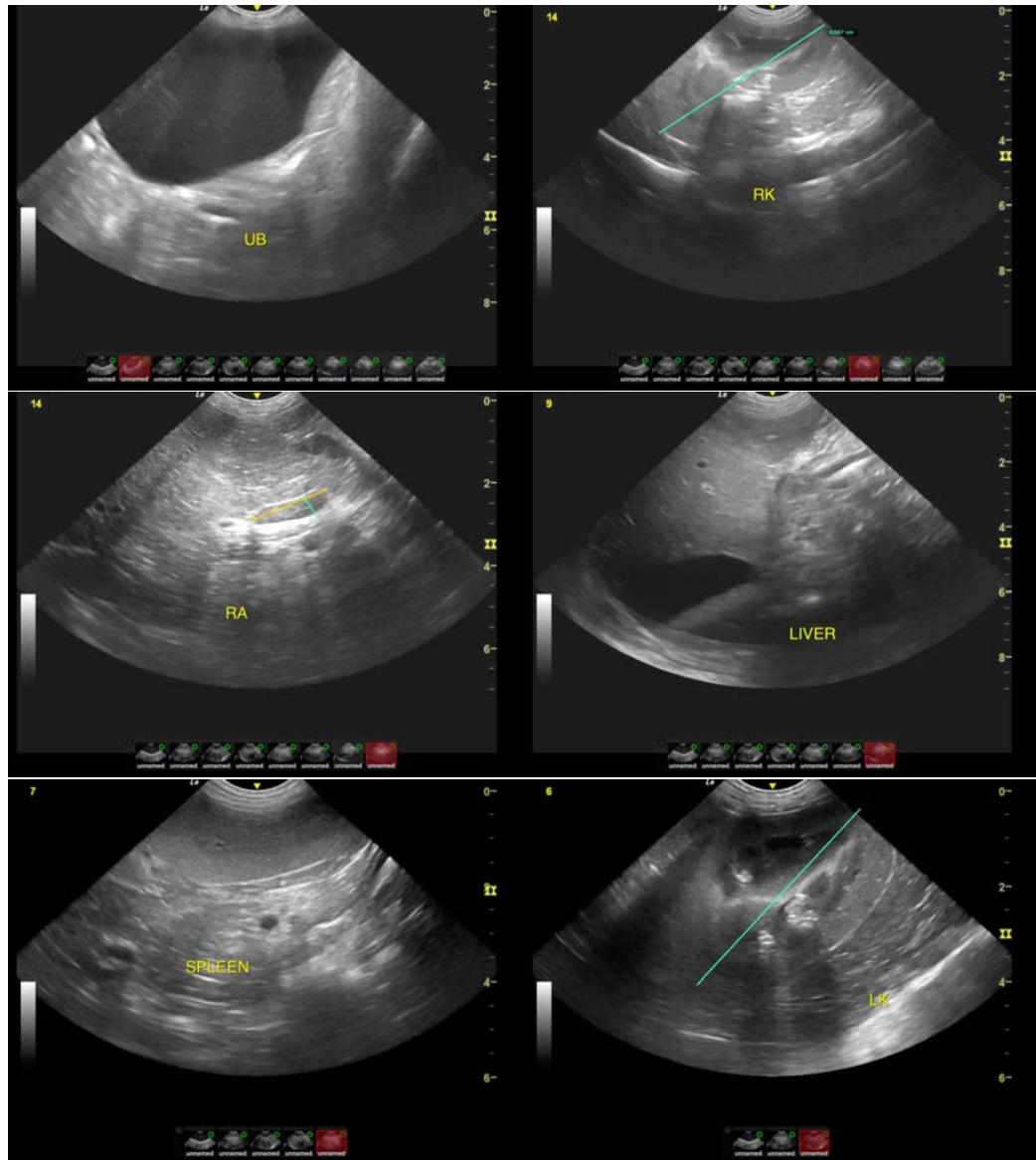
8 Years

**WEIGHT**

25

**INTERPRETED BY**

Kathleen Sennello DVM,  
MS, Diplomate ACVIM  
(Small Animal Internal  
Medicine)



**IMAGING PERFORMED BY**

Dr. James Hornbuckle

**HOSPITAL NAME**

Golden Isles AH

**REFERRING VET**

Dr. James Hornbuckle

**INVOICE**

44839

**DATE**

2/8/23



**PATIENT**

Lexi Fowler

**SPECIES**

Canine

**BREED**

Scotty

**SEX**

Spayed Female

**AGE**

8 Years

**WEIGHT**

25

**INTERPRETED BY**

Kathleen Sennello DVM,  
MS, Diplomate ACVIM  
(Small Animal Internal  
Medicine)

**IMAGING  
PERFORMED BY**

Dr. James Hornbuckle

**HOSPITAL NAME**

Golden Isles AH

**REFERRING VET**

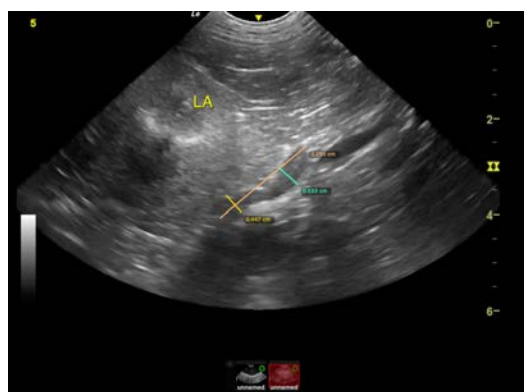
Dr. James Hornbuckle

**INVOICE**

44839

**DATE**

2/8/23



The information and recommendations provided are based on the images presented by the referring veterinarian/sonographer. No evaluation can be communicated regarding pathology that was not visible in the image/video clips provided.

Thank you for this referral. If the clinical or image interpretation does not parallel your findings or if I can be of any further assistance please contact me.

Kathleen Sennello DVM,MS, Diplomate ACVIM (Small animal Internal Medicine)

kathleen.sennello@sonopath.com