SonoPath
Clinical Sonography & Telecytology
EDUCATIONAL TELECONSULTATION SERVICES™
1-800-838-4268 info@sonopath.com SonoPath.com

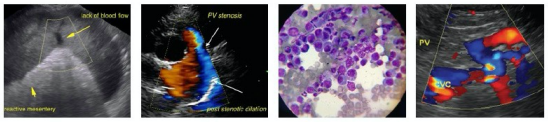

IMAGING PERFORMED BY
pawsonography@gmail.com 530-786-8340

PATIENT

Auggie Phelps

SPECIES

Canine

BREED

Scottish Terrier

SEX

Neutered Male

AGE

12 Years

WEIGHT

25 Pounds

INTERPRETED BY

Kathleen Sennello DVM, MS, Diplomate ACVIM (Small Animal Internal Medicine)

IMAGING BY

Loetitia Saint-Jacques, LVT

HOSPITAL NAME

North Hills VC

REFERRING VET

Dr. David Baggett

INVOICE

35501

DATE

2/8/22

PRESENTING CLINICAL SIGNS

high liver values (alt 770 alk phos almost 2500). Denamarin has not helped.

ULTRASONOGRAPHIC EXAMINATION OF THE ABDOMEN

Urinary System

The urinary bladder is moderately distended with anechoic urine. The Bladder wall, trigone, ureteral papillae and visible urethra (to a depth of 2cm) appear normal with no evidence of wall thickening, mucosal irregularities, masses or cystic calculi.

The prostate is normal in size (1.0 cm) and shape for this neutered male dog. The parenchyma is homogenous and the external margins are smooth. The prostatic urethra appears normal with no evidence of irregularity, invasion, mass effect or calculi.

The left kidney has a normal shape and size (5.4 cm). Overall echogenicity is normal with adequate corticomedullary distinction and a typical 1:3 cortex:medulla ratio. There is no evidence of perinephric inflammation or effusion. There is no evidence of pyelectasia, nephroliths, infarcts or hydroureter. Renal vasculature is normal.

The right kidney has a normal shape and size (6.31 cm). Overall echogenicity is normal with adequate corticomedullary distinction and a typical 1:3 cortex:medulla ratio. There is no evidence of perinephric inflammation or effusion. There is no evidence of pyelectasia, nephroliths, infarcts or hydroureter. Renal vasculature is normal.

Adrenal Glands

The left adrenal gland is normal in size measuring 0.43 cm at the caudal pole. It is observed in its normal position cranial to the left renal artery. It is normal in appearance (uniformly hypoechoic) and shape with no evidence of a mass effect.

The right adrenal gland is large in size measuring 1.6 cm at the cranial pole, 2.3 cm at the caudal pole, and 4.91 cm in length. It is observed in its normal position between the cranial aspect of the right kidney and the vena cava. It is abnormal in appearance in that it is very large and somewhat ovoid in shape with a heterogeneous parenchyma. It appears to be compressing the vena cava, but no direct invasion is visualized. Findings are most consistent with a large right adrenal mass.

Spleen

The spleen is subjectively normal in size, echotexture is homogenous, and the splenic capsule is smooth with no irregularities. The blood flow through the hilus and splenic parenchyma appears normal. No focal parenchymal abnormalities are visualized.

Liver

The liver is large in size, and normal in echogenicity with smooth peripheral margins. The parenchyma is heterogenous in echotexture with subtle, indistinct focal mottling. The visible portions of the vasculature and biliary tract appear normal. There are occasional ill-defined, hypoechoic large nodules visualized. On the right side, there is a nodule measuring 2.16 cm x 3.7 cm. On the left side, there is a nodule measuring 1.43 cm x 3.11 cm.

SonoPath
Clinical Sonography & Telecytology
EDUCATIONAL TELECONSULTATION SERVICES™
1-800-838-4268 info@sonopath.com SonoPath.com

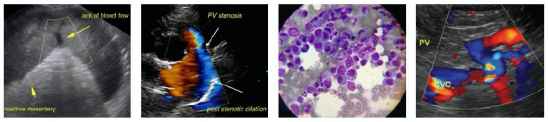

IMAGING PERFORMED BY
pawsonography@gmail.com 530-786-8340

PATIENT

Auggie Phelps

SPECIES

Canine

BREED

Scottish Terrier

SEX

Neutered Male

AGE

12 Years

WEIGHT

25 Pounds

INTERPRETED BY

Kathleen Sennello DVM, MS, Diplomate ACVIM (Small Animal Internal Medicine)

IMAGING BY

Loetitia Saint-Jacques, LVT

HOSPITAL NAME

North Hills VC

REFERRING VET

Dr. David Baggett

INVOICE

35501

DATE

2/8/22

The gall bladder lumen is significantly distended. Some areas of the wall appear mildly thickened with adherent debris. There is a large amount of primarily non-organized echogenic debris. There is no evidence of bile duct dilation. These changes can be consistent with an early gall bladder mucocele.

Gastrointestinal

The stomach contains minimal luminal contents. It measures at a normal thickness of <0.7cm with some variability due to the presence of rugal folds. The distinction of the gastric wall layers is adequate and there is no impression of reduced peristaltic activity. No masses or focal lesions were observed.

The visualized areas of duodenum, jejunum and ileum have a relatively uniform diameter with minimal fluid distension. Wall thickness is normal. Bowel loops follow a curvilinear path with distinct wall layering maintaining the typical 1:3 muscularis:mucosa layer ratio. The duodenum measured as normal (between 0.3-0.5cm in wall thickness) and the jejunum measured as normal (between 0.2-0.47cm.) Visualized peristalsis appears appropriate. There were no focal lesions consistent with obstruction or a mass effect observed.

The ileocecal junction was visualized and exhibited normal intact wall layering and is subjectively of normal thickness. Sections of colon are visualized with formed fecal material and gas shadowing distally. There is no observed focal or generalized colon wall thickening or loss of layering.

Pancreas

The pancreas is normal and isoechoic to surrounding mesentery. There is no evidence of nodules or cystic lesions. There is no evidence of regional mesenteric inflammation or fluid.

Free Abdomen

Evaluation of the peritoneal cavity did not reveal any evidence of effusion, or subjective lymphadenomegaly. The Medial iliac nodes appear normal and there was no evidence of a caudal aortic thrombus at the bifurcation. The omentum is of normal uniform echogenicity.

Other

A brief view of the heart was submitted. No significant pericardial effusion was seen.

ULTRASONOGRAPHIC FINDINGS

- Large, heterogeneous liver with hypoechoic nodules – The diffuse hepatic changes are non-specific and could be consistent with vacuolar hepatopathy, nodular hyperplasia, inflammatory/immune-mediated disease, fibrosis, extramedullary hematopoiesis, toxic hepatopathy (e.g., copper), infiltrative neoplasia (less likely) or other hepatopathy. The focal nodules could represent benign process or a neoplastic process.

- Large, mixed echogenicity right-sided adrenal mass –Right adrenomegaly could be consistent with neoplasia (e.g., adenoma, carcinoma, pheochromocytoma), hyperplasia, inflammation, other.

- Distended gallbladder with large amount of gallbladder debris and early organization of this debris – The significance of the aggregated gallbladder sludge is unclear. This could represent an early mucocele, cholestasis, or may be secondary to fasting.

SonoPath
Clinical Sonography & Telecytology
EDUCATIONAL TELECONSULTATION SERVICES™
1-800-838-4268 info@sonopath.com SonoPath.com

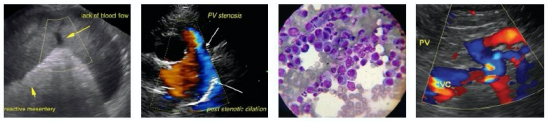

IMAGING PERFORMED BY
pawsonography@gmail.com 530-786-8340

PATIENT

Auggie Phelps

SPECIES

Canine

BREED

Scottish Terrier

SEX

Neutered Male

AGE

12 Years

WEIGHT

25 Pounds

INTERPRETED BY

Kathleen Sennello DVM, MS, Diplomate ACVIM (Small Animal Internal Medicine)

IMAGING BY

Loetitia Saint-Jacques, LVT

HOSPITAL NAME

North Hills VC

REFERRING VET

Dr. David Baggett

INVOICE

35501

DATE

2/8/22

INTERPRETATION OF THE FINDINGS & FURTHER RECOMMENDATIONS

There is mass present involving the right adrenal gland. This mass is irregular and relatively large. I do not see evidence of clear vascular invasion, but this is still possible. These masses can be benign or malignant and can secrete hormones or be non-active. Based on the irregular appearance of this mass a cancerous process is considered more likely. Options moving forward include:

- If signs of cushings are present, consider adrenal function testing. I prefer an ACTH stimulation test combined with an adrenal panel to the University of Tennessee's endocrine lab to look for atypical adrenal hormones as well as cortisol. (other testing can suffice)
- If adrenal dependent cushings is suspected and supported by adrenal function testing consider medical therapy with lysodren or trilostane and/or consider surgical removal (recommend referral to a board certified veterinary surgeon and possible pre op CT)-This can be a challenging surgery with significant risk for complication
- Recommend blood pressure evaluation-if hypertensive consider testing catecholamine levels for a possible pheochromocytoma
- Due to the invasive nature of these masses a CT scan is recommended to evaluate for metastasis and vascular invasion.
- If no symptoms of cushings are present, consider either referral for surgery or if surgery is not an option consultation with a veterinary oncologist regarding chemotherapeutic options and continued monitoring with ultrasound (in 4-6 weeks) can be considered.
- Some aggressive adrenal tumors can grow quickly and there is risk for acute hemorrhage from vascular invasion.

The liver is somewhat heterogeneous with some ill-defined nodules. This could represent a steroid hepatopathy, and could (less likely) represent metastatic disease. A fine needle aspirate of the nodules is recommended (and I believe this has already been performed).

The gallbladder is large and distended with a large amount of debris. An emerging mucocele is likely. Recommend therapy with Ursodiol +/- antibiotics and close monitoring of the gallbladder.

Recommend 3-view thoracic radiographs.

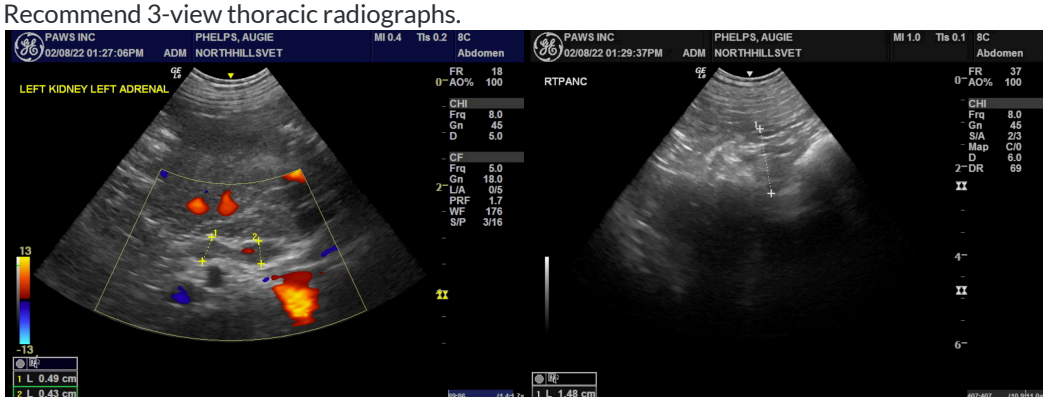

SonoPath
Clinical Sonography & Telecytology

EDUCATIONAL TELECONSULTATION SERVICES™
1-800-838-4268 info@sonopath.com SonoPath.com

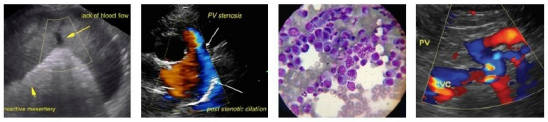

Portable Animal Western Sonography, Inc.

IMAGING PERFORMED BY
pawsonography@gmail.com 530-786-8340

PATIENT

Auggie Phelps

SPECIES

Canine

BREED

Scottish Terrier

SEX

Neutered Male

AGE

12 Years

WEIGHT

25 Pounds

INTERPRETED BY

Kathleen Sennello DVM, MS, Diplomate ACVIM (Small Animal Internal Medicine)

IMAGING BY

Loetitia Saint-Jacques, LVT

HOSPITAL NAME

North Hills VC

REFERRING VET

Dr. David Baggett

INVOICE

35501

DATE

2/8/22

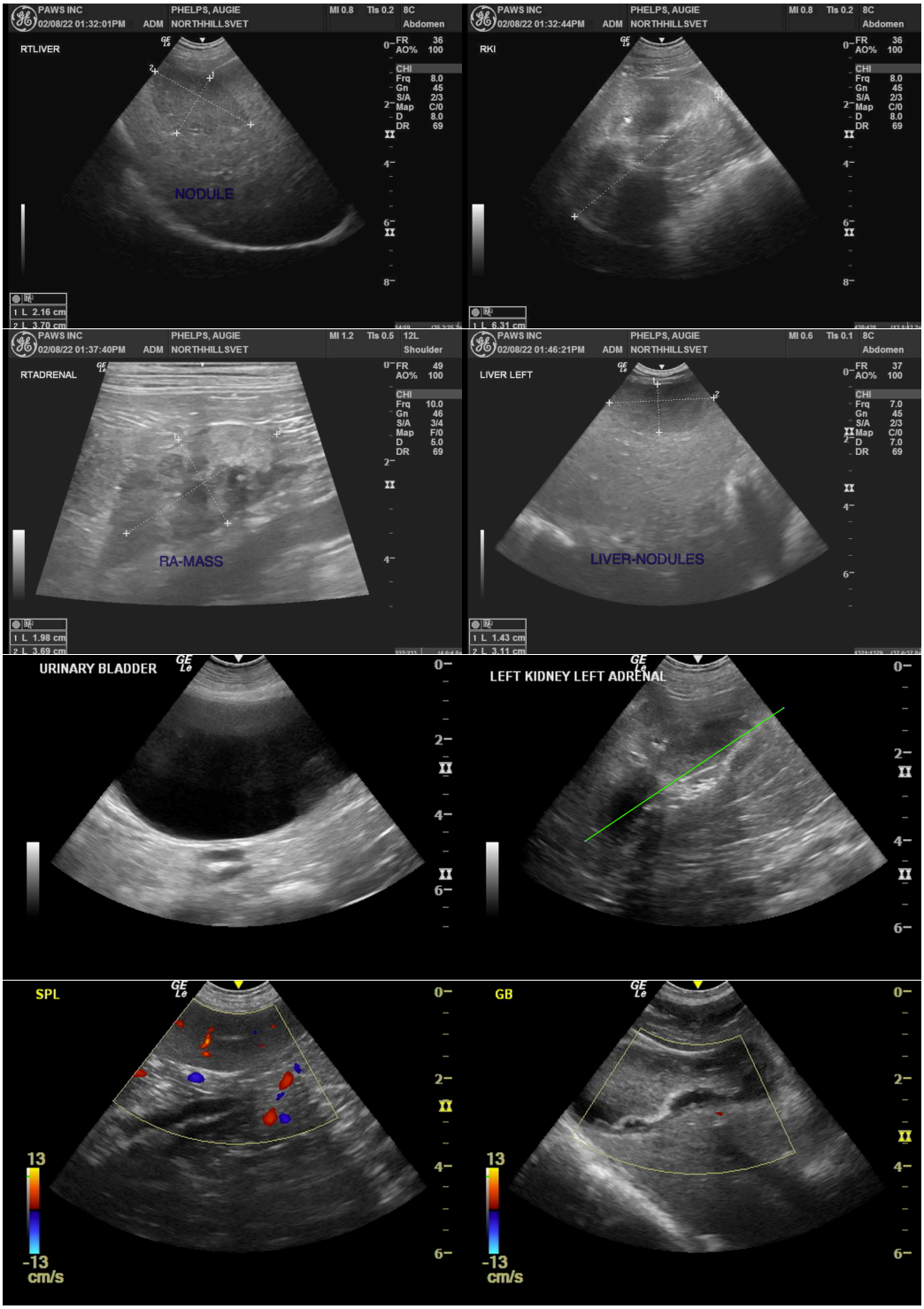

SonoPath
Clinical Sonography & Telecytology
EDUCATIONAL TELECONSULTATION SERVICES™
1-800-838-4268 info@sonopath.com SonoPath.com

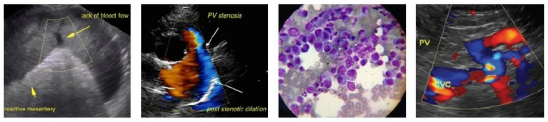

IMAGING PERFORMED BY
pawsonography@gmail.com 530-786-8340

PATIENT

Auggie Phelps

SPECIES

Canine

BREED

Scottish Terrier

SEX

Neutered Male

AGE

12 Years

WEIGHT

25 Pounds

INTERPRETED BY

Kathleen Sennello DVM, MS, Diplomate ACVIM (Small Animal Internal Medicine)

IMAGING BY

Loetitia Saint-Jacques, LVT

HOSPITAL NAME

North Hills VC

REFERRING VET

Dr. David Baggett

INVOICE

35501

DATE

2/8/22

The information and recommendations provided are based on the images presented by the referring veterinarian/sonographer. No evaluation can be communicated regarding pathology that was not visible in the image/video clips provided.

Thank you for this referral. If the clinical or image interpretation does not parallel your findings or if I can be of any further assistance please contact me.

Kathleen Sennello DVM,MS, Diplomate ACVIM (Small animal Internal Medicine)
kathleen.sennello@sonopath.com