



**PATIENT**

Mishka Mendes

**SPECIES**

Feline

**BREED**

DSH

**SEX**

Spayed Female

**AGE**

5

**WEIGHT**

N/A

**INTERPRETED BY**

Kathleen Sennello DVM,  
MS, Diplomate ACVIM  
(Small Animal Internal  
Medicine)

**IMAGING  
PERFORMED BY**

Diane McFadden

**HOSPITAL NAME**

Newton Vet Hospital

**REFERRING VET**

Dr.

**INVOICE**

44805

**DATE**

2/7/23

**PRESENTING CLINICAL SIGNS**

Vomiting, not eating, abnormal FPL; cerenia given  
Abnormal PE/Chem/CBC/UA Results: glob 6.1

**ULTRASONOGRAPHIC EXAMINATION OF THE ABDOMEN**

**Urinary System**

The urinary bladder is moderately distended with anechoic urine. The Bladder wall, trigone, ureteral papillae and visible urethra (to a depth of 2cm) appear normal with no evidence of wall thickening, mucosal irregularities, masses or cystic calculi.

The left kidney has a normal shape and size (3.96 cm). Overall echogenicity is normal with adequate corticomedullary distinction and a typical 1:3 cortex:medulla ratio. There is no evidence of focal perinephric inflammation or effusion. There is no evidence of pyelectasia, nephroliths, infarcts or hydroureter. Renal vasculature is normal.

The right kidney has a normal shape and size (4.06 cm). Overall echogenicity is normal with adequate corticomedullary distinction and a typical 1:3 cortex:medulla ratio. There is no evidence of focal perinephric inflammation or effusion. There is no evidence of pyelectasia, nephroliths, infarcts or hydroureter. Renal vasculature is normal.

**Adrenal Glands**

The left adrenal gland is normal in size measuring 0.42 cm at the caudal pole. It is observed in its normal position cranial to the left renal artery. It is normal in appearance (uniformly hypoechoic) and shape with no evidence of a mass effect.

The right adrenal gland is normal in size measuring 0.35 cm at the caudal pole. It is observed in its normal position between the cranial aspect of the right kidney and the caudal vena cava. It is normal in appearance (uniformly hypoechoic) and shape with no evidence of a mass effect.

**Spleen**

The spleen is subjectively normal in size (0.92 cm in width), echotexture is homogenous, and the splenic capsule is smooth with no irregularities. The blood flow through the hilus and splenic parenchyma appears normal. No focal parenchymal abnormalities are visualized.

**Liver**

The liver is subjectively normal in size, and echogenicity with smooth peripheral margins. The parenchyma is homogenous echotexture. The visible portions of the vasculature and biliary tract appear normal. No focal nodules or cystic lesions are observed.

The gallbladder lumen is moderately distended. The wall of the gall bladder is not thickened and has a smooth mucosal surface. Luminal contents are mild and primarily anechoic. The cystic and common bile ducts are normal/not visible.

**Gastrointestinal**

The stomach contains minimal luminal contents. It measures at a normal thickness of <0.36cm with some variability due to the presence of rugal folds. The distinction of the gastric wall layers is adequate and there is no impression of reduced peristaltic activity. No masses or focal lesions were observed.

The visualized areas of duodenum, jejunum and ileum have a relatively uniform diameter with minimal fluid distension. Wall thickness is normal. Bowel loops follow a curvilinear path with distinct wall



**PATIENT**

Mishka Mendes

layering maintaining the typical 1:3 muscularis:mucosa layer ratio. Jejunum wall measures 0.20 cm. Visualized peristalsis appears appropriate. There were no focal lesions consistent with obstruction or a mass effect observed.

**SPECIES**

Feline

The ileocecal junction was visualized and exhibited normal intact wall layering and is subjectively of normal thickness. Sections of colon are visualized with formed fecal material and gas shadowing distally. There is no observed focal or generalized colon wall thickening or loss of layering.

**BREED**

***Pancreas***

DSH

The pancreas is normal and isoechoic to surrounding mesentery. There is no evidence of nodules or cystic lesions. There is no evidence of regional mesenteric inflammation or fluid.

**SEX**

***Free Abdomen***

Spayed Female

Evaluation of the peritoneal cavity did not reveal any evidence of effusion, or subjective lymphadenomegaly. The Medial iliac nodes appear normal and there was no evidence of a caudal aortic thrombus at the bifurcation. The omentum is of normal uniform echogenicity.

**AGE**

5

**ULTRASONOGRAPHIC FINDINGS**

**WEIGHT**

- No significant lesions visualized on today's exam

N/A

**INTERPRETATION OF THE FINDINGS & FURTHER RECOMMENDATIONS**

**INTERPRETED BY**

Kathleen Sennello DVM,  
MS, Diplomate ACVIM  
(Small Animal Internal  
Medicine)

No focal lesions are visualized associated with the gastrointestinal tract to explain the vomiting and anorexia reported. Unfortunately, not all causes of vomiting can be definitively diagnosed with ultrasound alone. If this is an acute condition, consider the possibility of ingested foreign material (not all foreign material can readily be visualized with ultrasound), pancreatic disease, food allergy/dietary intolerance, GI parasitism, non-specific acute gastroenteritis, and metabolic disease.

**IMAGING PERFORMED BY**

Diane McFadden

- Correlate findings with abdominal radiographs. If there is any concern for ingested foreign material, consider serial radiographs and close monitoring.
- Consider a novel protein/hydrolyzed protein diet (exclusively at least 4-6 weeks)
- Consider a GI panel to Texas A&M for evaluation of B12 levels, folate, PLI/TLI etc.. to further evaluate for pancreatic/small intestinal disease.
- Recommend chronic probiotic therapy.
- If symptoms persist and there is no evidence of metabolic disease, then further evaluation of the GI tract with biopsies may need to be considered.

**HOSPITAL NAME**

Newton Vet Hospital

**REFERRING VET**

Dr.

**INVOICE**

44805

**DATE**

2/7/23



**PATIENT**

Mishka Mendes

**SPECIES**

Feline

**BREED**

DSH

**SEX**

Spayed Female

**AGE**

5

**WEIGHT**

N/A

**INTERPRETED BY**

Kathleen Sennello DVM,  
MS, Diplomate ACVIM  
(Small Animal Internal  
Medicine)

**IMAGING  
PERFORMED BY**

Diane McFadden

**HOSPITAL NAME**

Newton Vet Hospital

**REFERRING VET**

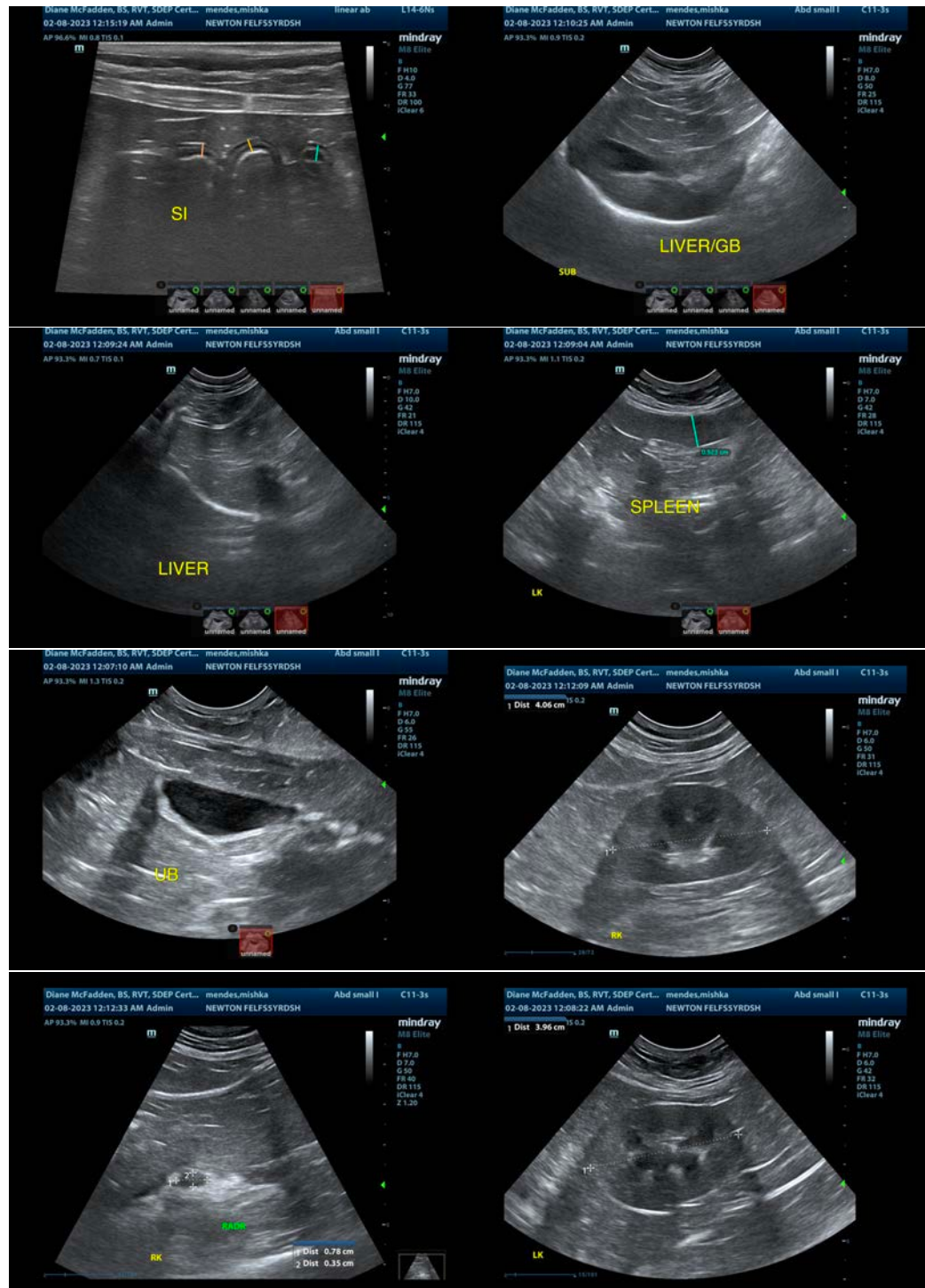
Dr.

**INVOICE**

44805

**DATE**

2/7/23





**PATIENT**

Mishka Mendes

**SPECIES**

Feline

**BREED**

DSH

**SEX**

Spayed Female

**AGE**

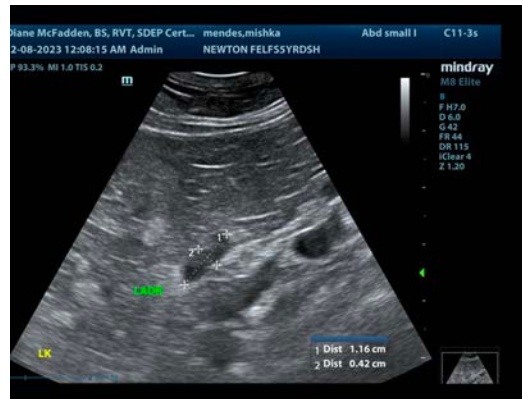
5

**WEIGHT**

N/A

**INTERPRETED BY**

Kathleen Sennello DVM,  
MS, Diplomate ACVIM  
(Small Animal Internal  
Medicine)



The information and recommendations provided are based on the images presented by the referring veterinarian/sonographer. No evaluation can be communicated regarding pathology that was not visible in the image/video clips provided.

Thank you for this referral. If the clinical or image interpretation does not parallel your findings or if I can be of any further assistance please contact me.

Kathleen Sennello DVM,MS, Diplomate ACVIM (Small animal Internal Medicine)

kathleen.sennello@sonopath.com

**IMAGING PERFORMED BY**

Diane McFadden

**HOSPITAL NAME**

Newton Vet Hospital

**REFERRING VET**

Dr.

**INVOICE**

44805

**DATE**

2/7/23