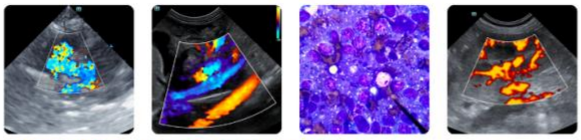

DATE

2/6/26

PATIENT

Dora McSherry

SPECIES

Feline

BREED

DSH

SEX

Spayed Female

AGE

4/12/2008

WEIGHT

12 Pounds

INTERPRETED BY

Kathleen Sennello DVM, MS, Diplomate ACVIM (Small animal Internal Medicine)

HOSPITAL NAME

Cat Sense Feline AH

REFERRING VET

Dr. Sinclair

INVOICE

35717

PRESENTING CLINICAL SIGNS

Patient History: Dora presented for increased thirst and urination. She had lost 1# since July. She was too tense to palpate anything in her abdomen. Her bloodwork showed a minor increase in her renal values. Her BG was a little elevated but she did not have any glucosuria. Bloodwork shows a neutrophilia and a monocytosis. She has proteinuria with a UPC of 0.78.

Current Medications: Prednisolone 5mg eod except she hasn't gotten it for the past 2-3 weeks (owner forgot) until she had a dose Wednesday famciclovir 125mg bid and chlorpheniramine 2mg bid for herpes flare
chlorpheniramine 2mg bid
Labwork Results: Labwork attached, reported as WBC=22,800, neutrophils=20,018, monocytes=1,072, BG=223, BUN=43, creat=2.2, UPC=0.78
Date of Previous IntraPet Ultrasound: 3/14/25. See attached.
Sedation: Not required to complete full diagnostic ultrasound.
Stat Report: Not requested.
Imaging Performed by: Stephanie Warga RDCS RVT.

ULTRASONOGRAPHIC EXAMINATION OF THE ABDOMEN

Urinary System

The urinary bladder is moderately distended with mild primarily suspended echogenic debris present. The bladder wall, trigone, ureteral papillae and visible urethra (to a depth of 2.0 cm) appear normal with no evidence of wall thickening, mucosal irregularities, masses or calculi. Echogenic debris of this type can be associated with small crystals, cellular debris and proteinaceous debris.

The left kidney has a normal shape and normal to borderline small in size (3.42 cm). Overall echogenicity is slightly hyperechoic with decreased corticomedullary distinction and a typical 1:3 cortex:medulla ratio. There is no evidence of focal perinephric inflammation or effusion. There is no evidence of pyelectasia, nephroliths, infarcts or hydroureter. Renal vasculature is normal.

The right kidney is normal in shape and size (3.76 cm). Overall echogenicity is slightly hyperechoic with decreased corticomedullary distinction and a typical 1:3 cortex:medulla ratio. There is no evidence of focal perinephric inflammation or effusion. There is no evidence of pyelectasia, nephroliths, infarcts or hydroureter. Renal vasculature is normal.

Adrenal Glands

The left adrenal gland is normal in size measuring 0.35 cm at the caudal pole. It is observed in its normal position cranial to the left renal artery. It is normal in appearance (uniformly hypoechoic) and shape with no evidence of a mass effect.

The right adrenal gland is normal in size measuring 0.36 cm at the caudal pole. It is observed in its normal position between the cranial aspect of the right kidney and the caudal vena cava. It is normal in appearance (uniformly hypoechoic) and shape with no evidence of a mass effect.

Spleen

The spleen is subjectively normal in size, echotexture is homogenous, and the splenic capsule is smooth with no irregularities. The blood flow through the hilus and splenic parenchyma appears normal. No focal parenchymal abnormalities are visualized.

Liver

The liver is subjectively normal in size, and echogenicity with smooth peripheral margins. The parenchyma is homogenous echotexture. The visible portions of the vasculature and biliary tract appear normal. No focal nodules or cystic lesions are observed. The gall bladder lumen is moderately distended. The wall of the gall bladder is not thickened and has a smooth mucosal surface. Luminal contents are primarily anechoic. The cystic and common bile ducts are normal/not visible.

Gastrointestinal

The stomach contains minimal luminal contents. It measures at a normal thickness of <0.7 cm with some variability due to the presence of rugal folds. The distinction of the gastric wall layers is adequate and there is no impression of reduced peristaltic activity. No masses or focal lesions were observed.

The visualized areas of duodenum, jejunum and ileum have a uniform diameter with minimal fluid and gas distension. Wall thickness is normal to slightly increased. Bowel loops follow a typical curvilinear path with distinct wall layering, but some areas display a prominent muscularis layer which does not display the typical 1:3 muscularis:mucosa layer ratio. The jejunum measured 0.17 cm in diameter. Visualized peristalsis appears appropriate. There were no focal lesions consistent with obstruction or a mass effect observed.

Sections of colon are visualized with formed fecal material and gas shadowing distally. There is no observed focal or generalized colon wall thickening or loss of layering.

Pancreas

The pancreas is prominent, hypoechoic, irregular and mottled in both limbs compared to the surrounding isoechoic mesentery. There is a large hypoechoic irregular nodule visualized in the caudal aspect of the left limb of the pancreas, measuring 1.0 cm, and another smaller nodule visualized, measuring 0.32 cm (previous measurement 3/25 the nodule measured 1.2 cm). There is no evidence of regional mesenteric inflammation or fluid. The pancreatic duct is prominent, measuring 0.38 cm.

Free Abdomen

Evaluation of the peritoneal cavity did not reveal any evidence of effusion, or subjective lymphadenomegaly. The medial iliac nodes appear normal and there was no evidence of a caudal aortic thrombus at the bifurcation. The omentum is of normal uniform echogenicity.

ULTRASONOGRAPHIC FINDINGS

Primary Findings

- Decreased corticomedullary distinction in both kidneys- Mild loss of corticomedullary distinction in both kidneys could be consistent with chronic degenerative disease or interstitial nephrosis.

- Prominent hypoechoic mottled pancreas with stable hypoechoic nodules visualized in the left limb- Findings are most consistent with chronic pancreatic remodeling, +/- chronic pancreatitis,

and nodular hyperplasia. A neoplastic process seems less likely based on the stability of these changes.

- Prominent somewhat ropey small intestine with some areas exhibiting a prominent muscularis layer- The small intestinal wall changes are most consistent with an inflammatory process (i.e., inflammatory bowel disease) with a low possibility of emerging lymphoma

Secondary Findings

- Mild suspended echogenic debris in the urinary bladder- The echogenic debris in the bladder lumen could be consistent with cells, crystals, and/or mucus. Recommend urinalysis and culture.

INTERPRETATION OF THE FINDINGS & FURTHER RECOMMENDATIONS

The findings on today's scan are very similar to those reported 3/14/2025. The pancreatic changes appear stable and there are no appreciable changes in the appearance of the kidneys, although you can have a loss of progressive function regardless. Consider a fructosamine to rule out intermittent hyperglycemia and a blood pressure if this has not been recently evaluated. A urine culture could also be considered based on the progression of the renal values and the mild debris visualized within the urinary bladder.

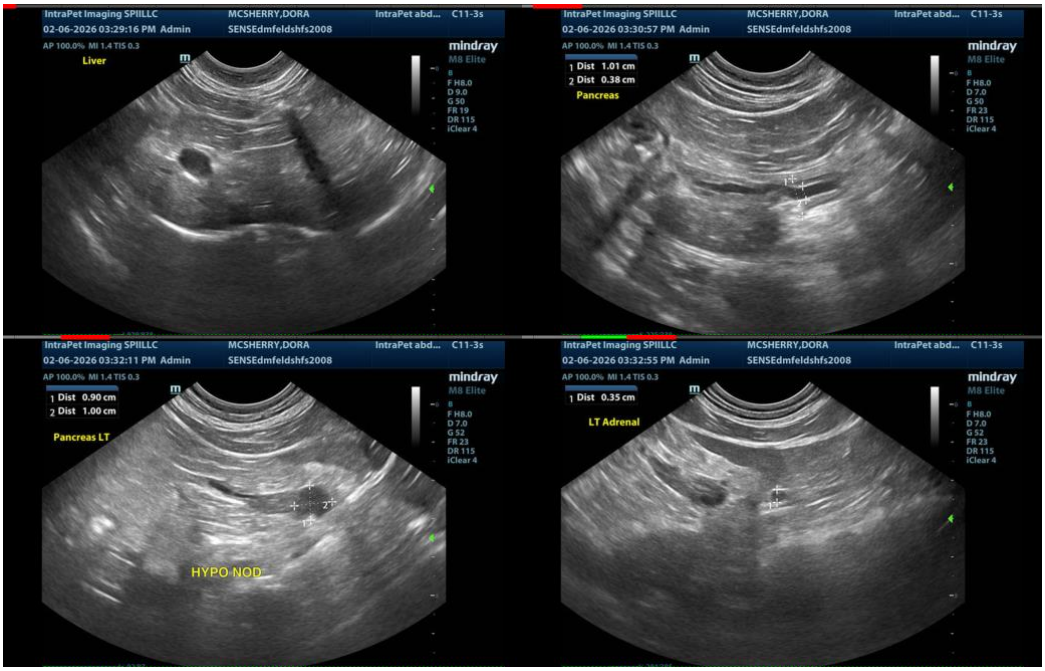

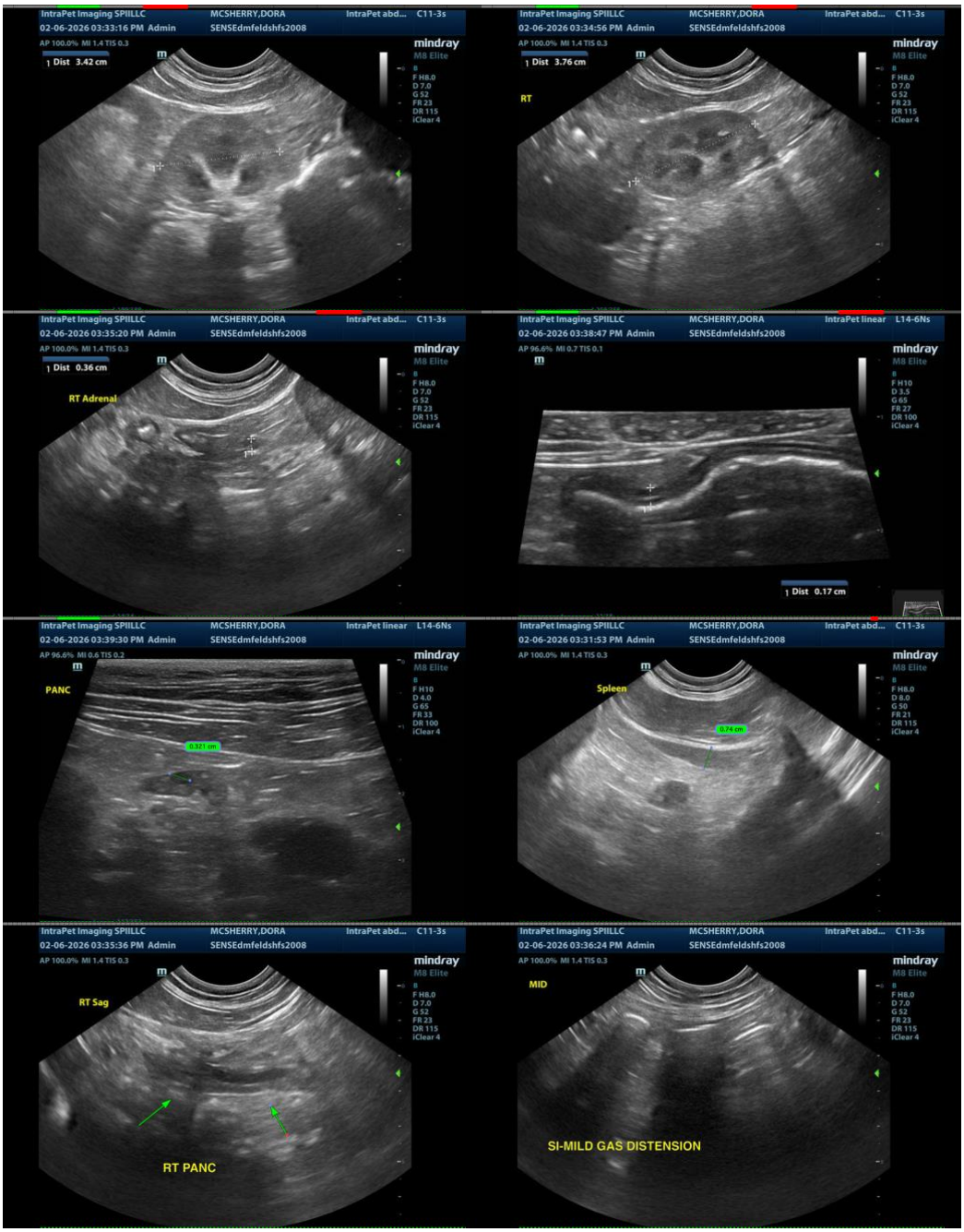

The information and recommendations provided are based on the images presented by the referring veterinarian/sonographer. No evaluation can be communicated regarding pathology that was not visible in the image/video clips provided.

Thank you for this referral. If the clinical or image interpretation does not parallel your findings or if I can

be of any further assistance, please contact me.

Kathleen Sennello DVM, MS, Diplomate ACVIM (Small animal Internal Medicine)

info@sonopath.com