



PATIENT

Harry Zaccor

SPECIES

Canine

BREED

Lagotto Romagnolo

SEX

Neutered Male

AGE

8 Years

WEIGHT

48 lbs

INTERPRETED BY

Kathleen Sennello DVM,
MS, Diplomate ACVIM
(Small Animal Internal
Medicine)

IMAGING PERFORMED BY

Dr. Casper

HOSPITAL NAME

Hometown Animal
Hospital (Florida)

REFERRING VET

Dr. Casper

INVOICE

72739

DATE

2/5/26

PRESENTING CLINICAL SIGNS

Recent worsening of separation anxiety. Otherwise no concerns. AUS recheck scheduled based on wellness bloodwork results

Abnormal PE/Chem/CBC/UA Results: Hx of adrenomegaly and adrenomegaly on prev AUS in 2024. (report attached) Overweight, separation anxiety. Jan16 bloodwork: Cbc - WNL. Chem- inc TP (7.6), inc ALT (266), AST (61), ALP (1514), inc chol (392), UPC 0.5

ULTRASONOGRAPHIC EXAMINATION OF THE ABDOMEN

Urinary System

The urinary bladder is moderately distended with anechoic urine. The Bladder wall, trigone, ureteral papillae and visible urethra (to a depth of 2cm) appear normal with no evidence of wall thickening, mucosal irregularities, masses or cystic calculi.

The visualized areas of prostate and surrounding tissue appear normal. Unfortunately, the prostate is not fully visualized likely due to its intrapelvic location. Correlate with rectal exam findings.

The left kidney has a normal shape and size (5.8 cm). Overall echogenicity is normal with adequate corticomedullary distinction and a typical 1:3 cortex:medulla ratio. There is no evidence of focal perinephric inflammation or effusion. There is no evidence of pyelectasia, nephroliths, infarcts or hydroureter. Renal vasculature is normal.

The right kidney has a normal shape and size (4.47 cm). Overall echogenicity is normal with adequate corticomedullary distinction and a typical 1:3 cortex:medulla ratio. There is no evidence of focal perinephric inflammation or effusion. There is no evidence of pyelectasia, nephroliths, infarcts or hydroureter. Renal vasculature is normal.

Adrenal Glands

The left adrenal gland is normal in size measuring 0.60 cm at the cranial pole and 0.54 cm at the caudal pole (previous measurement 12/2024 was 0.60 cm at the caudal pole). It is observed in its normal position cranial to the left renal artery. It is normal in appearance (uniformly hypoechoic) and shape with no evidence of a mass effect.

The right adrenal gland is normal in size measuring 0.62 cm at the cranial pole and 0.57 cm at the caudal pole (previous measurement 12/2024 was 0.64 cm at the caudal pole). It is observed in its normal position between the cranial aspect of the right kidney and the caudal vena cava. It is normal in appearance (uniformly hypoechoic) and shape with no evidence of a mass effect.

Spleen

The spleen is subjectively normal in size (1.53 cm in width at the level of the hilus), echotexture is homogenous, and the splenic capsule is smooth with no irregularities. The blood flow through the hilus and splenic parenchyma appears normal. There is a poorly defined hypoechoic nodule in the body measuring 1.09 cm in diameter (previous measurement 12/2024 was 0.93 cm x 0.69 cm).



PATIENT

Harry Zaccor

SPECIES

Canine

BREED

Lagotto Romagnolo

SEX

Neutered Male

AGE

8 Years

WEIGHT

48 lbs

INTERPRETED BY

Kathleen Sennello DVM,
MS, Diplomate ACVIM
(Small Animal Internal
Medicine)

IMAGING PERFORMED BY

Dr. Casper

HOSPITAL NAME

Hometown Animal
Hospital (Florida)

REFERRING VET

Dr. Casper

INVOICE

72739

DATE

2/5/26

Liver

The liver is large in size with smooth peripheral margins. The parenchyma is mildly hyperechoic and homogenous in echotexture. The visible portions of the vasculature and biliary tract appear normal. No focal nodules or cystic lesions are observed.

The gall bladder lumen is moderately distended. The wall of the gall bladder is not thickened and has a smooth mucosal surface. There is a moderate amount of non-organized echogenic debris. The cystic and common bile ducts are normal/not visible.

Gastrointestinal

The stomach contains minimal luminal contents. It measures at a normal thickness of <0.7cm with some variability due to the presence of rugal folds. The distinction of the gastric wall layers is adequate and there is no impression of reduced peristaltic activity. No masses or focal lesions were observed.

The visualized areas of duodenum, jejunum and ileum have a relatively uniform diameter with minimal fluid distension. Wall thickness is normal. Bowel loops follow a curvilinear path with distinct wall layering maintaining the typical 1:3 muscularis:mucosa layer ratio. Duodenum wall measures 0.40 cm. Jejunum wall measures 0.39 cm. Visualized peristalsis appears appropriate. There were no focal lesions consistent with obstruction or a mass effect observed.

Sections of colon are visualized with formed fecal material and gas shadowing distally. There is no observed focal or generalized colon wall thickening or loss of layering.

Pancreas

The pancreas is normal and isoechoic to surrounding mesentery. There is no evidence of nodules or cystic lesions. There is no evidence of regional mesenteric inflammation or fluid.

Free Abdomen

Evaluation of the peritoneal cavity did not reveal any evidence of effusion, or subjective lymphadenomegaly. The Medial iliac nodes appear normal and there was no evidence of a caudal aortic thrombus at the bifurcation. The omentum is of normal uniform echogenicity.

ULTRASONOGRAPHIC FINDINGS

- Large, hyperechoic liver – The diffuse hepatic changes are non-specific and can be seen with vacuolar hepatopathy, reactive change, nodular hyperplasia or, less likely, inflammatory/immune-mediated disease, infiltrative neoplasia, or other hepatopathy.
- Hypoechoic nodule in the spleen – There is a non-cavitated, hypoechoic splenic nodule visualized. Differentials include lymphoid hyperplasia, extramedullary hematopoiesis, infiltrative neoplasia, inflammation, other. Cytology or histopathology would be necessary to get a definitive diagnosis.
- Moderate gallbladder debris – The significance of the aggregated gallbladder debris is unclear. This could represent an early mucocele, cholestasis, or may be secondary to fasting but seems unlikely to be causing a current issue. Recommend continued monitoring.



PATIENT

Harry Zaccor

SPECIES

Canine

BREED

Lagotto Romagnolo

SEX

Neutered Male

AGE

8 Years

WEIGHT

48 lbs

INTERPRETED BY

Kathleen Sennello DVM,
MS, Diplomate ACVIM
(Small Animal Internal
Medicine)

IMAGING PERFORMED BY

Dr. Casper

HOSPITAL NAME

Hometown Animal
Hospital (Florida)

REFERRING VET

Dr. Casper

INVOICE

72739

DATE

2/5/26

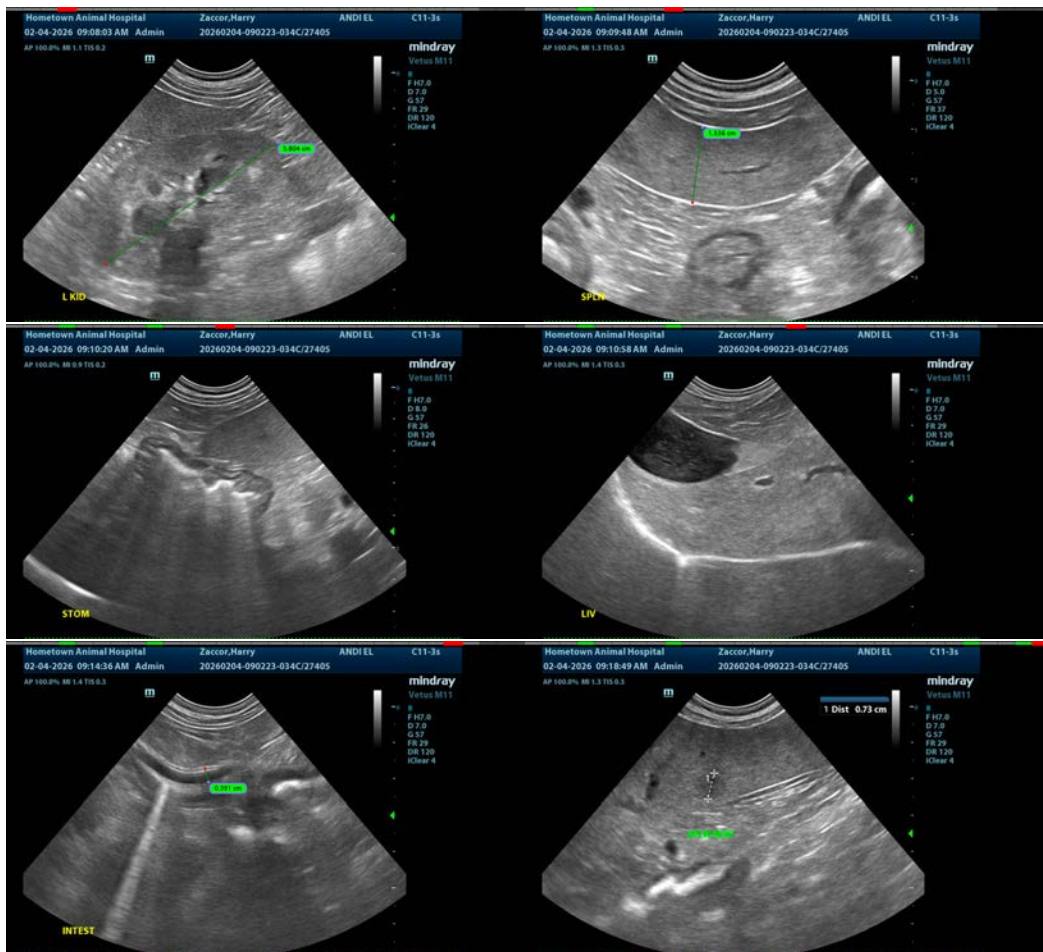
INTERPRETATION OF THE FINDINGS & FURTHER RECOMMENDATIONS

The liver is large and hyperechoic. No focal lesions are observed. These findings are most consistent with a vacuolar hepatopathy, although other hepatopathies are possible.

There is a small, hypoechoic nodule in the spleen. I suspect this is the same nodule previously described, and it appears relatively stable in size, making an aggressive neoplastic lesion less likely.

The adrenals are stable in size and do not appear significantly enlarged.

Findings are suggestive of a primary vacuolar hepatopathy, although Cushing's disease cannot be ruled out. If further evaluation is desired, a liver function test and a fine needle aspirate could be considered.





PATIENT

Harry Zaccor

SPECIES

Canine

BREED

Lagotto Romagnolo

SEX

Neutered Male

AGE

8 Years

WEIGHT

48 lbs

INTERPRETED BY

Kathleen Sennello DVM,
MS, Diplomate ACVIM
(Small Animal Internal
Medicine)

IMAGING PERFORMED BY

Dr. Casper

HOSPITAL NAME

Hometown Animal
Hospital (Florida)

REFERRING VET

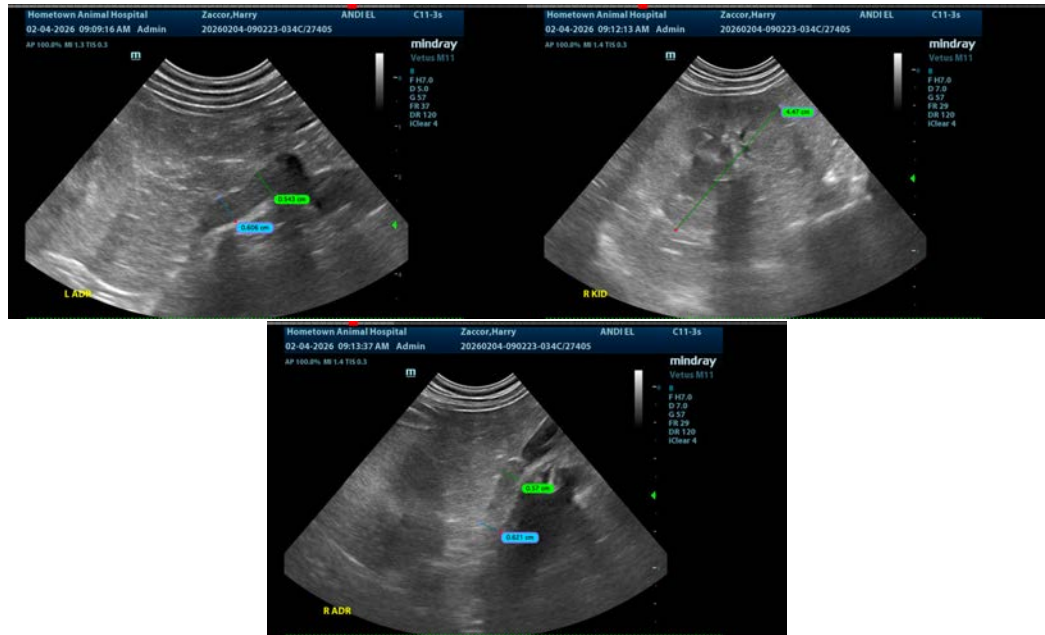
Dr. Casper

INVOICE

72739

DATE

2/5/26



The information and recommendations provided are based on the images presented by the referring veterinarian/sonographer. No evaluation can be communicated regarding pathology that was not visible in the image/video clips provided.

Thank you for this referral. If the clinical or image interpretation does not parallel your findings or if I can be of any further assistance please contact me.

Kathleen Sennello DVM,MS, Diplomate ACVIM (Small animal Internal Medicine)

info@sonopath.com