



PATIENT

Cobie Zook

SPECIES

Canine

BREED

Border Collie

SEX

Neutered Male

AGE

12 Years 8 Months

WEIGHT

54.8 lbs

INTERPRETED BY

Kathleen Sennello DVM,
 MS, Diplomate ACVIM
 (Small Animal Internal
 Medicine)

IMAGING PERFORMED BY

Kathleen Byrnes

HOSPITAL NAME

Stoney Creek
 Veterinary Hospital

REFERRING VET

Dr. Eldred

INVOICE

72745

DATE

2/5/26

PRESENTING CLINICAL SIGNS

P presented as ADR- bloodwork showed low platelets started doxycycline. presented to ER clinic for dyspnea, concern for stomach upset due to doxycycline. Presented to rdvm today for abd US, eating 50-60% of what he normally eats, difficulty breathing when recumbent, occasionally hacks. Has lost about 3# since last visit

ULTRASONOGRAPHIC EXAMINATION OF THE ABDOMEN

Urinary System

The urinary bladder is moderately distended with anechoic urine. The Bladder wall, trigone, ureteral papillae and visible urethra (to a depth of 2cm) appear normal with no evidence of wall thickening, mucosal irregularities, masses or cystic calculi.

The prostate is normal in size (0.89 cm) and shape for this neutered male dog. The parenchyma is homogenous and the external margins are smooth. The prostatic urethra appears normal with no evidence of irregularity, invasion, mass effect or calculi.

The left kidney has a normal shape and size (6.14 cm). Overall echogenicity is normal with adequate corticomedullary distinction and a typical 1:3 cortex:medulla ratio. There is no evidence of focal perinephric inflammation or effusion. There is no evidence of pyelectasia, nephroliths, infarcts or hydroureter. Renal vasculature is normal.

The right kidney has a normal shape and size (4.74 cm). Overall echogenicity is normal with adequate corticomedullary distinction and a typical 1:3 cortex:medulla ratio. There is no evidence of focal perinephric inflammation or effusion. There is no evidence of pyelectasia, nephroliths, infarcts or hydroureter. Renal vasculature is normal.

Adrenal Glands

The left adrenal gland is normal in size measuring 0.40 cm at the cranial pole and 0.40 cm at the caudal pole. It is observed in its normal position cranial to the left renal artery. It is normal in appearance (uniformly hypoechoic) and shape with no evidence of a mass effect.

The right adrenal gland is normal in size measuring 0.43 cm at the cranial pole and 0.42 cm at the caudal pole. It is observed in its normal position between the cranial aspect of the right kidney and the caudal vena cava. It is normal in appearance (uniformly hypoechoic) and shape with no evidence of a mass effect.

Spleen

The spleen is large, measuring 2.63 cm in width at the level of the hilus. The spleen echotexture is heterogenous and mottled, the splenic capsule is smooth with no irregularities. The blood flow through the hilus and splenic parenchyma appears normal. There is a diffuse nodular/reticulated pattern associated with the splenic parenchyma.

Liver

The liver is subjectively normal in size, and echogenicity with rounded margins. The parenchyma is heterogenous in echotexture with subtle, indistinct focal mottling. The visible portions of the



PATIENT

Cobie Zook

SPECIES

Canine

BREED

Border Collie

SEX

Neutered Male

AGE

12 Years 8 Months

WEIGHT

54.8 lbs

INTERPRETED BY

Kathleen Sennello DVM,
 MS, Diplomate ACVIM
 (Small Animal Internal
 Medicine)

IMAGING PERFORMED BY

Kathleen Byrnes

HOSPITAL NAME

Stoney Creek
 Veterinary Hospital

REFERRING VET

Dr. Eldred

INVOICE

72745

DATE

2/5/26

vasculature and biliary tract appear normal. There is a hyperechoic nodule visualized associated with the parenchyma measuring 1.23 cm in diameter.

The gall bladder lumen is moderately distended. The wall of the gall bladder is not thickened and has a smooth mucosal surface. There is a moderate amount of non-organized echogenic debris. The debris is hyperechoic, forming a "sludge ball". The cystic and common bile ducts are normal/not visible.

Gastrointestinal

The stomach contains minimal luminal contents. It measures at a normal thickness of <0.7cm with some variability due to the presence of rugal folds. The distinction of the gastric wall layers is adequate and there is no impression of reduced peristaltic activity. No masses or focal lesions were observed.

The visualized areas of duodenum, jejunum and ileum have a relatively uniform diameter with mild/moderate fluid/gas distension. Wall thickness is normal. Bowel loops follow a curvilinear path with distinct wall layering maintaining the typical 1:3 muscularis:mucosa layer ratio. Duodenum wall measures 0.42 cm. Jejunum wall measures 0.37 cm. Visualized peristalsis appears appropriate. There were no focal lesions consistent with obstruction or a mass effect observed.

Sections of colon are visualized with formed fecal material and gas shadowing distally. There is no observed focal or generalized colon wall thickening or loss of layering.

Pancreas

The area of the pancreas is normal and isoechoic to surrounding mesentery. There is no evidence of nodules or cystic lesions. There is no evidence of regional mesenteric inflammation or fluid.

Free Abdomen

Evaluation of the peritoneal cavity did not reveal any evidence of effusion. There are prominent iliac lymph nodes visualized measuring 1.4 cm and 0.97 cm in width.

ULTRASONOGRAPHIC FINDINGS

- Large, reticulated spleen – Primary differential is round cell neoplasia. Recommend a fine needle aspirate.
- Heterogeneous liver with a hyperechoic nodule – The diffuse hepatic changes are non-specific and could be consistent with vacuolar hepatopathy, nodular hyperplasia, inflammatory/immune-mediated disease, fibrosis, extramedullary hematopoiesis, toxic hepatopathy (e.g., copper), infiltrative neoplasia (less likely) or other hepatopathy. The hyperechoic nodule has the appearance most consistent with a benign lesion. Recommend continued monitoring.
- Moderate gallbladder debris – The significance of the aggregated gallbladder debris is unclear. This could represent an early mucocele, cholestasis, or may be secondary to fasting but seems unlikely to be causing a current issue. Recommend continued monitoring.
- Large, hypoechoic iliac lymph nodes – Findings could be consistent with highly reactive or early metastatic lymph nodes.



PATIENT

Cobie Zook

SPECIES

Canine

BREED

Border Collie

SEX

Neutered Male

AGE

12 Years 8 Months

WEIGHT

54.8 lbs

INTERPRETED BY

Kathleen Sennello DVM,
 MS, Diplomate ACVIM
 (Small Animal Internal
 Medicine)

**IMAGING
 PERFORMED BY**

Kathleen Byrnes

HOSPITAL NAME

Stoney Creek
 Veterinary Hospital

REFERRING VET

Dr. Eldred

INVOICE

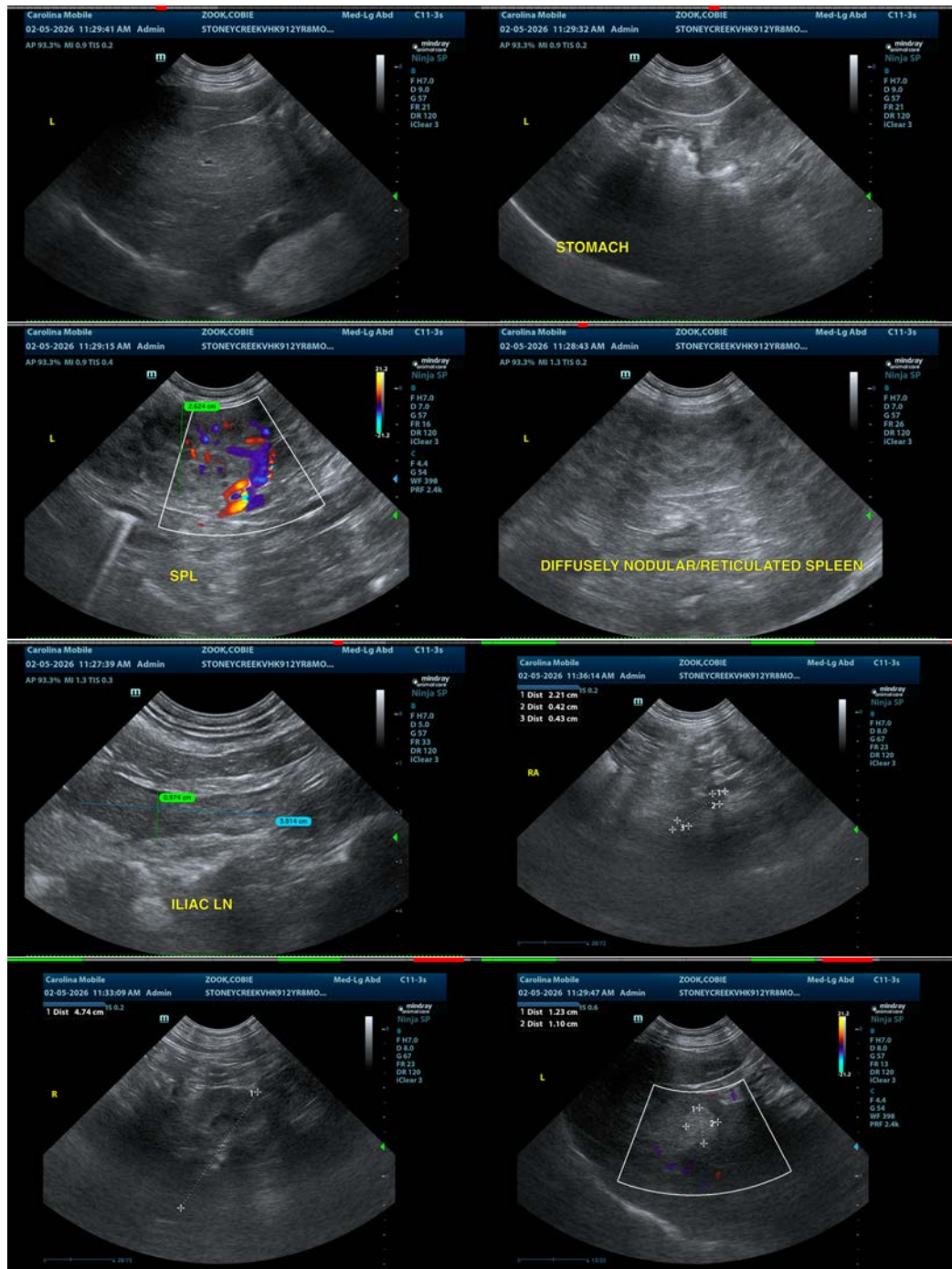
72745

DATE

2/5/26

INTERPRETATION OF THE FINDINGS & FURTHER RECOMMENDATIONS

The appearance of the spleen is highly concerning for an underlying neoplastic process. Round cell neoplasia would be a primary differential. If further evaluation is desired, recommend a fine needle aspirate.





PATIENT

Cobie Zook

SPECIES

Canine

BREED

Border Collie

SEX

Neutered Male

AGE

12 Years 8 Months

WEIGHT

54.8 lbs

INTERPRETED BY

Kathleen Sennello DVM,
 MS, Diplomate ACVIM
 (Small Animal Internal
 Medicine)

IMAGING PERFORMED BY

Kathleen Byrnes

HOSPITAL NAME

Stoney Creek
 Veterinary Hospital

REFERRING VET

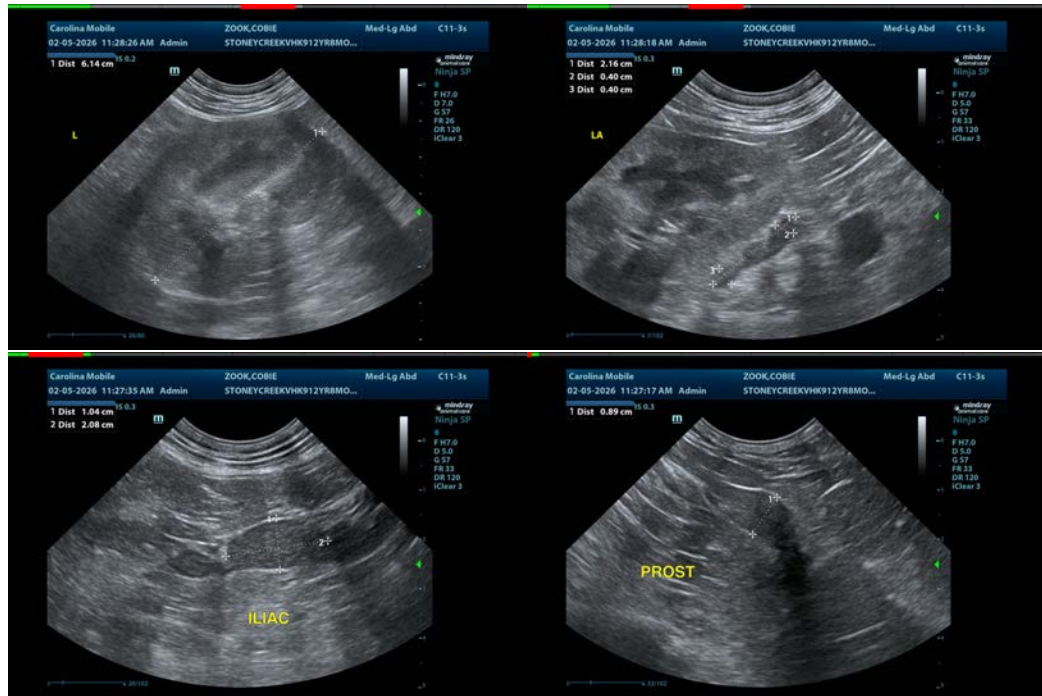
Dr. Eldred

INVOICE

72745

DATE

2/5/26



The information and recommendations provided are based on the images presented by the referring veterinarian/sonographer. No evaluation can be communicated regarding pathology that was not visible in the image/video clips provided.

Thank you for this referral. If the clinical or image interpretation does not parallel your findings or if I can be of any further assistance please contact me.

Kathleen Sennello DVM,MS, Diplomate ACVIM (Small animal Internal Medicine)

info@sonopath.com