



PATIENT

Eleanor Hoffman

SPECIES

Canine

BREED

Havanese

SEX

Spayed Female

AGE

8 Years

WEIGHT

20 lbs

INTERPRETED BY

Kathleen Sennello DVM,
MS, Diplomate ACVIM
(Small Animal Internal
Medicine)

IMAGING PERFORMED BY

Megan Cassels-
Conway, DVM

HOSPITAL NAME

Central Broward
Animal Hospital

REFERRING VET

Megan Cassels-
Conway, DVM

INVOICE

72727

DATE

2/5/26

PRESENTING CLINICAL SIGNS

Recurring urinary tract infections. Hematuria noted 12/16, treated with 2 weeks clavamox and clear UA/culture. 4 days off antibiotics hematuria recurred. Clear UA/culture after 2 weeks of antibiotics. Historically has average of 1 UTI yearly.

Liver enzyme elevation. 10/12/25 seen at ER for vomiting, potential anaphylaxis. Noted galbladder wall edema and liver enzyme elevation. Treated with diphenhydramine, cerenia, denamarin. 2 weeks later liver enzymes significantly improved, ALP slight elevation, ALT wnl, GGT wnl, Tbili wnl.

O noted PU/PD past 1-2 months. 11/14/25 Seen for CCL tear L hind. Treated with carprofen. P is urinating on hindlimbs suspected due to different positioning to urinate. Pee pad trained only. Surgery postponed due to UTI. CCL treated with carprofen was on 2 months. 11/14/25 to 1/12/26. Liver enzymes continued to rise despite stopping carprofen. History of epilepsy. Seizures occur 1-4 times per year, not on any antiseizure medications. P is on rayne rabbit diet and famotidine for vomiting/regurgitation. Has been controlled about 1 year

Abnormal PE/Chem/CBC/UA Results: 1/28/26 CBC: PLT 527, Monocytosis 1702 CHEM: ALT 186, ALP 1388 UA: 1.009, 2+ protein C/S no growth 1/15/26 CBC: PLT 484, NRBC 3 CHEM: ALP 925, ALT 168, Chol 399, Glob 3.8 T4: WNL U/A: 1.019, 3+ protein, wbc 2-3, rods<10 C/S Ecoli heavy growth- sensitive to clavamox 1/9/26 UA: 1.010, 2+ protein C/S: No growth 12/16/25 UA: 1.007, 1+ protein, wbc 4-10, rods>100 C/S Ecoli- sensitive to clavamox 10/25/25 Chem: ALP 182 10/12/25 POCUS: No peritoneal effusion. Mild gallbladder wall edema. No evident abdominal masses - CBC/CHEM: Hct 59%, ALT 853, ALP 463, GGT 14, tBili 2.2 - VBG: Hct 58%, Na 149.6, K 3.46, gluc 101, lact 3.6, creat 0.9, BUN 13. 8/9/25 Cbc-WNL Chem- 8 H Fast TG- 507 H T4- 4.5H U/a Sp G 1020, Quiet sediment urine c/s- no growth 4/4/25 T4- 2.8 N TSh- 0.21 N Free t4 13.2

ULTRASONOGRAPHIC EXAMINATION OF THE ABDOMEN

Urinary System

The urinary bladder is moderately distended with anechoic urine. The Bladder wall, trigone, ureteral papillae and visible urethra (to a depth of 2cm) appear normal with no evidence of wall thickening, mucosal irregularities, or masses. There are rare pinpoint shadowing mineralizations in the dependent portion of the urinary bladder. Two visualized measure 0.13 cm and 0.15 cm.

The left kidney has a normal shape and size (4.54 cm) with occasional small non-obstructive nephroliths, an example of which measures 0.28 cm. Overall echogenicity is normal with adequate corticomedullary distinction and a typical 1:3 cortex:medulla ratio. There is no evidence of focal perinephric inflammation or effusion. There is no evidence of pyelectasia, infarcts or hydroureter. Renal vasculature is normal.

The right kidney has a normal shape and size (5.03 cm) with occasional pinpoint cortical mineralizations. Overall echogenicity is normal with adequate corticomedullary distinction and a typical 1:3 cortex:medulla ratio. There is no evidence of focal perinephric inflammation or effusion. There is no evidence of pyelectasia, infarcts or hydroureter. Renal vasculature is normal.



PATIENT

Eleanor Hoffman

SPECIES

Canine

BREED

Havanese

SEX

Spayed Female

AGE

8 Years

WEIGHT

20 lbs

INTERPRETED BY

Kathleen Sennello DVM,
MS, Diplomate ACVIM
(Small Animal Internal
Medicine)

**IMAGING
PERFORMED BY**

Megan Cassels-
Conway, DVM

HOSPITAL NAME

Central Broward
Animal Hospital

REFERRING VET

Megan Cassels-
Conway, DVM

INVOICE

72727

DATE

2/5/26

Adrenal Glands

The left adrenal gland is “plump” measuring 0.46 cm at the cranial pole and 0.59 cm at the caudal pole. It is observed in its normal position cranial to the left renal artery. It is normal in appearance (uniformly hypoechoic) and shape with no evidence of a mass effect.

The right adrenal gland is normal in size measuring 0.57 cm at the cranial pole and 0.57 cm at the caudal pole. It is observed in its normal position between the cranial aspect of the right kidney and the caudal vena cava. It is normal in appearance (uniformly hypoechoic) and shape with no evidence of a mass effect.

Spleen

The spleen is subjectively normal in size (0.88 cm), echotexture is homogenous, and the splenic capsule is smooth with no irregularities. The blood flow through the hilus and splenic parenchyma appears normal. No focal parenchymal abnormalities are visualized.

Liver

The liver is large in size with smooth peripheral margins. The parenchyma is hyperechoic and homogenous in echotexture. The visible portions of the vasculature and biliary tract appear normal. No focal nodules or cystic lesions are observed.

The gall bladder lumen is moderately distended. The wall of the gall bladder is not thickened and has a smooth mucosal surface. Luminal contents are mild and likely incidental at this time. The cystic and common bile ducts are normal/not visible.

Gastrointestinal

The stomach contains minimal luminal contents. It measures at a normal thickness of <0.7cm with some variability due to the presence of rugal folds. The distinction of the gastric wall layers is adequate and there is no impression of reduced peristaltic activity. No masses or focal lesions were observed.

The visualized areas of duodenum, jejunum and ileum have a relatively uniform diameter with minimal fluid distension. Wall thickness is normal. Bowel loops follow a curvilinear path with distinct wall layering maintaining the typical 1:3 muscularis:mucosa layer ratio. Duodenum wall measures 0.34 cm. Jejunum wall measures 0.31 cm. Visualized peristalsis appears appropriate. There were no focal lesions consistent with obstruction or a mass effect observed.

The ileocecal junction was visualized and exhibited normal intact wall layering and is subjectively of normal thickness. Sections of colon are visualized with formed fecal material and gas shadowing distally. There is no observed focal or generalized colon wall thickening or loss of layering.

Pancreas

The pancreas is normal and isoechoic to surrounding mesentery. There is no evidence of nodules or cystic lesions. There is no evidence of regional mesenteric inflammation or fluid.

Free Abdomen

Evaluation of the peritoneal cavity did not reveal any evidence of effusion, or subjective lymphadenomegaly. The Medial iliac nodes appear normal and there was no evidence of a caudal aortic thrombus at the bifurcation. The omentum is of normal uniform echogenicity.



PATIENT

Eleanor Hoffman

SPECIES

Canine

BREED

Havanese

SEX

Spayed Female

AGE

8 Years

WEIGHT

20 lbs

INTERPRETED BY

Kathleen Sennello DVM,
MS, Diplomate ACVIM
(Small Animal Internal
Medicine)

IMAGING PERFORMED BY

Megan Cassels-
Conway, DVM

HOSPITAL NAME

Central Broward
Animal Hospital

REFERRING VET

Megan Cassels-
Conway, DVM

INVOICE

72727

DATE

2/5/26

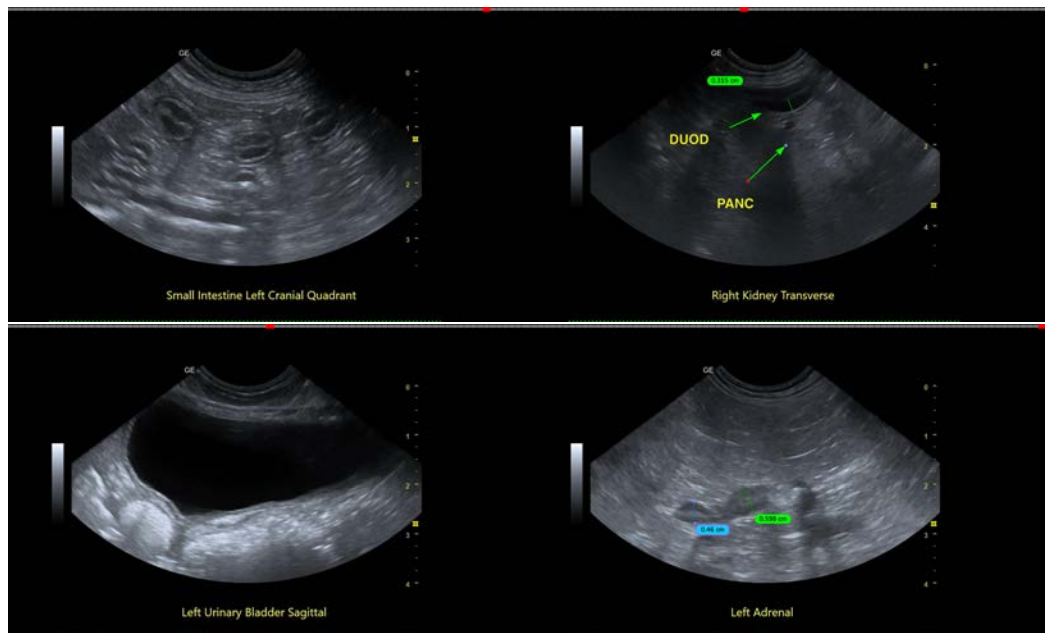
ULTRASONOGRAPHIC FINDINGS

- Normal/borderline “plump” adrenal glands – Findings could be consistent with anatomic variation or early hyperplasia.
- Pinpoint dependent mineralizations visualized in the urinary bladder – Findings are most consistent with small stones. These are likely small enough to pass.
- Large, hyperechoic liver – The appearance is most consistent with a vacuolar hepatopathy, although other hepatopathies are possible.

INTERPRETATION OF THE FINDINGS & FURTHER RECOMMENDATIONS

No focal lesions are visualized associated with the urinary bladder to explain the recurrent urinary tract infections reported. There are occasional small, mineralized foci that are likely small enough to pass currently. Given the liver changes and the recurrent urinary tract infections, you could consider adrenal function testing despite the adrenals not being overtly enlarged. Use caution with interpretation of results, as concurrent illness can cause false positives (fewer false positives with an ACTH stimulation test).

If further workup of the liver enzyme elevations is desired, recommend a liver function test and a fine needle aspirate of the liver.





PATIENT

Eleanor Hoffman

SPECIES

Canine

BREED

Havanese

SEX

Spayed Female

AGE

8 Years

WEIGHT

20 lbs

INTERPRETED BY

Kathleen Sennello DVM,
MS, Diplomate ACVIM
(Small Animal Internal
Medicine)

IMAGING PERFORMED BY

Megan Cassels-
Conway, DVM

HOSPITAL NAME

Central Broward
Animal Hospital

REFERRING VET

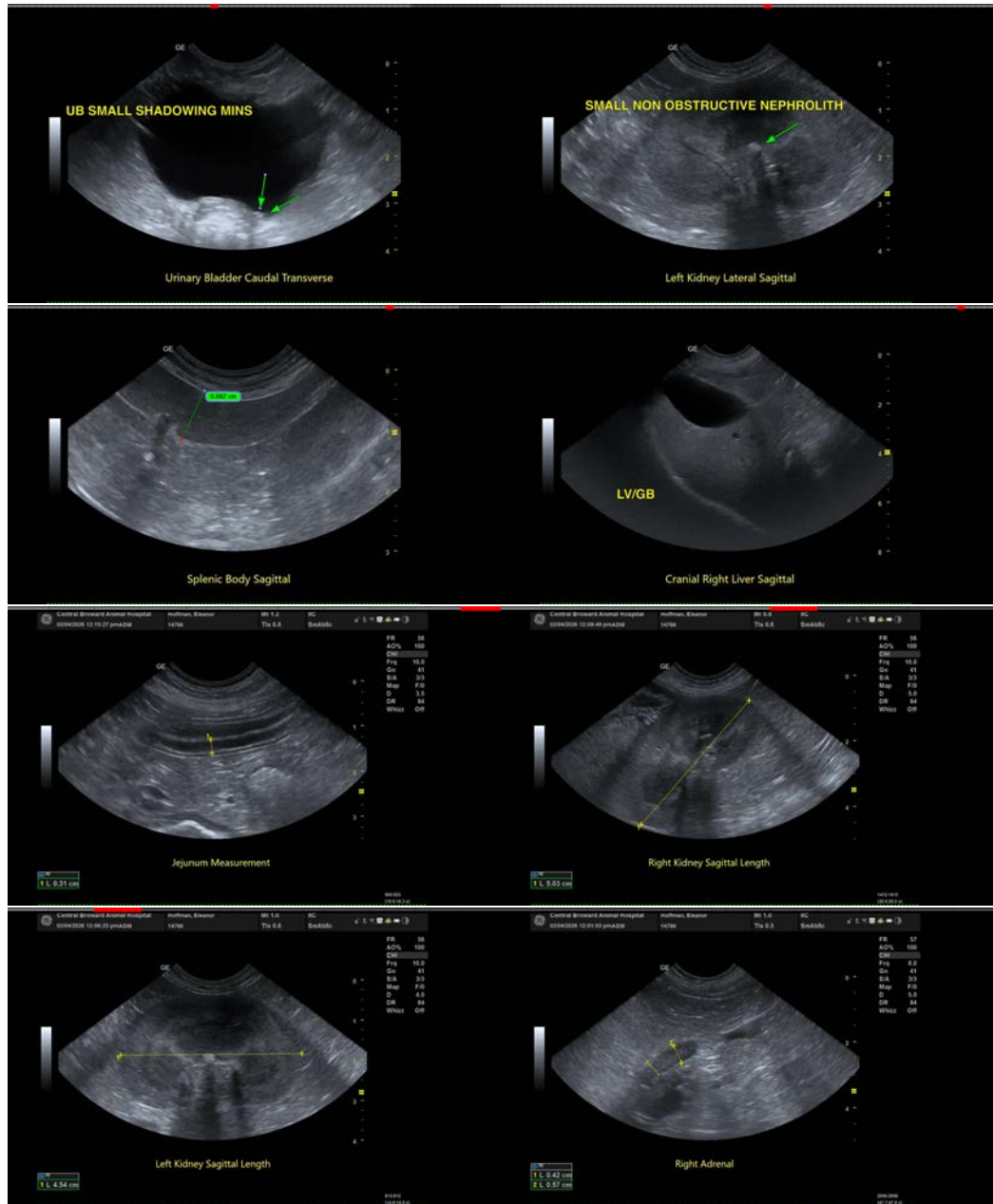
Megan Cassels-
Conway, DVM

INVOICE

72727

DATE

2/5/26



The information and recommendations provided are based on the images presented by the referring veterinarian/sonographer. No evaluation can be communicated regarding pathology that was not visible in the image/video clips provided.

Thank you for this referral. If the clinical or image interpretation does not parallel your findings or if I can be of any further assistance please contact me.

Kathleen Sennello DVM,MS, Diplomate ACVIM (Small animal Internal Medicine)

info@sonopath.com