



## PATIENT

Chester George

## SPECIES

Canine

## BREED

Labrador x

## SEX

Neutered Male

## AGE

10 Years

## WEIGHT

32.7 kg

## INTERPRETED BY

Kathleen Sennello DVM,  
MS, Diplomate ACVIM  
(Small Animal Internal  
Medicine)

## IMAGING PERFORMED BY

Dr. Iacovides

## HOSPITAL NAME

Tuxedo Animal  
Hospital

## REFERRING VET

Dr. Lameg

## INVOICE

72669

## DATE

2/3/26

## PRESENTING CLINICAL SIGNS

Pet has some CBC morphology changes. Reason for ultrasound is to r/o any evidence of neoplasia in the abdomen that would cause the morphology changes.

Pet has no spleen or left kidney, extensive scar tissue in abdomen due to gunshot wounds, right kidney has adhesions to duodenum and retroperitoneal space noted in previous sx to release bowel that was trapped and compromised due to scarring.

Abnormal PE/Chem/CBC/UA Results: CBC: Acantho 2+ Echino 2+ Echinoellipto 1+ Poly 1+ Pathologists comments attached

## ULTRASONOGRAPHIC EXAMINATION OF THE ABDOMEN

### Urinary System

The urinary bladder is moderately distended with anechoic urine. The Bladder wall, trigone, ureteral papillae and visible urethra (to a depth of 2cm) appear normal with no evidence of wall thickening, mucosal irregularities, masses or cystic calculi.

The prostate is normal in size (1.26 cm) and shape for this neutered male dog. The parenchyma is homogenous and the external margins are smooth. The prostatic urethra appears normal with no evidence of irregularity, invasion, mass effect or calculi.

The left kidney is surgically absent.

The right kidney has a normal shape and size (7.0 cm). Overall echogenicity is normal with adequate corticomedullary distinction and a typical 1:3 cortex:medulla ratio. There is no evidence of focal perinephric inflammation or effusion. There is no evidence of pyelectasia, nephroliths, infarcts or hydroureter. Renal vasculature is normal.

### Adrenal Glands

The left adrenal gland is normal in size measuring 0.79 cm at the caudal pole. It is observed in its normal position cranial to the left renal artery. It is normal in appearance (uniformly hypoechoic) and shape with no evidence of a mass effect. The cranial pole is not clearly visualized.

The region of the right adrenal (between right cranial kidney and vena cava) is unremarkable, but the adrenal is not distinctly visualized. No evidence of a mass effect is visualized.

### Spleen

The spleen is surgically absent.

### Liver

The liver is subjectively normal in size, and echogenicity with smooth peripheral margins. The parenchyma is homogenous echotexture. The visible portions of the vasculature and biliary tract appear normal. No focal nodules or cystic lesions are observed.

The gall bladder lumen is moderately distended. The wall of the gall bladder is not thickened and has a smooth mucosal surface. There is a moderate amount of non-organized echogenic debris. The cystic and common bile ducts are normal/not visible.



**PATIENT**

Chester George

**SPECIES**

Canine

**BREED**

Labrador x

**SEX**

Neutered Male

**AGE**

10 Years

**WEIGHT**

32.7 kg

**INTERPRETED BY**

Kathleen Sennello DVM,  
MS, Diplomate ACVIM  
(Small Animal Internal  
Medicine)

**IMAGING  
PERFORMED BY**

Dr. Iacovides

**HOSPITAL NAME**

Tuxedo Animal  
Hospital

**REFERRING VET**

Dr. Lameg

**INVOICE**

72669

**DATE**

2/3/26

**Gastrointestinal**

The stomach contains minimal luminal contents. It measures at a normal thickness of <0.7cm with some variability due to the presence of rugal folds. The distinction of the gastric wall layers is adequate and there is no impression of reduced peristaltic activity. No masses or focal lesions were observed.

The visualized areas of duodenum, jejunum and ileum have a relatively uniform diameter with minimal fluid distension. Wall thickness is normal. Bowel loops follow a curvilinear path with distinct wall layering maintaining the typical 1:3 muscularis:mucosa layer ratio. Jejunum wall measures 0.41 cm. Visualized peristalsis appears appropriate. There were no focal lesions consistent with obstruction or a mass effect observed.

The ileocecal junction was visualized and exhibited normal intact wall layering and is subjectively of normal thickness. Sections of colon are visualized with formed fecal material and gas shadowing distally. There is no observed focal or generalized colon wall thickening or loss of layering.

**Pancreas**

The pancreas is normal and isoechoic to surrounding mesentery. There is no evidence of nodules or cystic lesions. There is no evidence of regional mesenteric inflammation or fluid.

**Free Abdomen**

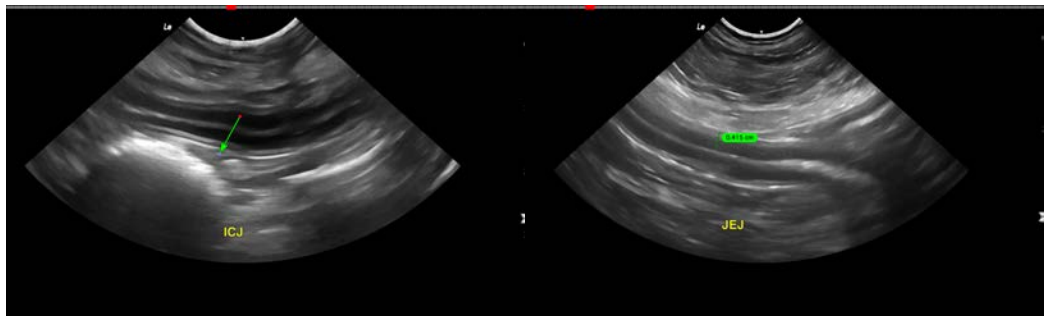
Evaluation of the peritoneal cavity did not reveal any evidence of effusion, or subjective lymphadenomegaly. The Medial iliac nodes appear normal and there was no evidence of a caudal aortic thrombus at the bifurcation. The omentum is of normal uniform echogenicity.

**ULTRASONOGRAPHIC FINDINGS**

- Moderate gallbladder debris – The significance of the aggregated gallbladder debris is unclear. This could represent an early mucocele, cholestasis, or may be secondary to fasting but seems unlikely to be causing a current issue. Recommend continued monitoring.
- Surgically absent spleen and left kidney.

**INTERPRETATION OF THE FINDINGS & FURTHER RECOMMENDATIONS**

No focal mass lesions were visualized on today's exam to explain the changes in red blood cell morphology reported. Recommend continued monitoring and follow up evaluations with pathology reviews, looking for evidence of progressive change.





## PATIENT

Chester George

## SPECIES

Canine

## BREED

Labrador x

## SEX

Neutered Male

## AGE

10 Years

## WEIGHT

32.7 kg

## INTERPRETED BY

Kathleen Sennello DVM,  
MS, Diplomate ACVIM  
(Small Animal Internal  
Medicine)

## IMAGING PERFORMED BY

Dr. Iacovides

## HOSPITAL NAME

Tuxedo Animal  
Hospital

## REFERRING VET

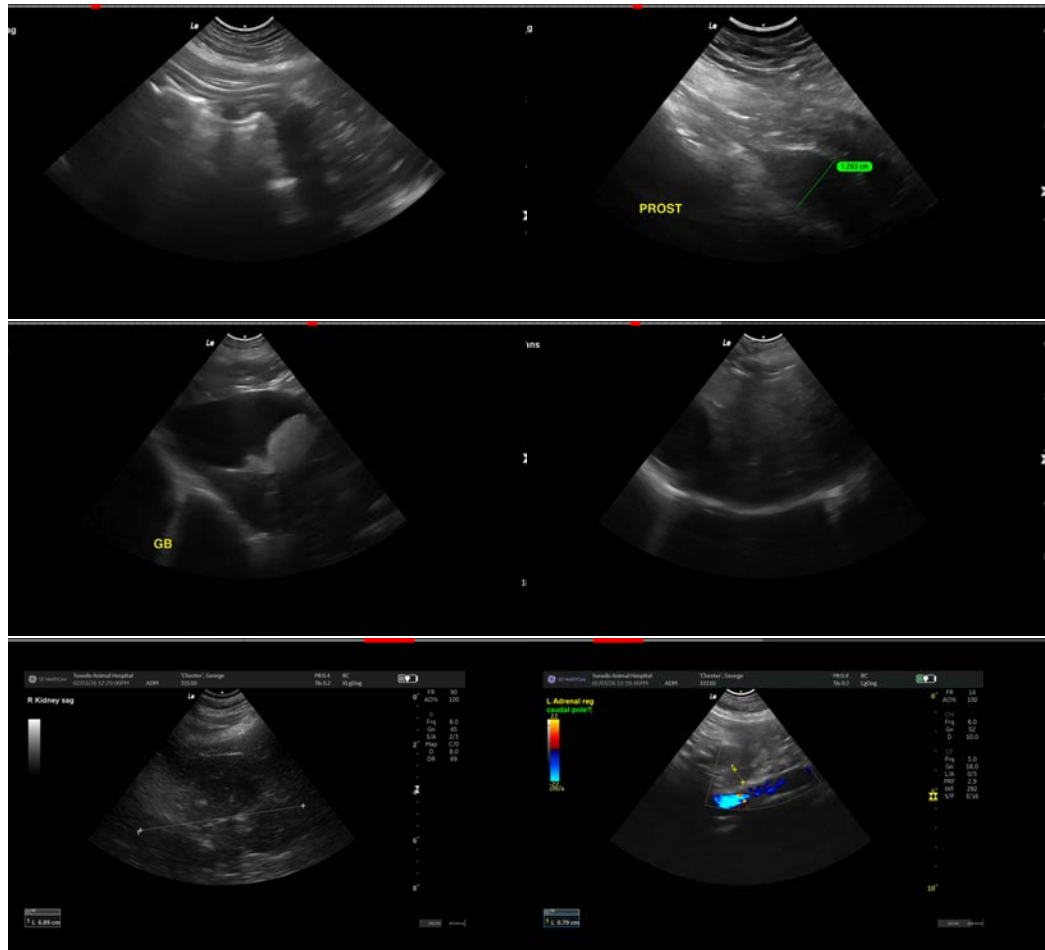
Dr. Lameg

## INVOICE

72669

## DATE

2/3/26



The information and recommendations provided are based on the images presented by the referring veterinarian/sonographer. No evaluation can be communicated regarding pathology that was not visible in the image/video clips provided.

Thank you for this referral. If the clinical or image interpretation does not parallel your findings or if I can be of any further assistance please contact me.

Kathleen Sennello DVM,MS, Diplomate ACVIM (Small animal Internal Medicine)

info@sonopath.com