

**DATE PRESENTING CLINICAL SIGNS**

2/28/23

PATIENT

Molly Mullen

History of vomiting for years. End of November beginning of December seemed worse. At that time owner moved in with her daughter. Seen at rDVM - full work up per owner and was diagnosed with pancreatitis. Per owner thyroid in grey zone. Treated with medications and restricted amounts of food / frequency. Had been eating wet food then she wanted dry but would vomit following. Has become ravenous for food - especially for dry Last week owner tried purina sensitive stomach - did well for a day then started vomiting also having diarrhea.

SPECIES

Feline

Current Medications: Ampicillin, Protonix, Cerenia, Vitamin B12, Buprenorphine.

Lab Results: See attached.

Date of Previous IntraPet Ultrasound: No previous.

Sedation: IV propofol.

BREED

DSH

Stat Report: Not requested.

Imaging Performed By: Rachel Brillhart, RDMS.

SEX

Spayed Female

ULTRASONOGRAPHIC EXAMINATION OF THE ABDOMEN**Urinary System**

The urinary bladder is moderately distended with anechoic urine. The Bladder wall, trigone, ureteral papillae and visible urethra (to a depth of 2cm) appear normal with no evidence of wall thickening, mucosal irregularities, masses or cystic calculi.

AGE

8/16/11

The left kidney has a normal shape and size (3.89 cm) with occasional pinpoint non-obstructive nephroliths. Overall echogenicity is slightly hyperechoic with poor corticomedullary distinction and a typical 1:3 cortex:medulla ratio. There is no evidence of focal perinephric inflammation or effusion. There is no evidence of pyelectasia, infarcts or hydroureter. Renal vasculature is normal.

WEIGHT

6.6 Pounds

INTERPRETED BY

Kathleen Sennello DVM,
MS, Diplomate ACVIM
(Small Animal Internal
Medicine)

The right kidney has a normal shape and size (3.55 cm) with occasional pinpoint non-obstructive nephroliths. Overall echogenicity is slightly hyperechoic with poor corticomedullary distinction and a typical 1:3 cortex:medulla ratio. There is no evidence of focal perinephric inflammation or effusion. There is no evidence of pyelectasia, infarcts or hydroureter. Renal vasculature is normal.

HOSPITAL NAME

Animal Emergency
Hospital

Adrenal Glands

The left adrenal gland is normal in size measuring 0.43 cm at the caudal pole. It is observed in its normal position cranial to the left renal artery. It is normal in appearance (uniformly hypoechoic) and shape with no evidence of a mass effect.

REFERRING VET

Dr. Saubier

The right adrenal gland is normal in size measuring 0.45 cm at the caudal pole. It is observed in its normal position between the cranial aspect of the right kidney and the caudal vena cava. It is normal in appearance (uniformly hypoechoic) and shape with no evidence of a mass effect.

INVOICE

45562

Spleen

The spleen is subjectively normal in size (0.69 cm), echotexture is homogenous, and the splenic capsule is smooth with no irregularities. The blood flow through the hilus and splenic parenchyma appears normal. No focal parenchymal abnormalities are visualized.

Liver

The liver is subjectively normal in size, and echogenicity with smooth peripheral margins. The parenchyma is homogenous echotexture. The visible portions of the vasculature and biliary tract appear normal. No focal nodules or cystic lesions are observed.

The gallbladder lumen is moderately distended. The wall of the gall bladder is not thickened and has a smooth mucosal surface. Luminal contents are mild and primarily anechoic. The cystic and common bile ducts are normal/not visible.

Gastrointestinal

The stomach contains minimal luminal contents. It measures at a normal thickness of <0.36cm with some variability due to the presence of rugal folds. The distinction of the gastric wall layers is adequate and there is no impression of reduced peristaltic activity. No masses or focal lesions were observed.

The visualized areas of duodenum, jejunum and ileum have a uniform diameter with minimal fluid distension. Wall thickness is normal to slightly increased. Bowel loops follow a typical curvilinear path with distinct wall layering, but some areas display a prominent muscularis layer which does not display the typical 1:3 muscularis:mucosa layer ratio. Jejunum wall measures 0.22-0.32 cm. Visualized peristalsis appears appropriate. Some of the bowel loops appear to have more pronounced thickening with significant reduction and detail of wall layering. In these regions, the bowel wall measures at 0.47 cm.

The ileocecal junction was visualized and exhibited normal intact wall layering and is subjectively of normal thickness. Sections of colon are visualized with formed fecal material and gas shadowing distally. There is no observed focal or generalized colon wall thickening or loss of layering.

Pancreas

The pancreas is prominent and mottled compared to the surrounding isoechoic mesentery. There is no evidence of nodules or cystic lesions. There is no evidence of regional mesenteric inflammation or fluid.

Free Abdomen

There is a scant amount of free fluid. There is a significant mesenteric lymphadenopathy with irregular hypoechoic lymph nodes measuring 0.72, 0.44, and 0.66 cm. The omentum is generally hyperechoic.

PRIMARY FINDINGS

- Prominent, mottled pancreas – The pancreatic changes are most consistent with mild pancreatitis or a recent episode of pancreatic inflammation.
- Diffuse thickening of the small intestine with prominent muscularis layer. Additionally, some focally thickened regions are visualized with significant loss of wall layering – The bowel wall thickening could be consistent with inflammation, edema, or infiltrative neoplasia. A reduction in the detail of wall layering favors either severe intestinal disease or neoplastic infiltration. Biopsy is recommended.
- Scant free abdominal fluid
- Moderate mesenteric lymphadenopathy – The moderate mesenteric lymphadenopathy could be concerning for a neoplastic process, although you can see significant lymphadenopathy in some cases of autoimmune/inflammatory disease, infectious disease (tick born disease-such as bartonella, fungal infections, FIP (cats)) etc. A fine needle aspirate with cytology is recommended for further evaluation.

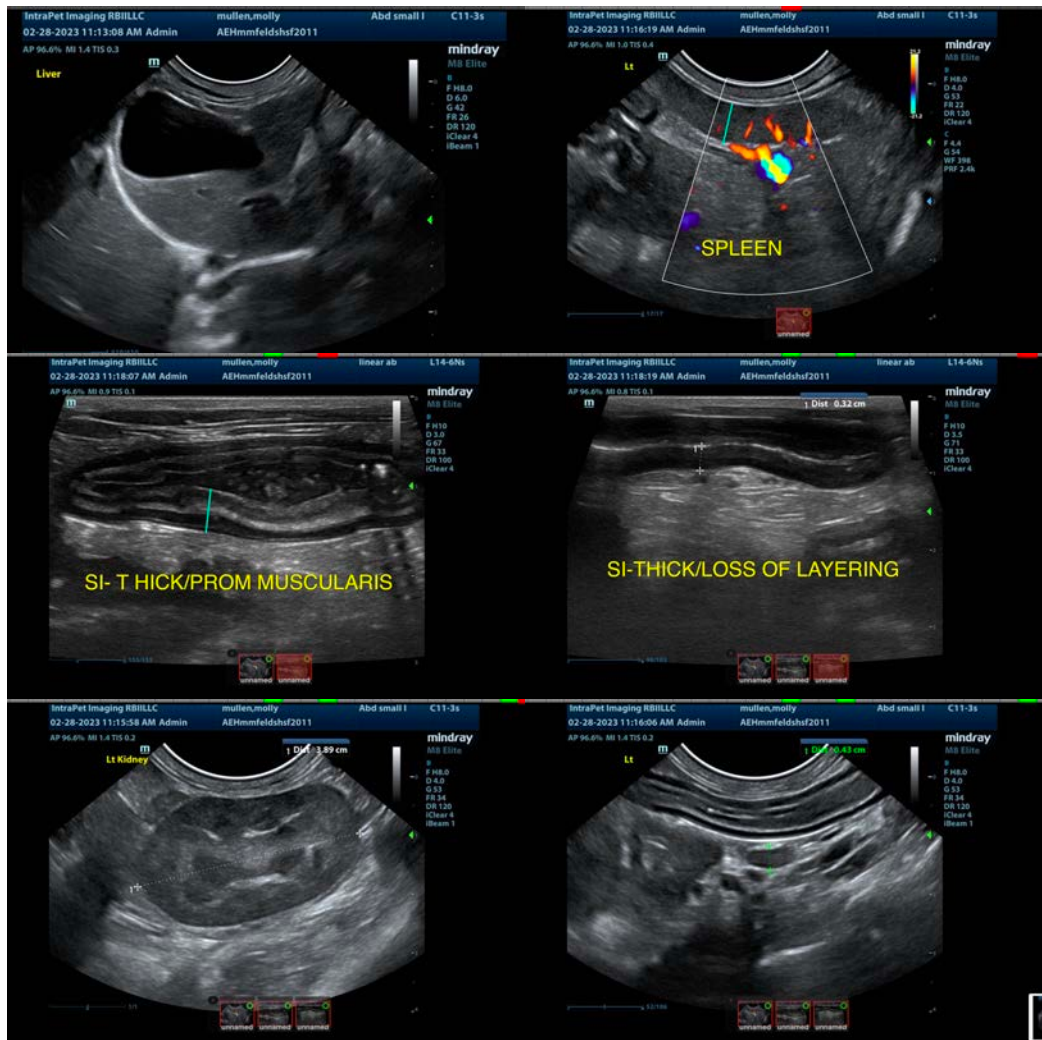
SECONDARY FINDINGS

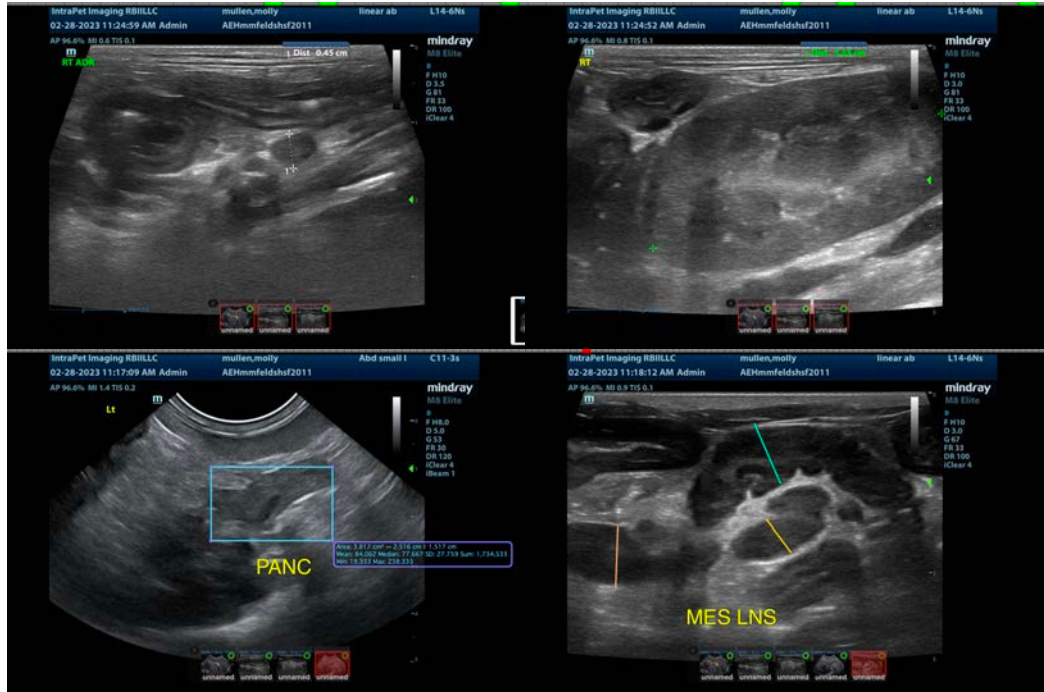
- Decreased corticomedullary distinction in both kidneys with pinpoint non-obstructive nephroliths – The bilateral renal findings are consistent with age-related change.

INTERPRETATION OF THE FINDINGS & FURTHER RECOMMENDATIONS

There is diffuse small intestinal thickening observed in addition to a diffuse moderate lymphadenopathy. Additionally, there are some regions of the small bowel that appear to have more pronounced thickening and significantly reduced detail of wall layering. These areas are concerning for possible infiltrative disease (round cell neoplasia), although severe inflammatory processes are possible. Recommend a fine needle aspirate of an enlarged mesenteric lymph node and 3-view thoracic radiographs. If cytologic diagnosis cannot be obtained based on lymph node sampling, then consider obtaining GI biopsies (likely surgical so that abnormal bowel sections can be sampled).

The pancreas is somewhat prominent, but I suspect this is more consistent with previous of inflammation. While awaiting cytologic results, recommend symptomatic treatment for pancreatitis/gastroenteritis.





The information and recommendations provided are based on the images presented by the referring veterinarian/sonographer. No evaluation can be communicated regarding pathology that was not visible in the image/video clips provided.

Thank you for this referral. If the clinical or image interpretation does not parallel your findings or if I can be of any further assistance please contact me.

Kathleen Sennello DVM,MS, Diplomate ACVIM (Small animal Internal Medicine)
kathleen.sennello@sonopath.com