



PATIENT

Mama Marino

SPECIES

Canine

BREED

Mixed

SEX

Spayed Female

AGE

6 Years

WEIGHT

92 Pounds

INTERPRETED BY

Kathleen Sennello DVM,
MS, Diplomate ACVIM
(Small Animal Internal
Medicine)

IMAGING PERFORMED BY

Dr. Elaina Petrone

HOSPITAL NAME

Long Branch AH

REFERRING VET

Dr. Elaina Petrone

INVOICE

45570

DATE

2/28/23

PRESENTING CLINICAL SIGNS

Intermittent decreased appetite and vomiting. Bile acids pre and post <1.0. ALP: 292 ALT: 729 GGT: 18 Tbili: 0.3 Not vaccinated for Lepto.

ULTRASONOGRAPHIC EXAMINATION OF THE ABDOMEN

Urinary System

The urinary bladder is moderately distended with anechoic urine. The Bladder wall, trigone, ureteral papillae and visible urethra (to a depth of 2cm) appear normal with no evidence of wall thickening, mucosal irregularities, masses or cystic calculi.

The left kidney has a normal shape and size (6.37 cm). Overall echogenicity is normal with adequate corticomedullary distinction and a typical 1:3 cortex:medulla ratio. There is no evidence of focal perinephric inflammation or effusion. There is no evidence of pyelectasia, nephroliths, infarcts or hydroureter. Renal vasculature is normal.

The right kidney has a normal shape and size (6.85 cm). Overall echogenicity is normal with adequate corticomedullary distinction and a typical 1:3 cortex:medulla ratio. There is no evidence of focal perinephric inflammation or effusion. There is no evidence of pyelectasia, nephroliths, infarcts or hydroureter. Renal vasculature is normal.

Adrenal Glands

The left adrenal gland is normal in size measuring 0.82 cm at the caudal pole. It is observed in its normal position cranial to the left renal artery. It is normal in appearance (uniformly hypoechoic) and shape with no evidence of a mass effect.

The region of the right adrenal (between right cranial kidney and vena cava) is unremarkable, but the adrenal is not distinctly visualized. No evidence of a mass effect is visualized.

Spleen

The spleen is subjectively normal in size, echotexture is homogenous, and the splenic capsule is smooth with no irregularities. The blood flow through the hilus and splenic parenchyma appears normal. No focal parenchymal abnormalities are visualized.

Liver

The liver is subjectively normal in size, and echogenicity with smooth peripheral margins. The parenchyma is homogenous echotexture. The visible portions of the vasculature and biliary tract appear normal. No focal nodules or cystic lesions are observed.

The gall bladder lumen is moderately distended. The wall of the gall bladder is not thickened and has a smooth mucosal surface. There is a moderate amount of non-organized echogenic debris. The cystic and common bile ducts are normal/not visible.

Gastrointestinal

The stomach contains minimal luminal contents. It measures at a normal thickness of <0.7cm with some variability due to the presence of rugal folds. The distinction of the gastric wall layers is adequate and there is no impression of reduced peristaltic activity. No masses or focal lesions were observed.

The visualized areas of duodenum, jejunum and ileum have a relatively uniform diameter with minimal fluid distension. Wall thickness is normal. Bowel loops follow a curvilinear path with distinct wall



PATIENT

Mama Marino

layering maintaining the typical 1:3 muscularis:mucosa layer ratio. Duodenum wall measured 0.47 cm. Jejunum wall measures 0.36 cm. Visualized peristalsis appears appropriate. There were no focal lesions consistent with obstruction or a mass effect observed.

SPECIES

Canine

The ileocecal junction was visualized and exhibited normal intact wall layering and is subjectively of normal thickness. Sections of colon are visualized with formed fecal material and gas shadowing distally. There is no observed focal or generalized colon wall thickening or loss of layering.

BREED

Pancreas

Mixed

The pancreas is normal and isoechoic to surrounding mesentery. There is no evidence of nodules or cystic lesions. There is no evidence of regional mesenteric inflammation or fluid.

SEX

Spayed Female

Free Abdomen

Evaluation of the peritoneal cavity did not reveal any evidence of effusion, or subjective lymphadenomegaly. The Medial iliac nodes appear normal and there was no evidence of a caudal aortic thrombus at the bifurcation. The omentum is of normal uniform echogenicity.

AGE

6 Years

ULTRASONOGRAPHIC FINDINGS

WEIGHT

92 Pounds

- Moderate debris in the gallbladder – The significance of the aggregated gallbladder debris is unclear. This could represent an early mucocele, cholestasis, or may be secondary to fasting but seems unlikely to be causing a current issue. Recommend continued monitoring.

INTERPRETED BY

Kathleen Sennello DVM, MS, Diplomate ACVIM (Small Animal Internal Medicine)

INTERPRETATION OF THE FINDINGS & FURTHER RECOMMENDATIONS

No major focal lesions are visualized on today's exam to explain the liver enzyme elevations and the symptoms reported. Your initial step of performing a liver function test is a good one, but the ALT elevation is still significant, so I suspect there is some source of damage to the liver tissue, which as of yet is not severe enough to cause a decrease in function. Screening for Leptospirosis is an excellent idea. Additionally, I would consider a fine needle aspirate of the liver, provided coagulation parameters are normal. Consider starting Ursodiol, and if liver enzymes continue to rise despite taking these measures, a liver biopsy may need to be considered in the future, and possibly rechecking bile acids.

IMAGING PERFORMED BY

Dr. Elaina Petrone

My suspicion would be that the GI signs reported are secondary to what's going on in the liver. The changes in the gallbladder are relatively mild and unlikely to be causing symptoms at this time. You could consider a GI panel to Texas A&M for a qualitative PLI, TLI, cobalamin and folate to look for additional evidence of underlying concurrent gastrointestinal issues that may need further evaluation.

HOSPITAL NAME

Long Branch AH

REFERRING VET

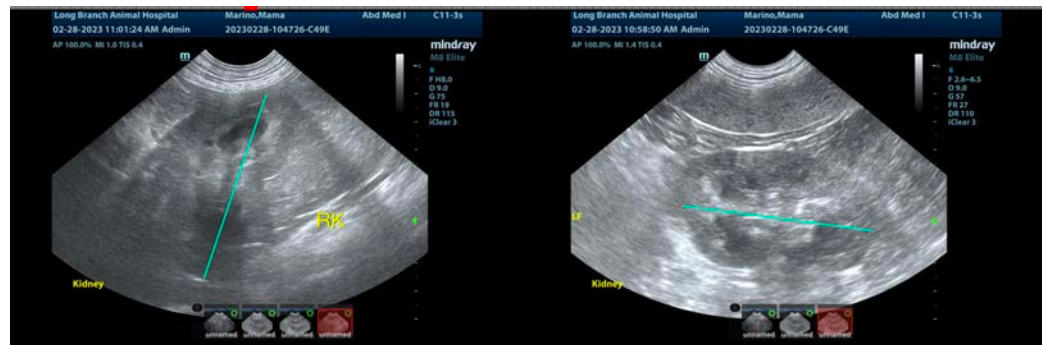
Dr. Elaina Petrone

INVOICE

45570

DATE

2/28/23





PATIENT

Mama Marino

SPECIES

Canine

BREED

Mixed

SEX

Spayed Female

AGE

6 Years

WEIGHT

92 Pounds

INTERPRETED BY

Kathleen Sennello DVM,
MS, Diplomate ACVIM
(Small Animal Internal
Medicine)

**IMAGING
PERFORMED BY**

Dr. Elaina Petrone

HOSPITAL NAME

Long Branch AH

REFERRING VET

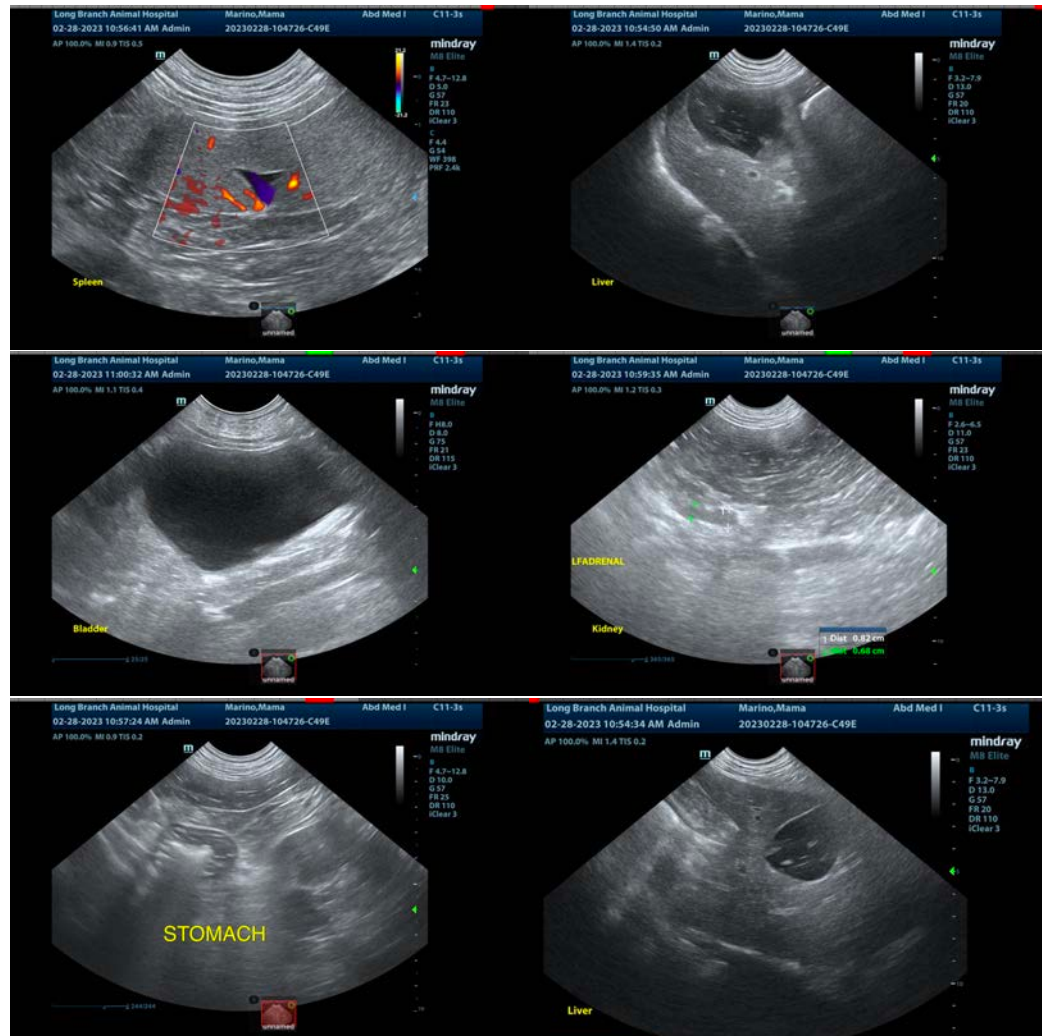
Dr. Elaina Petrone

INVOICE

45570

DATE

2/28/23



The information and recommendations provided are based on the images presented by the referring veterinarian/sonographer. No evaluation can be communicated regarding pathology that was not visible in the image/video clips provided.

Thank you for this referral. If the clinical or image interpretation does not parallel your findings or if I can be of any further assistance please contact me.

Kathleen Sennello DVM,MS, Diplomate ACVIM (Small animal Internal Medicine)

kathleen.sennello@sonopath.com