



PATIENT

Mac Taylor

SPECIES

Canine

BREED

Pug

SEX

Neutered Male

AGE

17 Years

WEIGHT

28 lbs

INTERPRETED BY

Kathleen Sennello DVM,
MS, Diplomate ACVIM
(Small Animal Internal
Medicine)

**IMAGING
PERFORMED BY**

Loetitia Saint-Jacques,
LVT

HOSPITAL NAME

Peavine Animal
Hospital

REFERRING VET

Dr. Morford

INVOICE

73319

DATE

2/26/26

PRESENTING CLINICAL SIGNS

Hypoalbuminemia. Urinary tract infection. Chronic diarrhea. Colitis. Elevated kidney enzymes.

Abnormal PE/Chem/CBC/UA Results: ALB 2.5 ALP 291 SDMA 15 BUN 40 Creat 2.1 USG 1031 K+ 5.6

ULTRASONOGRAPHIC EXAMINATION OF THE ABDOMEN

Urinary System

The urinary bladder is moderately distended with a large amount of suspended and dependent echogenic debris. The Bladder wall, trigone, ureteral papillae and visible urethra (to a depth of 2cm) appear normal with no evidence of wall thickening, mucosal irregularities, masses or cystic calculi.

The prostate is normal in size (1.1 cm) and shape for this neutered male dog. The parenchyma is homogenous and the external margins are smooth. The prostatic urethra appears normal with no evidence of irregularity, invasion, mass effect or calculi.

The left kidney has a normal shape and size (4.19 cm). Overall echogenicity is normal with adequate corticomedullary distinction and a typical 1:3 cortex:medulla ratio. There is no evidence of focal perinephric inflammation or effusion. There is no evidence of pyelectasia, nephroliths, infarcts or hydroureter. Renal vasculature is normal.

The right kidney has a normal shape and size (5.06 cm). Overall echogenicity is normal with adequate corticomedullary distinction and a typical 1:3 cortex:medulla ratio. There is no evidence of focal perinephric inflammation or effusion. There is no evidence of pyelectasia, nephroliths, infarcts or hydroureter. Renal vasculature is normal.

Adrenal Glands

The left adrenal gland is large and abnormal in appearance, measuring 2.71 cm at the cranial pole and 0.79 cm at the caudal pole. It is observed in its normal position cranial to the left renal artery. It is abnormal in appearance in that there is a large mixed echogenicity mass effect at the cranial pole. No evidence of vascular invasion is visualized.

The right adrenal gland is normal in size measuring 0.25 cm at the caudal pole. It is observed in its normal position between the cranial aspect of the right kidney and the caudal vena cava. It is normal in appearance (uniformly hypoechoic) and shape with no evidence of a mass effect.

Spleen

The spleen is subjectively normal in size (1.87 cm), echotexture is homogenous, and the splenic capsule is smooth with no irregularities. The blood flow through the hilus and splenic parenchyma appears normal. There is a small hypoechoic nodule in the parenchyma measuring 0.39 cm.

Liver

The liver is subjectively normal in size, and echogenicity with smooth peripheral margins. The parenchyma is heterogenous in echotexture with subtle, indistinct focal mottling. The visible portions of the vasculature and biliary tract appear normal. There are numerous ill-defined hypoechoic nodules visualized throughout the parenchyma. An example on the left side measures 1.46 cm x 2.43 cm. Additionally there is a hyperechoic nodule on the left side of the liver measuring 1.89 cm in diameter.



PATIENT

Mac Taylor

SPECIES

Canine

BREED

Pug

SEX

Neutered Male

AGE

17 Years

WEIGHT

28 lbs

INTERPRETED BY

Kathleen Sennello DVM,
MS, Diplomate ACVIM
(Small Animal Internal
Medicine)

**IMAGING
PERFORMED BY**

Loetitia Saint-Jacques,
LVT

HOSPITAL NAME

Peavine Animal
Hospital

REFERRING VET

Dr. Morford

INVOICE

73319

DATE

2/26/26

The gall bladder lumen is significantly distended. Some areas of the wall appear mildly thickened with adherent debris and there is organization and stranding of this debris into a mucocele. There is a small amount of surrounding inflammation. No obvious free fluid observed. The bile duct is normal/not visible. Findings are consistent with a mucocele. Consider close monitoring and initial medical management.

Gastrointestinal

The stomach contains minimal luminal contents. It measures at a normal thickness of <0.7cm with some variability due to the presence of rugal folds. The distinction of the gastric wall layers is adequate and there is no impression of reduced peristaltic activity. No masses or focal lesions were observed.

The visualized areas of duodenum, jejunum and ileum have a relatively uniform diameter with minimal fluid distension. Wall thickness is normal. Bowel loops follow a curvilinear path with distinct wall layering maintaining the typical 1:3 muscularis:mucosa layer ratio. Jejunum wall measures 0.34 cm. Visualized peristalsis appears appropriate. There were no focal lesions consistent with obstruction or a mass effect observed.

Sections of colon are visualized with formed fecal material and gas shadowing distally. There is no observed focal or generalized colon wall thickening or loss of layering.

Pancreas

The area of the pancreas is normal and isoechoic to surrounding mesentery. There is no evidence of nodules or cystic lesions. There is no evidence of regional mesenteric inflammation or fluid.

Free Abdomen

Evaluation of the peritoneal cavity did not reveal any evidence of effusion. No significant lymphadenopathy noted. The omentum is slightly hyperechoic in the region of the gallbladder.

ULTRASONOGRAPHIC FINDINGS

- Large amount of dependent and suspended echogenic debris in the urinary bladder – The echogenic debris in the bladder lumen could be consistent with cells, crystals, and/or mucus.
- Large, mixed echogenicity, slightly cystic left adrenal mass lesion – Possible differentials include an adenoma, carcinoma, pheochromocytoma, other.
- Small hypoechoic splenic nodule – There is a non-cavitated, hypoechoic splenic nodule visualized. Differentials include lymphoid hyperplasia, extramedullary hematopoiesis, infiltrative neoplasia, inflammation, other. Cytology or histopathology would be necessary to get a definitive diagnosis.
- Heterogeneous liver with ill-defined hypoechoic nodules – The diffuse hepatic changes are non-specific and could be consistent with vacuolar hepatopathy, nodular hyperplasia, inflammatory/immune-mediated disease, fibrosis, extramedullary hematopoiesis, toxic hepatopathy (e.g., copper), infiltrative neoplasia (less likely) or other hepatopathy. The nodules observed trend toward a more benign process, but underlying neoplasia cannot be ruled out.
- Large distended gallbladder with a large amount of echogenic debris and early organization into a mucocele.



PATIENT

Mac Taylor

SPECIES

Canine

BREED

Pug

SEX

Neutered Male

AGE

17 Years

WEIGHT

28 lbs

INTERPRETED BY

Kathleen Sennello DVM,
MS, Diplomate ACVIM
(Small Animal Internal
Medicine)

IMAGING PERFORMED BY

Loetitia Saint-Jacques,
LVT

HOSPITAL NAME

Peavine Animal
Hospital

REFERRING VET

Dr. Morford

INVOICE

73319

DATE

2/26/26

INTERPRETATION OF THE FINDINGS & FURTHER RECOMMENDATIONS

The gallbladder is large and distended with a large amount of intraluminal debris. Some of this debris appeared adhered to the gallbladder wall and is starting to form mucosal strands, consistent with a mucocele. Additionally, there is some mild inflammation surrounding the gallbladder. Recommend medical management for cholecystitis and a mucocele with Ursodiol, Denamarin, and a course of antibiotics with close continued monitoring, as a cholecystectomy may be warranted in the near future. There could be some risk for rupture, particularly if the patient clinically deteriorates.

There is a large amount of dependent and suspended echogenic debris in the urinary bladder. Recommend a urinalysis and culture for further evaluation.

There is a left-sided adrenal mass lesion. If signs of Cushing's are present, consider adrenal function testing. Additionally, consider blood pressure evaluation. If hypertension is present, consider measuring catecholamine levels, looking for a possible pheochromocytoma. If surgical intervention would be considered, recommend a contrast CT scan to look for any evidence of vascular invasion, metastasis, etc. The gallbladder could also be evaluated at this time.

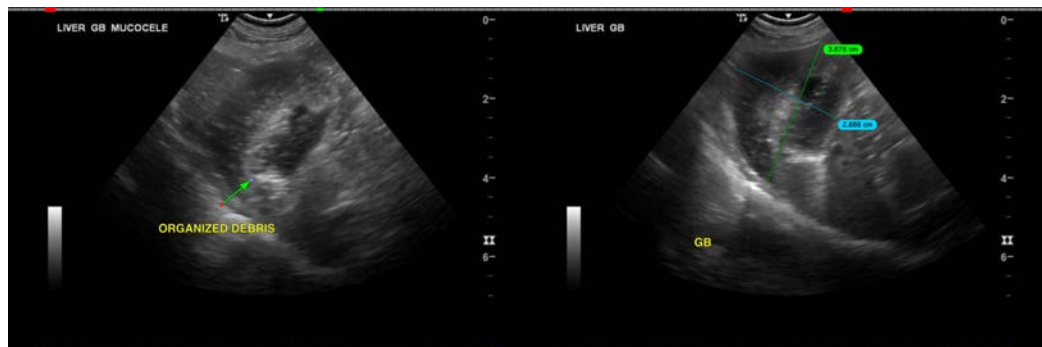
There is a small nodule in the spleen. Options moving forward include continued monitoring or a fine needle aspirate (may be challenging to sample, as it is very small).

The liver is heterogeneous with numerous hypoechoic nodules. These generally have an appearance most consistent with regenerative nodules, but metastatic lesions or similar cannot be ruled out.

The patient is azotemic and has low albumin levels. Recommend fluid therapy and assessment for urinary tract infection/pyelonephritis. Additionally consider a urine protein to creatinine ratio (as long as urine sediment is quiet), and potentially a liver function test, looking for causes of hypoalbuminemia. The GI tract did not overtly look abnormal but this could certainly be a source of the low albumin levels, as the patient has a history of diarrhea.

Additional evaluation could include a GI panel to Texas A&M for a qualitative PLI, TLI, cobalamin and folate as well as a hydrolyzed protein prescription diet.

Recommend three view thoracic radiographs to evaluate for possible concurrent thoracic disease/involvement (disregard if this has already been done).



Imaging performed by



pawsonography@gmail.com
530-786-8340



Clinical Sonography & Telectology
Educational Teleconsultation Services™

SonoPath

FOSTERING THE ART OF VETERINARY MEDICINE™

SonoPath.com info@sonopath.com 1.800.838.4268

PATIENT

Mac Taylor

SPECIES

Canine

BREED

Pug

SEX

Neutered Male

AGE

17 Years

WEIGHT

28 lbs

INTERPRETED BY

Kathleen Sennello DVM,
MS, Diplomate ACVIM
(Small Animal Internal
Medicine)

IMAGING PERFORMED BY

Loetitia Saint-Jacques,
LVT

HOSPITAL NAME

Peavine Animal
Hospital

REFERRING VET

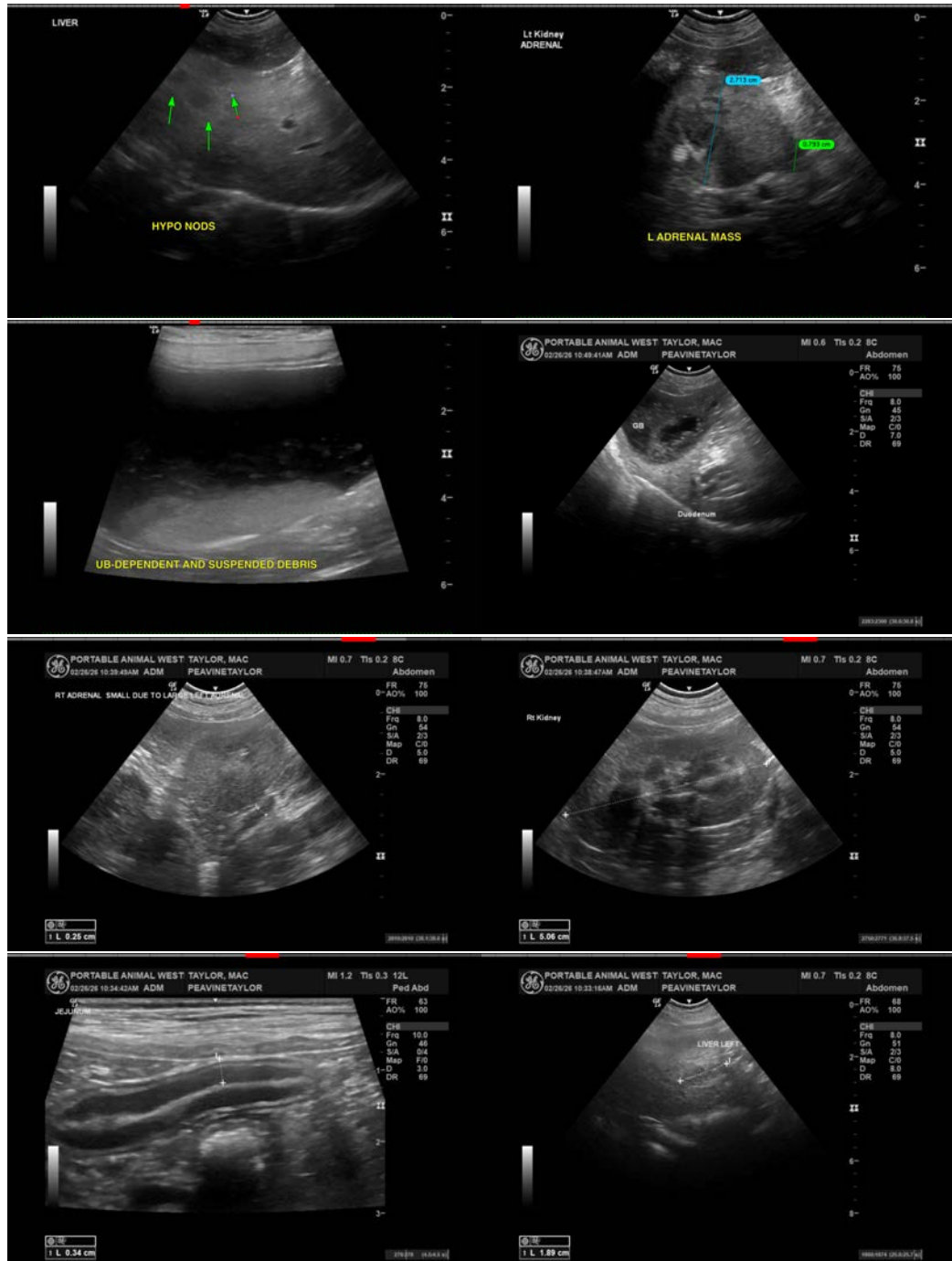
Dr. Morford

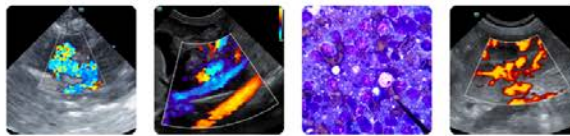
INVOICE

73319

DATE

2/26/26





PATIENT

Mac Taylor

SPECIES

Canine

BREED

Pug

SEX

Neutered Male

AGE

17 Years

WEIGHT

28 lbs

INTERPRETED BY

Kathleen Sennello DVM,
MS, Diplomate ACVIM
(Small Animal Internal
Medicine)

IMAGING PERFORMED BY

Loetitia Saint-Jacques,
LVT

HOSPITAL NAME

Peavine Animal
Hospital

REFERRING VET

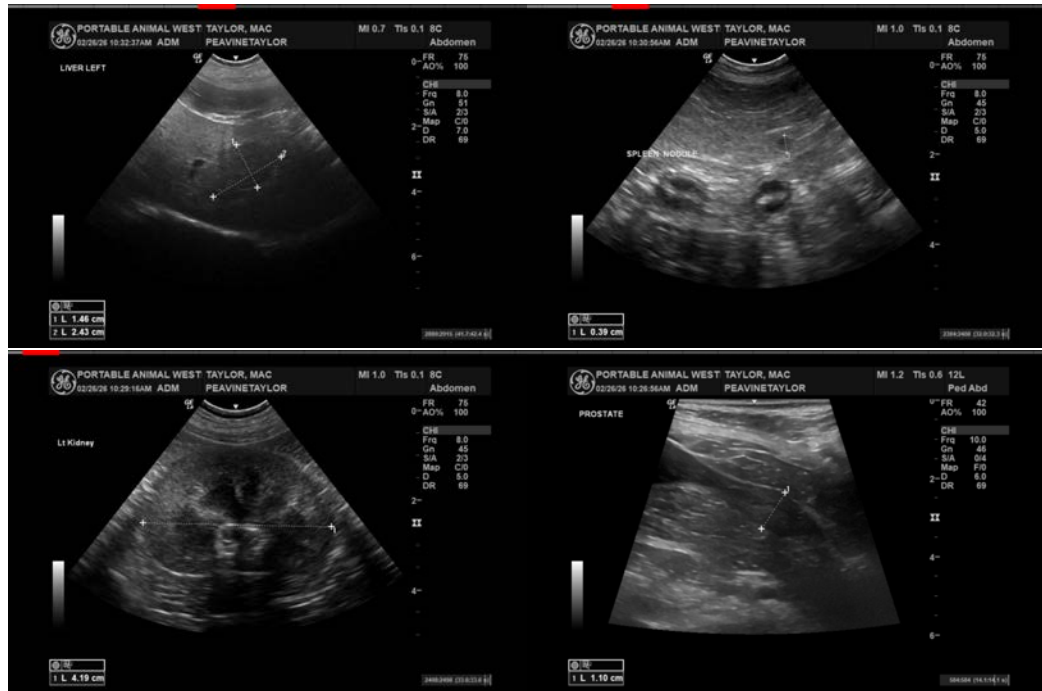
Dr. Morford

INVOICE

73319

DATE

2/26/26



The information and recommendations provided are based on the images presented by the referring veterinarian/sonographer. No evaluation can be communicated regarding pathology that was not visible in the image/video clips provided.

Thank you for this referral. If the clinical or image interpretation does not parallel your findings or if I can be of any further assistance please contact me.

Kathleen Sennello DVM,MS, Diplomate ACVIM (Small animal Internal Medicine)

info@sonopath.com