



PATIENT

Quinn Stoltzfus

SPECIES

Canine

BREED

Pitbull Mix

SEX

MN

AGE

11.5 years

WEIGHT

26 kg

INTERPRETED BY

Kathleen Sennello DVM,
MS, Diplomate ACVIM
(Small Animal Internal
Medicine)

IMAGING PERFORMED BY

Dr. Meghan Myers

HOSPITAL NAME

Hershey Animal
Emergency Center

REFERRING VET

Dr. Kim Davidson

INVOICE

11364

DATE

2/25/2026

PRESENTING CLINICAL SIGNS

- Defecating bloody sloughed intestine all over house this morning following anal glandectomy 2/11 with right sided anal gland adenocarcinoma.
- Oral Cavity: Mucous membranes pink/tacky, CRT <2s, mild tartar/gingival erythema, sublingual clear.
- Abdominal: Tense and uncomfortable on abdominal palpation. Pictures of hemorrhagic diarrhea with appearance of potential sloughing intestines vs. foreign material.
- Rectal: anal sacculotomy incision site healing well. Mild amount of dark red blood and mucous on glove. No other abnormalities on rectal exam and no observation of intestinal sloughing.

Abnormal PE/Chem/CBC/UA Results: CBC: lymphopenia (0.97) Chem: WNL EPOC: WNL cPL: WNL PCV/TP: 60/6.4.

ULTRASONOGRAPHIC EXAMINATION OF THE ABDOMEN

Urinary System

The urinary bladder is moderately distended with mild primarily suspended echogenic debris present. The Bladder wall, trigone, ureteral papillae and visible urethra (to a depth of 2cm) appear normal with no evidence of wall thickening, mucosal irregularities, masses or calculi. Echogenic debris of this type can be associated with small crystals, cellular debris and proteinaceous debris.

The visualized areas of prostate and surrounding tissue appear normal. Unfortunately, the prostate is not fully visualized likely due to its intrapelvic location. Correlate with rectal exam findings.

The left kidney has a normal shape and size (6.5 cm). Overall echogenicity is normal with adequate corticomedullary distinction and a typical 1:3 cortex:medulla ratio. There is no evidence of focal perinephric inflammation or effusion. There is no evidence of pyelectasia, nephroliths, infarcts or hydroureter. Renal vasculature is normal.

The right kidney has a normal shape and size (5.95 cm). Overall echogenicity is normal with adequate corticomedullary distinction and a typical 1:3 cortex:medulla ratio. There is no evidence of focal perinephric inflammation or effusion. There is no evidence of pyelectasia, nephroliths, infarcts or hydroureter. Renal vasculature is normal.

Adrenal Glands

The left adrenal gland is borderline plump in size measuring 0.67 cm at the cranial pole and 0.96 cm at the caudal pole. It is observed in its normal position cranial to the left renal artery. It is normal in appearance (uniformly hypoechoic) and shape with no evidence of a mass effect.

The right adrenal gland is normal in size measuring 0.7 cm at the cranial pole and 0.56 cm at the caudal pole. It is observed in its normal position between the cranial aspect of the right kidney and the caudal vena cava. It is normal in appearance (uniformly hypoechoic) and shape with no evidence of a mass effect.

Spleen



PATIENT

Quinn Stoltzfus

SPECIES

Canine

BREED

Pitbull Mix

SEX

MN

AGE

11.5 years

WEIGHT

26 kg

INTERPRETED BY

Kathleen Sennello DVM,
MS, Diplomate ACVIM
(Small Animal Internal
Medicine)

IMAGING PERFORMED BY

Dr. Meghan Myers

HOSPITAL NAME

Hershey Animal
Emergency Center

REFERRING VET

Dr. Kim Davidson

INVOICE

11364

DATE

2/25/2026

The spleen is subjectively normal in size (2.16 cm) and the echotexture is homogenous. The splenic capsule is smooth with no visible irregularities. The blood flow through the hilus and splenic parenchyma appears normal. There's a small hypoechoic nodule in the parenchyma measuring 0.89 cm.

Liver

The liver is normal in size, and normal in echogenicity with smooth peripheral margins. The parenchyma is mildly heterogenous in echotexture with subtle, indistinct focal mottling. The visible portions of the vasculature and biliary tract appear normal. There is a poorly defined, hyperechoic, slightly cystic lesion visualized in the parenchyma measuring 1.35 cm in diameter.

The gall bladder lumen is moderately distended. The wall of the gall bladder is not thickened and has a smooth mucosal surface. Luminal contents are mild and likely incidental at this time. The cystic and common bile ducts are normal/not visible.

Gastrointestinal

The stomach has moderate fluid distension. It measures at a normal thickness of <0.7cm with some variability due to the presence of rugal folds. The distinction of the gastric wall layers is adequate and there is no impression of reduced peristaltic activity. Fluid and gas distension of the stomach interferes with full evaluation of the stomach, and some areas of the cranial abdomen.

Some of the visualized areas of duodenum, jejunum and ileum have a relatively uniform diameter with moderate fluid distension. Wall thickness is normal. The duodenum measured as normal (0.54 cm in wall thickness) and the jejunum measured as normal (0.27 cm.) The majority of the small intestine appears mildly to moderately fluid distended with some areas (particularly the duodenum) exhibiting corrugation. Findings are suggestive of diffuse ileus and enteritis. Although a distal obstruction or partial obstruction cannot be definitively ruled out.

Sections of colon are visualized with non-formed fecal material and gas shadowing distally. There is no observed focal or generalized colon wall thickening or loss of layering.

Pancreas

The area of the pancreas is normal and isoechoic to surrounding mesentery. There is no evidence of nodules or cystic lesions. There is no evidence of regional mesenteric inflammation or fluid.

Free Abdomen

Evaluation of the peritoneal cavity did not reveal any evidence of effusion. There is no significant lymphadenopathy. A slightly prominent sub lumbar lymph node is visualized measuring 0.68 cm x 1.27 cm. The omentum is mildly diffusely hyperechoic.

ULTRASONOGRAPHIC FINDINGS

- Mild suspended echogenic debris in the urinary bladder. The echogenic debris in the bladder lumen could be consistent with cells, crystals, and/or mucus. Recommend urinalysis and culture.
- Small, hypoechoic nodule in the spleen. There is a non-cavitated, hypoechoic splenic nodule visualized. Differentials include lymphoid hyperplasia, extramedullary hematopoiesis,



PATIENT

Quinn Stoltzfus

SPECIES

Canine

BREED

Pitbull Mix

SEX

MN

AGE

11.5 years

WEIGHT

26 kg

INTERPRETED BY

Kathleen Sennello DVM,
MS, Diplomate ACVIM
(Small Animal Internal
Medicine)

IMAGING PERFORMED BY

Dr. Meghan Myers

HOSPITAL NAME

Hershey Animal
Emergency Center

REFERRING VET

Dr. Kim Davidson

INVOICE

11364

DATE

2/25/2026

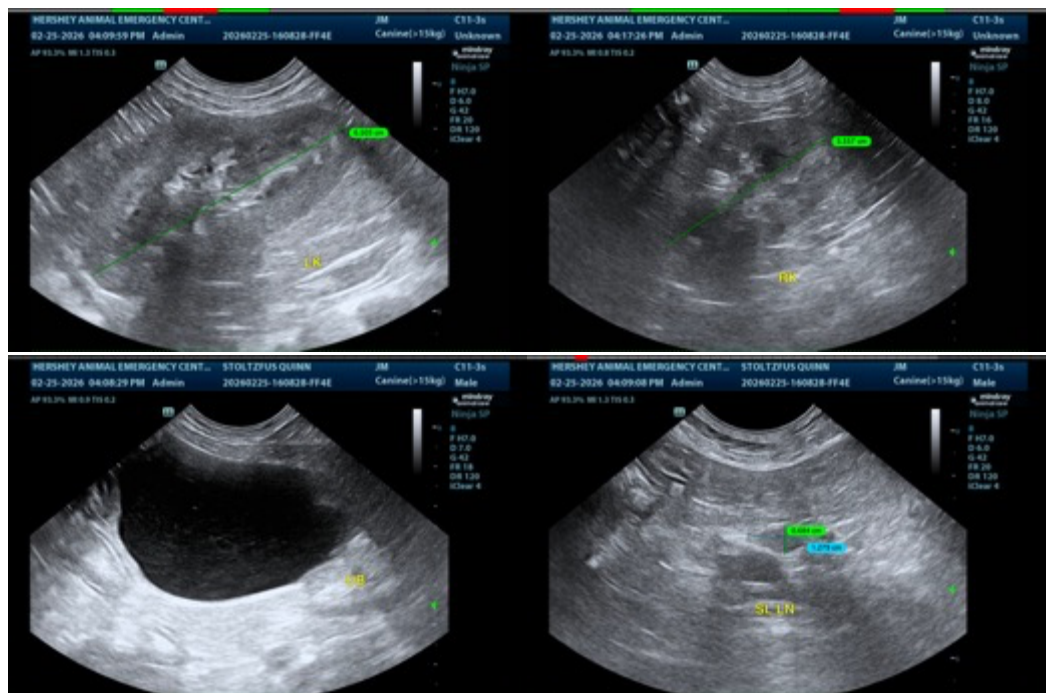
infiltrative neoplasia, inflammation, other. Cytology or histopathology would be necessary to get a definitive diagnosis.

- Poorly defined, hyperechoic liver lesion associated with a small cystic area. This generally has the appearance of a benign cystic lesion. Recommend continued monitoring.
- Fluid distended stomach, and small intestine. Correlate with the feeding history. If the patient was adequately fasted this likely represents diffuse ileus and gastroenterocolitis. A partially obstructive process cannot be definitively ruled out.
- Prominent sub lumbar lymph node. The appearance is most consistent with a reactive lymph node. A metastatic lymph node cannot be ruled out.

INTERPRETATION OF THE FINDINGS & FURTHER RECOMMENDATIONS

The stomach and small intestine appear significantly fluid distended with some areas exhibiting coregulation most consistent with an enteritis/inflammatory type pattern. Findings are suggestive of acute hemorrhagic gastroenterocolitis, although a small focal lesion or partially obstructive foreign material cannot be definitively ruled out. Recommend aggressive therapy for gastroenterocolitis with close monitoring. If symptoms are progressive despite therapy, you could consider repeat imaging in the future (radiographs +/- ultrasound) looking for the progression of today's lesions.

There's a small hypoechoic nodule in the spleen. Options moving forward include continued monitoring with ultrasound or a fine needle aspirate. Similarly, there's a poorly defined, slightly cystic, hyperechoic lesion in the liver. The appearance favors a benign lesion, but continued monitoring is recommended. If clinically appropriate, consider screening for infectious causes of diarrhea.





PATIENT

Quinn Stoltzfus

SPECIES

Canine

BREED

Pitbull Mix

SEX

MN

AGE

11.5 years

WEIGHT

26 kg

INTERPRETED BY

Kathleen Sennello DVM,
MS, Diplomate ACVIM
(Small Animal Internal
Medicine)

IMAGING PERFORMED BY

Dr. Meghan Myers

HOSPITAL NAME

Hershey Animal
Emergency Center

REFERRING VET

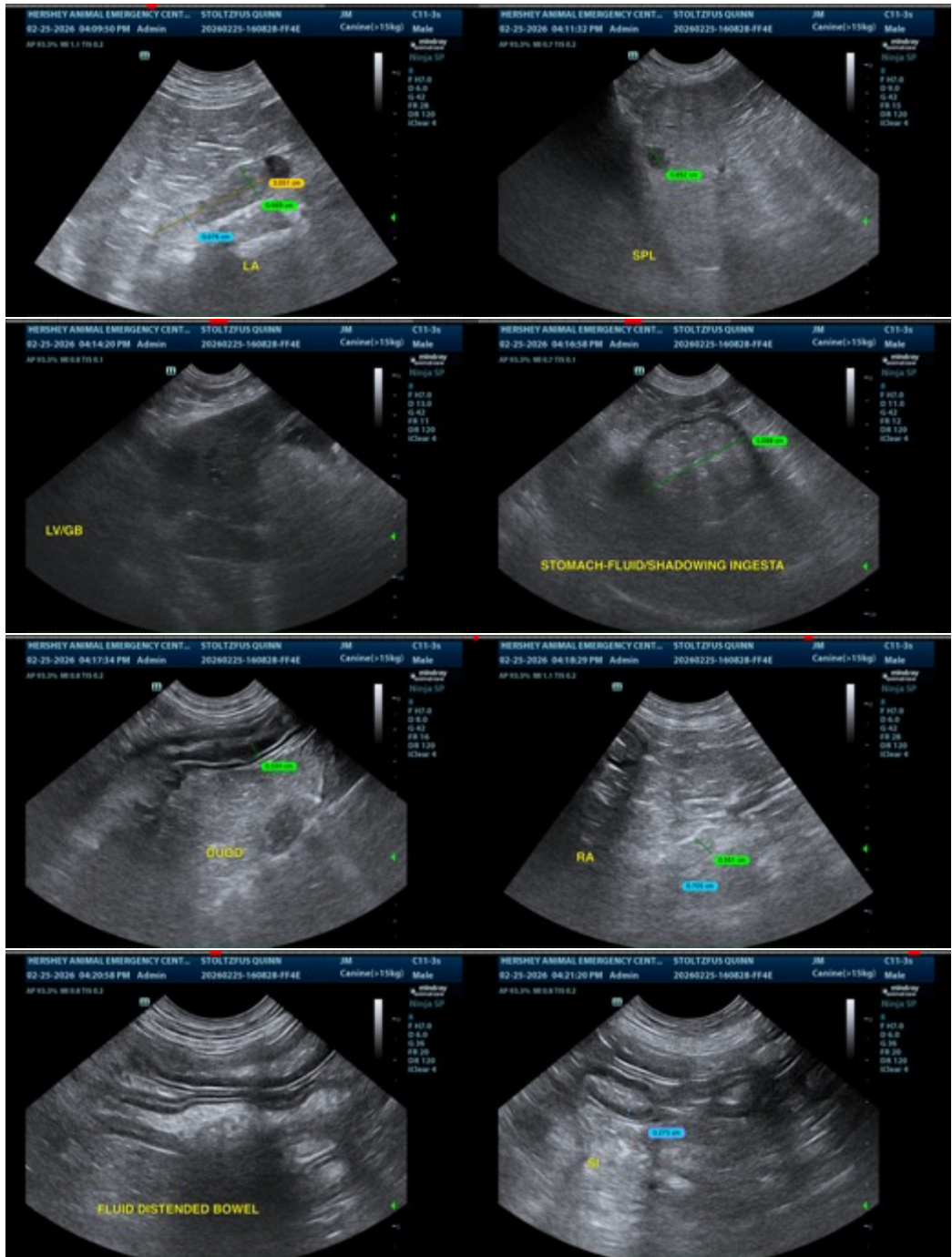
Dr. Kim Davidson

INVOICE

11364

DATE

2/25/2026





PATIENT

Quinn Stoltzfus

SPECIES

Canine

BREED

Pitbull Mix

SEX

MN

AGE

11.5 years

WEIGHT

26 kg

INTERPRETED BY

Kathleen Sennello DVM,
MS, Diplomate ACVIM
(Small Animal Internal
Medicine)

IMAGING PERFORMED BY

Dr. Meghan Myers

HOSPITAL NAME

Hershey Animal
Emergency Center

REFERRING VET

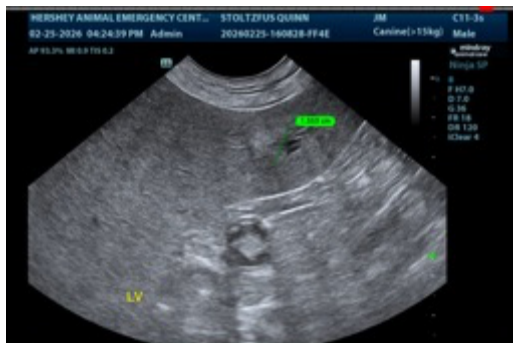Dr. Kim Davidson

INVOICE

11364

DATE

2/25/2026



The information and recommendations provided are based on the images presented by the referring veterinarian/sonographer. No evaluation can be communicated regarding pathology that was not visible in the image/video clips provided.

Thank you for this referral. If the clinical or image interpretation does not parallel your findings or if I can be of any further assistance please contact me.

Kathleen Sennello DVM,MS, Diplomate ACVIM (Small animal Internal Medicine)

info@sonopath.com