



**PATIENT**

Kiwi Hayes

**SPECIES**

Feline

**BREED**

DSH

**SEX**

Neutered Male

**AGE**

11 Years

**WEIGHT**

15 lbs

**INTERPRETED BY**

Kathleen Sennello DVM,  
MS, Diplomate ACVIM  
(Small Animal Internal  
Medicine)

**IMAGING PERFORMED BY**

Rebecca Hamilton

**HOSPITAL NAME**

Blairstown Animal  
Hospital

**REFERRING VET**

Dr. Clegg

**INVOICE**

73251

**DATE**

2/25/26

**PRESENTING CLINICAL SIGNS**

Lethargy, poor appetite. Weight loss. Meds: Gabapentin, Cerenia, Mirataz

Abnormal PE/Chem/CBC/UA Results: Eosinophilia 1519, USG 1.059

**ULTRASONOGRAPHIC EXAMINATION OF THE ABDOMEN**

**Urinary System**

The urinary bladder is moderately distended with moderate primarily suspended echogenic debris present. The Bladder wall, trigone, ureteral papillae and visible urethra (to a depth of 2cm) appear normal with no evidence of wall thickening, mucosal irregularities, masses or calculi. Echogenic debris of this type can be associated with small crystals, cellular debris and proteinaceous debris.

The left kidney has a normal shape and size (4.46 cm). Overall echogenicity is normal with adequate corticomedullary distinction and a typical 1:3 cortex:medulla ratio. There is no evidence of focal perinephric inflammation or effusion. There is no evidence of pyelectasia, nephroliths, infarcts or hydroureter. Renal vasculature is normal.

The right kidney has a normal shape and size (4.56 cm). Overall echogenicity is normal with adequate corticomedullary distinction and a typical 1:3 cortex:medulla ratio. There is no evidence of focal perinephric inflammation or effusion. There is no evidence of pyelectasia, nephroliths, infarcts or hydroureter. Renal vasculature is normal.

**Adrenal Glands**

The left adrenal gland is normal in size measuring 0.41 cm at the caudal pole. It is observed in its normal position cranial to the left renal artery. It is normal in appearance (uniformly hypoechoic) and shape with no evidence of a mass effect.

The right adrenal gland is normal in size measuring 0.33 cm at the caudal pole. It is observed in its normal position between the cranial aspect of the right kidney and the caudal vena cava. It is normal in appearance (uniformly hypoechoic) and shape with no evidence of a mass effect.

**Spleen**

The spleen is subjectively normal in size (0.81 cm), echotexture is homogenous, and the splenic capsule is smooth with no irregularities. The blood flow through the hilus and splenic parenchyma appears normal. No focal parenchymal abnormalities are visualized.

**Liver**

The liver is subjectively normal in size, and echogenicity with smooth peripheral margins. The parenchyma is homogenous echotexture. The visible portions of the vasculature and biliary tract appear normal. No focal nodules or cystic lesions are observed.

The gall bladder lumen is moderately distended. The wall of the gall bladder is not thickened and has a smooth mucosal surface. Luminal contents are mild and likely incidental at this time. The cystic and common bile ducts are normal/not visible.



**PATIENT**

Kiwi Hayes

**SPECIES**

Feline

**BREED**

DSH

**SEX**

Neutered Male

**AGE**

11 Years

**WEIGHT**

15 lbs

**INTERPRETED BY**

Kathleen Sennello DVM,  
MS, Diplomate ACVIM  
(Small Animal Internal  
Medicine)

**IMAGING PERFORMED BY**

Rebecca Hamilton

**HOSPITAL NAME**

Blairstown Animal  
Hospital

**REFERRING VET**

Dr. Clegg

**INVOICE**

73251

**DATE**

2/25/26

***Gastrointestinal***

The stomach contains minimal luminal contents. It measures at a normal thickness of <0.36cm with some variability due to the presence of rugal folds. The distinction of the gastric wall layers is adequate and there is no impression of reduced peristaltic activity. No masses or focal lesions were observed.

The visualized areas of duodenum, jejunum and ileum have a uniform diameter with minimal fluid distension. Wall thickness is normal to slightly increased. Bowel loops follow a typical curvilinear path with distinct wall layering, but some areas display a prominent muscularis layer which does not display the typical 1:3 muscularis:mucosa layer ratio. Jejunum wall measures 0.26 cm. Visualized peristalsis appears appropriate.

There is a large, poorly delineated, hypoechoic mass effect visualized in the region of the ileocecal junction measuring 3.87 cm x 4.48 cm. The bowel wall in this region is severely thickened, measuring at 0.71 cm. The ascending colon is associated with this mass lesion with a thickened wall measuring at 0.42 cm. The descending colon appears normal with intact wall layering.

***Pancreas***

The pancreas is large and hypoechoic to surrounding mesentery. There is no evidence of nodules or cystic lesions. There is evidence of regional mesenteric inflammation. Consistent with mild pancreatitis.

***Free Abdomen***

There is a moderate amount of echogenic free abdominal fluid. There are occasional mildly prominent mesenteric lymph nodes. An example measures 0.35 cm. The omentum is diffusely hyperechoic, particularly around the cranial abdominal mass lesion and the pancreas.

**ULTRASONOGRAPHIC FINDINGS**

- Moderate suspended echogenic debris in the urinary bladder – The echogenic debris in the bladder lumen could be consistent with cells, crystals, and/or mucus.
- Pancreatic changes in both limbs, most consistent with mild pancreatitis.
- Large, irregular, poorly defined, hypoechoic cranial abdominal mass lesion that appears to involve the ileocecal junction – Findings are concerning for a neoplastic lesion such as round cell neoplasia, carcinoma, other.
- Moderate echogenic free abdominal fluid – Findings are concerning for a neoplastic effusion. Recommend fluid analysis and cytology.
- Mildly thickened/ropey small intestine – Findings are most consistent with inflammatory type change, although early neoplastic change cannot be ruled out.

**INTERPRETATION OF THE FINDINGS & FURTHER RECOMMENDATIONS**

There is a large mass effect in the right cranial abdomen, which appears to be involving the ileocecal junction. The appearance is most consistent with a neoplastic lesion. Consider a fine needle aspirate of this mass effect for cytologic evaluation. Additionally, there is a moderate amount of echogenic free abdominal fluid. The appearance is concerning for either highly inflammatory or neoplastic effusion. Recommend fluid analysis and cytology for further evaluation.



**PATIENT**

Kiwi Hayes

**SPECIES**

Feline

**BREED**

DSH

**SEX**

Neutered Male

**AGE**

11 Years

**WEIGHT**

15 lbs

**INTERPRETED BY**

Kathleen Sennello DVM,  
 MS, Diplomate ACVIM  
 (Small Animal Internal  
 Medicine)

**IMAGING  
 PERFORMED BY**

Rebecca Hamilton

**HOSPITAL NAME**

Blairstown Animal  
 Hospital

**REFERRING VET**

Dr. Clegg

**INVOICE**

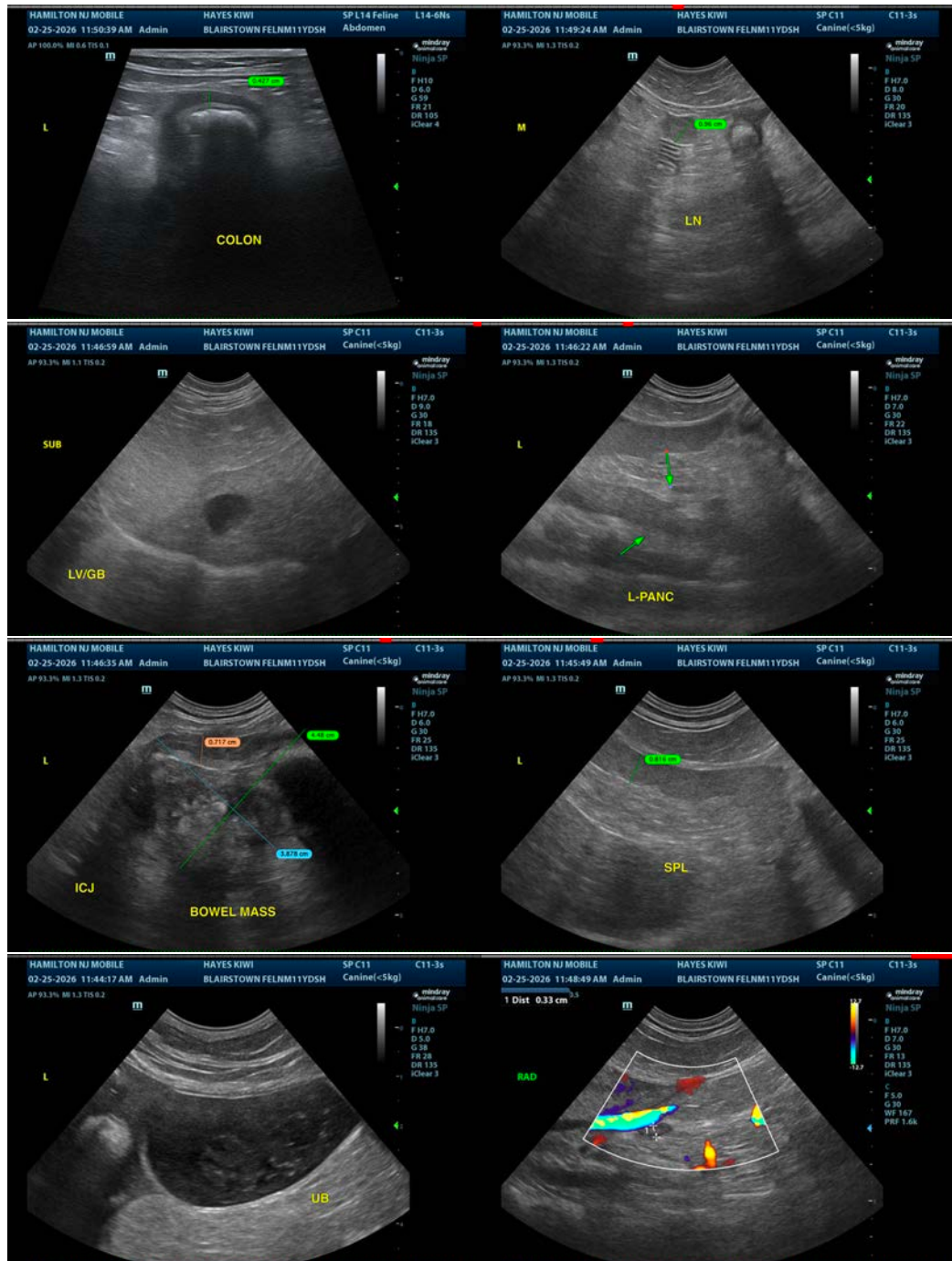
73251

**DATE**

2/25/26

Both limbs of the pancreas are prominent and hypoechoic. Some of this may be related to inflammation surrounding the mass effect. Recommend concurrent treatment for pancreatitis.

Recommend three view thoracic radiographs to evaluate for possible concurrent thoracic disease/involvement (disregard if this has already been done).





**PATIENT**

Kiwi Hayes

**SPECIES**

Feline

**BREED**

DSH

**SEX**

Neutered Male

**AGE**

11 Years

**WEIGHT**

15 lbs

**INTERPRETED BY**

Kathleen Sennello DVM,  
 MS, Diplomate ACVIM  
 (Small Animal Internal  
 Medicine)

**IMAGING  
 PERFORMED BY**

Rebecca Hamilton

**HOSPITAL NAME**

Blairstown Animal  
 Hospital

**REFERRING VET**

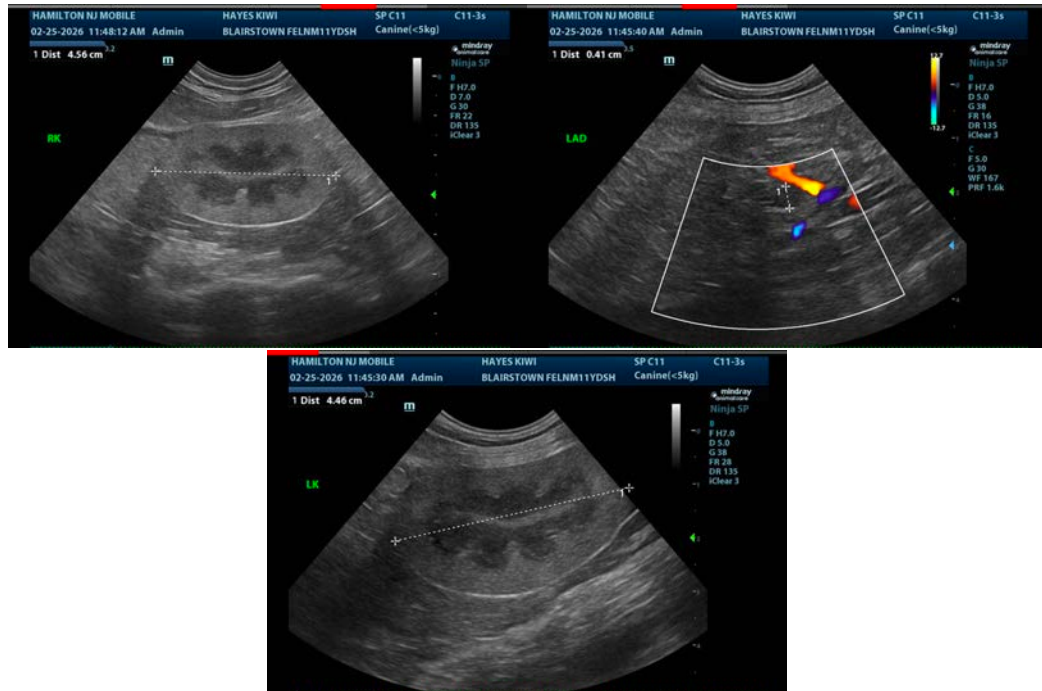
Dr. Clegg

**INVOICE**

73251

**DATE**

2/25/26



The information and recommendations provided are based on the images presented by the referring veterinarian/sonographer. No evaluation can be communicated regarding pathology that was not visible in the image/video clips provided.

Thank you for this referral. If the clinical or image interpretation does not parallel your findings or if I can be of any further assistance please contact me.

Kathleen Sennello DVM,MS, Diplomate ACVIM (Small animal Internal Medicine)

info@sonopath.com