



PATIENT

Dawson McCracken

SPECIES

Canine

BREED

Dachshund

SEX

MN

AGE

12.3 years

WEIGHT

17.3 lbs

INTERPRETED BY

Kathleen Sennello DVM,
MS, Diplomate ACVIM
(Small Animal Internal
Medicine)

IMAGING PERFORMED BY

Dr. Emily Kirk

HOSPITAL NAME

Shiloh Animal Hospital

REFERRING VET

Dr. Emily Kirk

INVOICE

11372

DATE

2/25/2026

PRESENTING CLINICAL SIGNS

- Acute on chronic GI signs. Symptoms have been waxing and waning for a couple of months.
- Recently vomited a large amount two days ago. Has been lethargic since. Developed watery diarrhea today.
- Recent lab work showed mild elevations in ALT and ALP. A cPL was wnl. Labs are being rechecked today

Abnormal PE/Chem/CBC/UA Results: Physical exam- slight dehydration, lethargy, no appreciable abdominal pain.

ULTRASONOGRAPHIC EXAMINATION OF THE ABDOMEN

Urinary System

The urinary bladder is moderately distended with anechoic urine. The Bladder wall, trigone, ureteral papillae and visible urethra (to a depth of 2cm) appear normal with no evidence of wall thickening, mucosal irregularities, masses or cystic calculi.

The visualized areas of prostate and surrounding tissue appear normal. Unfortunately, the prostate is not fully visualized likely due to its intrapelvic location. Correlate with rectal exam findings.

The left kidney has a normal shape and size (4.73 cm). Overall echogenicity is slightly hyperechoic with poor corticomedullary distinction and a typical 1:3 cortex:medulla ratio. There is no evidence of focal perinephric inflammation or effusion. Numerous pinpoint non-obstructive nephroliths are noted. There is no evidence of pyelectasia, infarcts or hydroureter. Renal vasculature is normal.

The right kidney has a normal shape and size (4.33 cm). Overall echogenicity is slightly hyperechoic with poor corticomedullary distinction and a typical 1:3 cortex:medulla ratio. There is no evidence of focal perinephric inflammation or effusion. Numerous pinpoint non-obstructive nephroliths are noted. There is no evidence of pyelectasia, infarcts or hydroureter. Renal vasculature is normal.

Adrenal Glands

The left adrenal gland is normal in size measuring 0.47 cm at the cranial pole and 0.4 cm at the caudal pole. It is observed in its normal position cranial to the left renal artery. It is normal in appearance (uniformly hypoechoic) and shape with no evidence of a mass effect.

The right adrenal gland is normal in size measuring 0.45 cm at the cranial pole and 0.47 cm at the caudal pole. It is observed in its normal position between the cranial aspect of the right kidney and the caudal vena cava. It is normal in appearance (uniformly hypoechoic) and shape with no evidence of a mass effect.

Spleen

The spleen is subjectively normal in size (1.1 cm in width at the level of the hilus) and the echotexture is homogenous. The splenic capsule is smooth with no visible irregularities. The blood flow through the hilus and splenic parenchyma appears normal. There's poorly defined hyperechoic tissue towards the margins, most consistent with myelolipoma like tissue.

Liver



PATIENT

Dawson McCracken

SPECIES

Canine

BREED

Dachshund

SEX

MN

AGE

12.3 years

WEIGHT

17.3 lbs

INTERPRETED BY

Kathleen Sennello DVM,
MS, Diplomate ACVIM
(Small Animal Internal
Medicine)

IMAGING PERFORMED BY

Dr. Emily Kirk

HOSPITAL NAME

Shiloh Animal Hospital

REFERRING VET

Dr. Emily Kirk

INVOICE

11372

DATE

2/25/2026

The liver is large in size, and normal in echogenicity with smooth peripheral margins. The parenchyma is heterogenous in echotexture with subtle, indistinct focal mottling. The visible portions of the vasculature and biliary tract appear normal. There's a hypoechoic nodule in the left side of the liver measuring 0.8 cm x 0.66 cm.

The gall bladder lumen is moderately distended. The wall of the gall bladder is not thickened and has a smooth mucosal surface. Luminal contents are mild and likely incidental at this time. The cystic and common bile ducts are normal/not visible.

Gastrointestinal

The stomach is moderately dilated with fluid and irregular shadowing material most consistent with large ingesta and gas. It measures at a normal thickness of <0.7cm with some variability due to the presence of rugal folds. The distinction of the gastric wall layering is adequate and there is no impression of reduced peristaltic activity. Shadowing material could be consistent with retained ingesta, foreign material etc..

Most of the visualized areas of duodenum, jejunum and ileum have a relatively uniform diameter with minimal to moderate fluid distension. Wall thickness is normal. Bowel loops follow a curvilinear path with distinct wall layering maintaining the typical 1:3 muscularis:mucosa layer ratio. The duodenum measured as normal (0.43 cm in wall thickness) and the jejunum measured as normal (0.35 cm.) The majority of the small bowel appears relatively normal, although some sections subjectively appear somewhat hypomotile and some areas have mild fluid and gas distension.

The descending colon appears significantly fluid distended with a prominent/mildly thickened wall measuring 0.23 cm with intact wall layering.

Pancreas

The pancreas is large and hypoechoic to surrounding mesentery. There is no evidence of nodules or cystic lesions. There is evidence of regional mesenteric inflammation. Consistent with mild pancreatitis in both limbs

Free Abdomen

Evaluation of the peritoneal cavity did not reveal any evidence of effusion. There is no significant lymphadenopathy. The omentum is highly reactive around some loops of bowel and in the cranial abdomen in the region of the pancreas.

PRIMARY FINDINGS

- Pancreatic changes consistent with mild/moderate pancreatitis.
- Large, heterogenous liver with a hypoechoic nodule. The diffuse hepatic changes are non-specific and could be consistent with vacuolar hepatopathy, nodular hyperplasia, inflammatory/immune-mediated disease, infiltrative neoplasia (less likely) or other hepatopathy. The hypoechoic nodule could represent a benign or neoplastic lesion.
- Large, shadowing ingesta visualized within the gastric lumen. This could represent delayed gastric emptying, ingested foreign material or a partial outflow tract obstruction (none seen at the level of the pylorus.)
- Mild segmental ileus and fluid distension of the small intestine. Findings are most consistent with an enteritis type pattern. No focal lesions are visualized.



PATIENT

Dawson McCracken

SPECIES

Canine

BREED

Dachshund

SEX

MN

AGE

12.3 years

WEIGHT

17.3 lbs

- Mildly thickened fluid distended colon. Findings are most consistent with colitis type changes. A neoplastic process is thought less likely.

SECONDARY FINDINGS

- Age related changes, and non-obstructive nephroliths visualized associated with both kidneys.

INTERPRETATION OF THE FINDINGS & FURTHER RECOMMENDATIONS

The colon is significantly fluid distended, and the colon wall is slightly thickened with intact wall layering. Generally, the small intestinal changes are less prominent with questionable decrease in motility and some mild segmental fluid distension. Additionally, the stomach is significantly distended with fluid and shadowing ingesta. This could represent retained ingesta, ingested foreign material or delayed gastric emptying.

There's significant focal inflammation in the abdomen. This appears to be centered around the cranial abdomen and some sections of bowel. This is the region of the pancreas, which is slightly prominent, possibly consistent with active pancreatitis. Recommend aggressive treatment for hemorrhagic gastroenterocolitis. Additionally, you could consider testing for infectious causes of colitis. If the patient is not responding to therapy consider repeat imaging looking to evaluate if the stomach is emptying and if a more focal lesion is observed as a partial obstruction or similar cannot be definitively ruled out.

If symptoms are persistent, ultimately biopsies of the GI tract may be warranted to further evaluate.

INTERPRETED BY

Kathleen Sennello DVM,
MS, Diplomate ACVIM
(Small Animal Internal
Medicine)

IMAGING PERFORMED BY

Dr. Emily Kirk

HOSPITAL NAME

Shiloh Animal Hospital

REFERRING VET

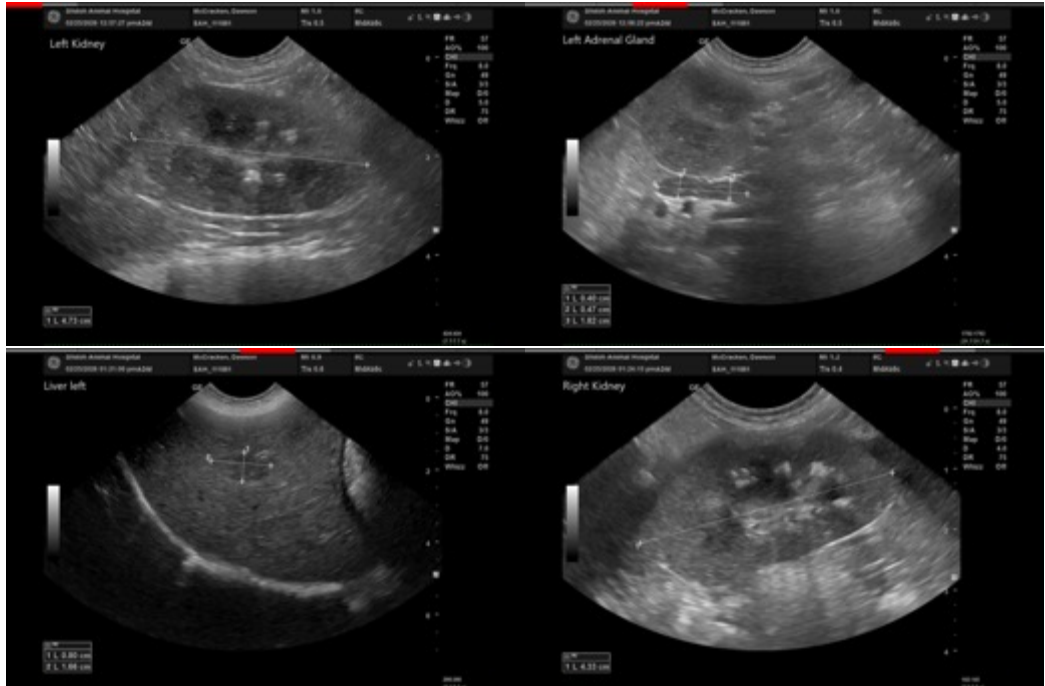
Dr. Emily Kirk

INVOICE

11372

DATE

2/25/2026





PATIENT

Dawson McCracken

SPECIES

Canine

BREED

Dachshund

SEX

MN

AGE

12.3 years

WEIGHT

17.3 lbs

INTERPRETED BY

Kathleen Sennello DVM,
MS, Diplomate ACVIM
(Small Animal Internal
Medicine)

IMAGING PERFORMED BY

Dr. Emily Kirk

HOSPITAL NAME

Shiloh Animal Hospital

REFERRING VET

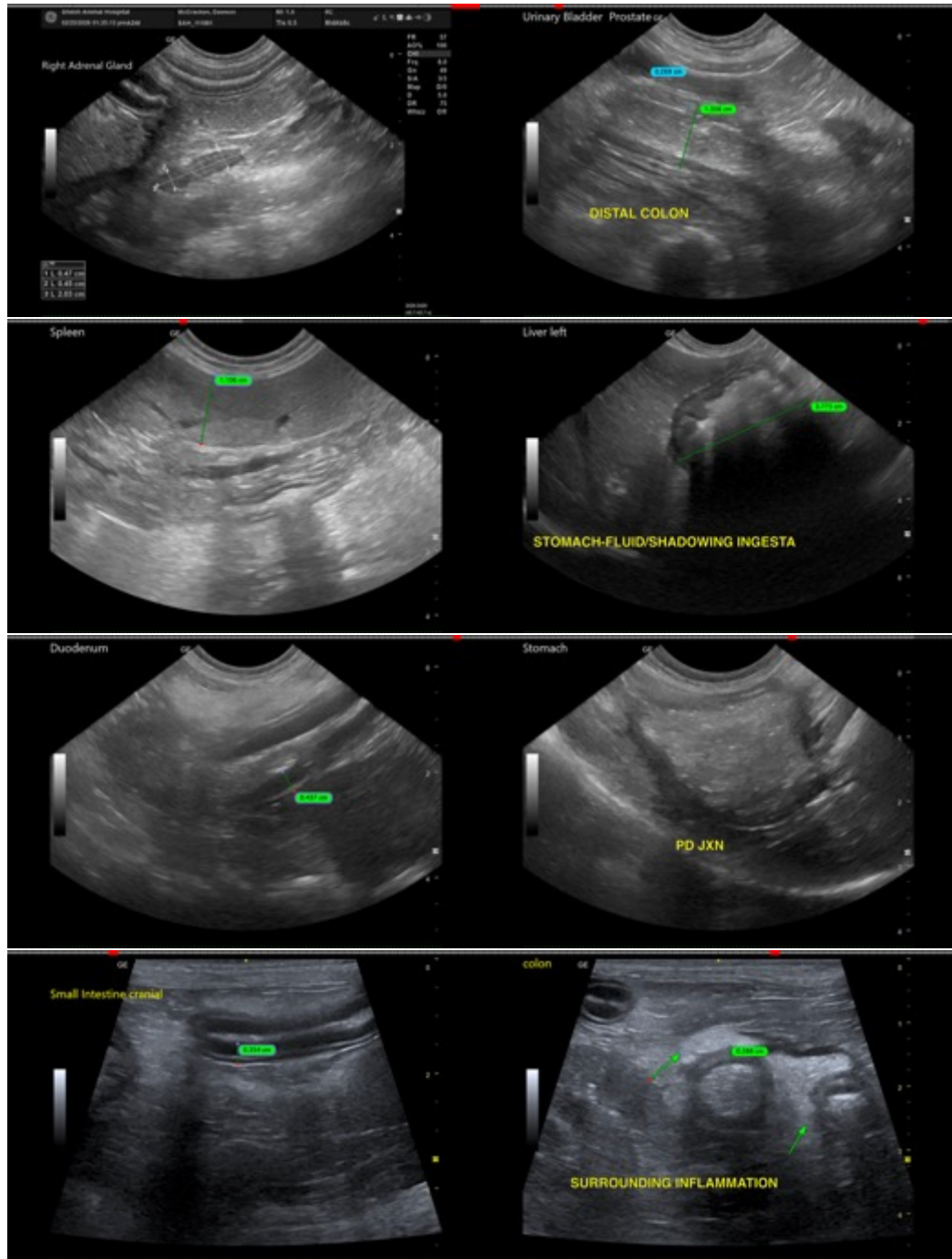
Dr. Emily Kirk

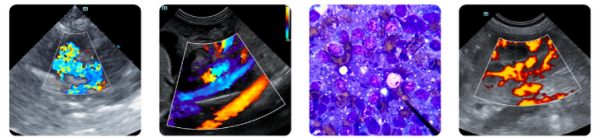
INVOICE

11372

DATE

2/25/2026





PATIENT

Dawson McCracken

SPECIES

Canine

BREED

Dachshund

SEX

MN

AGE

12.3 years

WEIGHT

17.3 lbs

INTERPRETED BY

Kathleen Sennello DVM,
MS, Diplomate ACVIM
(Small Animal Internal
Medicine)

IMAGING PERFORMED BY

Dr. Emily Kirk

HOSPITAL NAME

Shiloh Animal Hospital

REFERRING VET

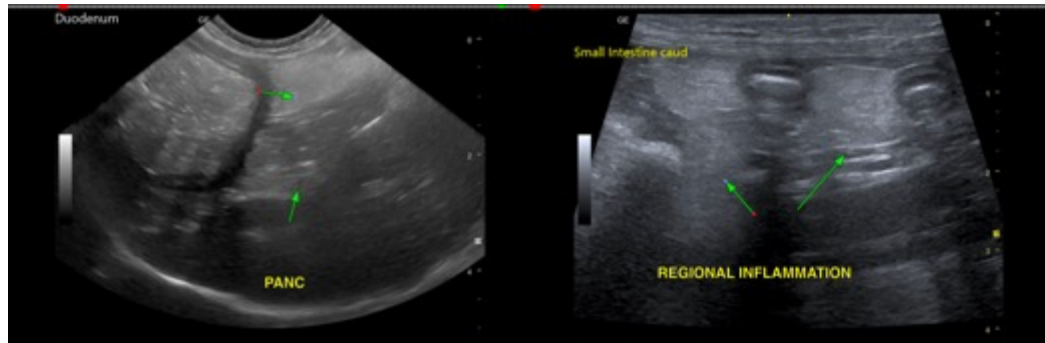
Dr. Emily Kirk

INVOICE

11372

DATE

2/25/2026



The information and recommendations provided are based on the images presented by the referring veterinarian/sonographer. No evaluation can be communicated regarding pathology that was not visible in the image/video clips provided.

Thank you for this referral. If the clinical or image interpretation does not parallel your findings or if I can be of any further assistance please contact me.

Kathleen Sennello DVM,MS, Diplomate ACVIM (Small animal Internal Medicine)

info@sonopath.com