

IMAGING PERFORMED BY

IntraPet.com



**SonoPath**

Clinical Sonography & Telemetry

EDUCATIONAL TELECONSULTATION SERVICES™

1-800-838-4268 info@sonopath.com SonoPath.com

**DATE PRESENTING CLINICAL SIGNS**

2/25/22 Intermittent vomiting. Improves with Cerenia. Currently on Low dose Prednisolone- mild improvement but still having intermittent vomiting.

**PATIENT**

Scotch Skehan Current Medications: Cerenia course. Prednisolone 5mg SID for 2 weeks then 2.5mg SID.  
Lab Results: See attached.

**SPECIES**

Feline

Date of Previous IntraPet Ultrasound: No previous.  
Sedation: Patient sedated with Torbugesic and Dexdomitor.  
Stat Report: Not requested.

**ULTRASONOGRAPHIC EXAMINATION OF THE ABDOMEN**

**BREED**

DSH

**Urinary System**

The urinary bladder is moderately distended with anechoic urine. The Bladder wall, trigone, ureteral papillae and visible urethra (to a depth of 2cm) appear normal with no evidence of wall thickening, mucosal irregularities, masses or cystic calculi.

**SEX**

Spayed Female

The left kidney has a normal shape and size (3.24 cm). Overall echogenicity is normal with adequate corticomedullary distinction and a typical 1:3 cortex:medulla ratio. There is no evidence of perinephric inflammation or effusion. There is no evidence of pyelectasia, nephroliths, infarcts or hydroureter. Renal vasculature is normal.

**AGE**

9/1/09

The right kidney has a normal shape and size (3.23 cm). Overall echogenicity is normal with adequate corticomedullary distinction and a typical 1:3 cortex:medulla ratio. There is no evidence of perinephric inflammation or effusion. There is no evidence of pyelectasia, nephroliths, infarcts or hydroureter. Renal vasculature is normal.

**WEIGHT**

10.3 Pounds

**INTERPRETED BY**

Kathleen Sennello DVM,  
MS, Diplomate ACVIM  
(Small Animal Internal  
Medicine)

**Adrenal Glands**

The left adrenal gland is normal in size measuring 0.40 cm at the caudal pole. It is observed in its normal position cranial to the left renal artery. It is normal in appearance (uniformly hypoechoic) and shape with no evidence of a mass effect.

**IMAGING PERFORMED BY**

Andi Parkinson RDMS

The region of the right adrenal (between right cranial kidney and vena cava) is unremarkable, but the adrenal is not distinctly visualized. No evidence of a mass effect.

**HOSPITAL NAME**

Timonium AH

**Spleen**

The spleen is subjectively normal in size, echotexture is homogenous, and the splenic capsule is smooth with no irregularities. The blood flow through the hilus and splenic parenchyma appears normal. No focal parenchymal abnormalities are visualized.

**REFERRING VET**

Dr. McMichael

**Liver**

The liver is subjectively normal in size, and echogenicity with smooth peripheral margins. The parenchyma is homogenous echotexture. The visible portions of the vasculature and biliary tract appear normal. No focal nodules or cystic lesions are observed.

**INVOICE**

35913

The gallbladder lumen is moderately distended. The wall of the gall bladder is not thickened and has a smooth mucosal surface. Luminal contents are primarily anechoic. The bile duct is visualized and appears somewhat tortuous and prominent, measuring 0.27 cm. No evidence of an obstruction is noted.

### ***Gastrointestinal***

The stomach contains minimal luminal contents. It measures at a normal thickness of <0.36cm with some variability due to the presence of rugal folds. The distinction of the gastric wall layers is adequate and there is no impression of reduced peristaltic activity. No masses or focal lesions were observed.

The visualized areas of duodenum, jejunum and ileum have a relatively uniform diameter with minimal fluid distension. Wall thickness is normal. Bowel loops follow a curvilinear path with distinct wall layering maintaining the typical 1:3 muscularis:mucosa layer ratio. The duodenum measured as normal (between 0.13-0.38cm in wall thickness) and the jejunum measured as normal (between 0.15-0.36cm.) Jejunum wall measured 0.20 cm. Visualized peristalsis appears appropriate. There were no focal lesions consistent with obstruction or a mass effect observed.

The ileocecal junction was visualized and exhibited normal intact wall layering and is subjectively of normal thickness. Sections of colon are visualized with formed fecal material and gas shadowing distally. There is no observed focal or generalized colon wall thickening or loss of layering.

### ***Pancreas***

The pancreas is prominent and hypoechoic as compared to the surrounding isoechoic mesentery. There is no evidence of nodules or cystic lesions. There is no evidence of regional mesenteric inflammation or fluid.

### ***Free Abdomen***

Evaluation of the peritoneal cavity did not reveal any evidence of effusion, or subjective lymphadenomegaly. The Medial iliac nodes appear normal and there was no evidence of a caudal aortic thrombus at the bifurcation. The omentum is of normal uniform echogenicity.

## **PRIMARY FINDINGS**

- Prominent, hypoechoic pancreas – The pancreatic changes are most consistent with mild pancreatitis or a recent episode of pancreatic inflammation.

## **SECONDARY FINDINGS**

- Mildly prominent and tortuous bile duct – Dilation of the common bile duct could be consistent with a functional obstruction (i.e. primary hepatic disease resulting in hepatocellular swelling) or with an extrahepatic bile duct obstruction (ie. choledocholith, bile duct tumor, pancreatic disease, other). No obstruction is noted, and the dilation is relatively mild.

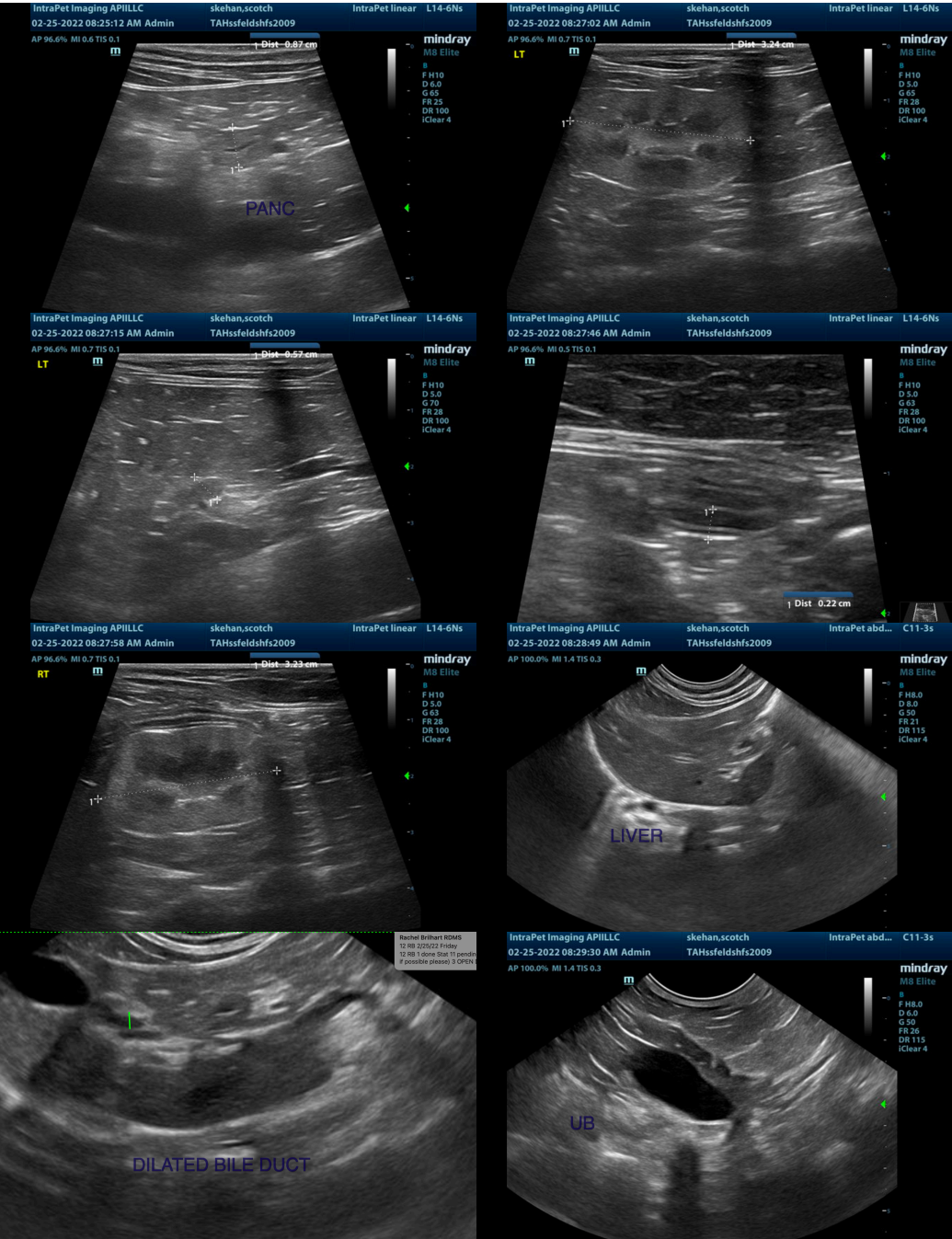
## **INTERPRETATION OF THE FINDINGS & FURTHER RECOMMENDATIONS**

No prominent focal lesions are observed on today's scan. The pancreas is prominent and hypoechoic. There is no significant inflammation visualized surrounding the pancreas, so the significance of this is unclear.

Provided metabolic disease has been ruled out (normal blood work, normal thyroid evaluation, etc.), then primary GI disease would be the most likely cause for the vomiting. Consider such differentials as dietary intolerance/food allergy, GI parasites, pancreatitis, IBD, and less likely intestinal neoplasia.

- Recommend hydrolyzed protein/novel protein diet.
- Consider chronic probiotic therapy.
- Recommend GI panel to Texas A&M with qualitative fPLI, TLI, cobalamin and folate to further evaluate the pancreas and small intestine. If symptoms persist, I would recommend tapering off of the Prednisone or to the lowest dose possible and obtaining GI biopsies.

- Consider three view thoracic radiographs to rule out concurrent thoracic disease/involvement.



**The information and recommendations provided are based on the images presented by the referring veterinarian/sonographer. No evaluation can be communicated regarding pathology that was not visible in the image/video clips provided.**

Thank you for this referral. If the clinical or image interpretation does not parallel your findings or if I can be of any further assistance please contact me.

Kathleen Sennello DVM,MS, Diplomate ACVIM (Small animal Internal Medicine)  
kathleen.sennello@sonopath.com