



**PATIENT**

Indy Harris

**SPECIES**

Canine

**BREED**

Miniature Australian Shepherd

**SEX**

Intact Male

**AGE**

5 Years

**WEIGHT**

9.7 lbs

**INTERPRETED BY**

Kathleen Sennello DVM,  
MS, Diplomate ACVIM  
(Small Animal Internal  
Medicine)

**IMAGING PERFORMED BY**

Meghan Morse, LVT,  
CVT

**HOSPITAL NAME**

Walden Animal Clinic

**REFERRING VET**

Dr. Kelly

**INVOICE**

73218

**DATE**

2/24/26

**PRESENTING CLINICAL SIGNS**

Presurgical testing (high ALP). Needs dental (fractured carnassial tooth). Current meds: Clavamox, Metacam. Abnormal PE/Chem/CBC/UA Results: ALP 1079, WBC 23.9, increased Neuts

**ULTRASONOGRAPHIC EXAMINATION OF THE ABDOMEN**

**Urinary System**

The urinary bladder is moderately distended with anechoic urine. The Bladder wall, trigone, ureteral papillae and visible urethra (to a depth of 2cm) appear normal with no evidence of wall thickening, mucosal irregularities, masses or cystic calculi.

The prostate is large in size (0.60 cm) but has a regular shape with smooth external margins. The parenchyma is heterogenous but no discrete focal lesions are present. The prostatic urethra appears normal with no evidence of irregularity, invasion, mass effect or calculi.

The left kidney has a normal shape and size (3.63 cm). Overall echogenicity is normal with adequate corticomedullary distinction and a typical 1:3 cortex:medulla ratio. There is no evidence of focal perinephric inflammation or effusion. There is no evidence of pyelectasia, nephroliths, infarcts or hydroureter. Renal vasculature is normal.

The right kidney has a normal shape and size (3.24 cm). Overall echogenicity is normal with adequate corticomedullary distinction and a typical 1:3 cortex:medulla ratio. There is no evidence of focal perinephric inflammation or effusion. There is no evidence of pyelectasia, nephroliths, infarcts or hydroureter. Renal vasculature is normal.

**Adrenal Glands**

The left adrenal gland is normal in size measuring 0.41 cm at the cranial pole and 0.39 cm at the caudal pole. It is observed in its normal position cranial to the left renal artery. It is normal in appearance (uniformly hypoechoic) and shape with no evidence of a mass effect.

The right adrenal gland is normal in size measuring 0.48 cm at the cranial pole and 0.33 cm at the caudal pole. It is observed in its normal position between the cranial aspect of the right kidney and the caudal vena cava. It is normal in appearance (uniformly hypoechoic) and shape with no evidence of a mass effect.

**Spleen**

The spleen is subjectively normal in size (0.97 cm), echotexture is homogenous, and the splenic capsule is smooth with no irregularities. The blood flow through the hilus and splenic parenchyma appears normal. No focal parenchymal abnormalities are visualized.

**Liver**

The liver is subjectively normal in size, and echogenicity with smooth peripheral margins. The parenchyma is mildly heterogenous in echotexture with subtle, indistinct focal mottling. The visible portions of the vasculature and biliary tract appear normal. No focal nodules or cystic lesions are observed.



**PATIENT**

Indy Harris

The gall bladder lumen is moderately distended. The wall of the gall bladder is not thickened and has a smooth mucosal surface. Luminal contents are mild and likely incidental at this time. The cystic and common bile ducts are normal/not visible.

**SPECIES**

Canine

***Gastrointestinal***

The stomach contains moderate fluid/ingesta. It measures at a normal thickness of 0.55 cm with some variability due to the presence of rugal folds. The distinction of the gastric wall layers is adequate and there is no impression of reduced peristaltic activity. Moderate fluid interferes with full evaluation of the stomach.

**BREED**

Miniature Australian Shepherd

The visualized areas of duodenum, jejunum and ileum have a relatively uniform diameter with minimal to moderate fluid and gas. Wall thickness is normal. Bowel loops follow a curvilinear path with distinct wall layering maintaining the typical 1:3 muscularis:mucosa layer ratio. Duodenum wall measures 0.34 cm. Jejunum wall measures 0.24 cm. Visualized peristalsis appears appropriate. There were no focal lesions consistent with obstruction or a mass effect observed.

**SEX**

Intact Male

**AGE**

5 Years

Sections of colon are visualized with formed fecal material and gas shadowing distally. There is no observed focal or generalized colon wall thickening or loss of layering.

**WEIGHT**

9.7 lbs

***Pancreas***

The area of the pancreas is normal and isoechoic to surrounding mesentery. There is no evidence of nodules or cystic lesions. There is no evidence of regional mesenteric inflammation or fluid.

**INTERPRETED BY**

Kathleen Sennello DVM,  
MS, Diplomate ACVIM  
(Small Animal Internal  
Medicine)

***Free Abdomen***

Evaluation of the peritoneal cavity did not reveal any evidence of effusion, or subjective lymphadenomegaly. The Medial iliac nodes appear normal and there was no evidence of a caudal aortic thrombus at the bifurcation. The omentum is of normal uniform echogenicity.

**IMAGING PERFORMED BY**

Meghan Morse, LVT,  
CVT

**ULTRASONOGRAPHIC FINDINGS**

- Mildly heterogeneous liver – The diffuse hepatic changes are non-specific and could be consistent with vacuolar hepatopathy, nodular hyperplasia, inflammatory/immune-mediated disease, fibrosis, extramedullary hematopoiesis, toxic hepatopathy (e.g., copper), infiltrative neoplasia (less likely) or other hepatopathy.
- Moderate fluid distention of the stomach and some areas of the small intestine – Correlate with the feeding history. If the patient was adequately fasted this could represent delayed gastric emptying/mild ileus, or a post-prandial patient.

**HOSPITAL NAME**

Walden Animal Clinic

**INTERPRETATION OF THE FINDINGS & FURTHER RECOMMENDATIONS**

The hepatic changes observed are relatively mild. No focal lesions were visualized. The gallbladder appears normal. There could possibly be a mild vacuolar hepatopathy or similar. Further evaluation of the liver could include pre- and post-prandial bile acids to assess liver function prior to anesthesia +/- a fine needle aspirate of the liver.

**REFERRING VET**

Dr. Kelly

**INVOICE**

73218

**DATE**

2/24/26

If values continue to rise, you could consider reevaluation of the liver and adrenals in the future, looking for the development of more significant lesions.



**PATIENT**

Indy Harris

**SPECIES**

Canine

**BREED**

Miniature Australian Shepherd

**SEX**

Intact Male

**AGE**

5 Years

**WEIGHT**

9.7 lbs

**INTERPRETED BY**

Kathleen Sennello DVM,  
 MS, Diplomate ACVIM  
 (Small Animal Internal  
 Medicine)

**IMAGING  
 PERFORMED BY**

Meghan Morse, LVT,  
 CVT

**HOSPITAL NAME**

Walden Animal Clinic

**REFERRING VET**

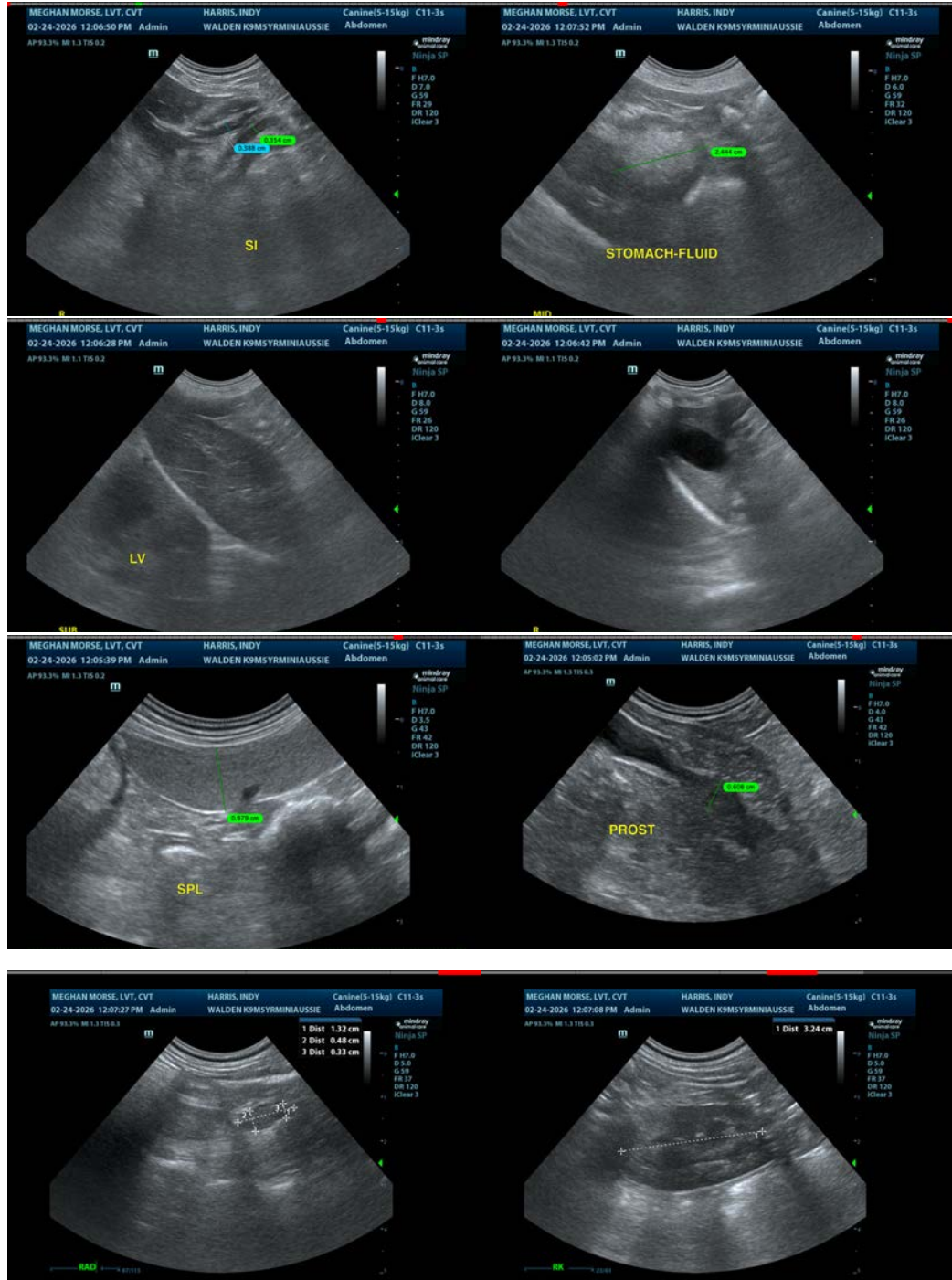
Dr. Kelly

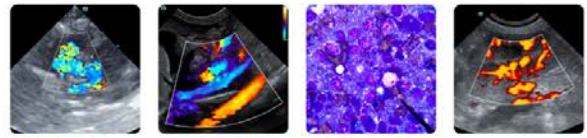
**INVOICE**

73218

**DATE**

2/24/26





**PATIENT**

Indy Harris

**SPECIES**

Canine

**BREED**

Miniature Australian Shepherd

**SEX**

Intact Male

**AGE**

5 Years

**WEIGHT**

9.7 lbs

**INTERPRETED BY**

Kathleen Sennello DVM,  
MS, Diplomate ACVIM  
(Small Animal Internal  
Medicine)

**IMAGING PERFORMED BY**

Meghan Morse, LVT,  
CVT

**HOSPITAL NAME**

Walden Animal Clinic

**REFERRING VET**

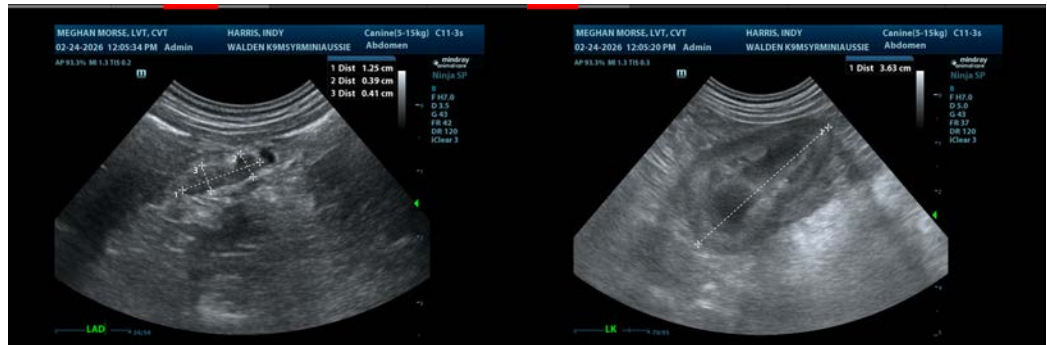
Dr. Kelly

**INVOICE**

73218

**DATE**

2/24/26



The information and recommendations provided are based on the images presented by the referring veterinarian/sonographer. No evaluation can be communicated regarding pathology that was not visible in the image/video clips provided.

Thank you for this referral. If the clinical or image interpretation does not parallel your findings or if I can be of any further assistance please contact me.

Kathleen Sennello DVM,MS, Diplomate ACVIM (Small animal Internal Medicine)

info@sonopath.com