



PATIENT

Ruba Lahoda

SPECIES

Canine

BREED

Great Dane

SEX

Spayed Female

AGE

6.8 Pounds

WEIGHT

128 Pounds

INTERPRETED BY

Kathleen Sennello DVM,
MS, Diplomate ACVIM
(Small Animal Internal
Medicine)

IMAGING PERFORMED BY

Dr. Tam Mengine

HOSPITAL NAME

Stoney Creek VH

REFERRING VET

Dr. Tam Mengine

INVOICE

35877

DATE

2/24/22

PRESENTING CLINICAL SIGNS

Many years history of having explosive bloody diarrhea every 2-3 weeks. Had a GI panel in 6/20, which showed an elevated PLI (388) and a borderline cobalamin (299) - client did not return for follow-up after that appt until 2/4/22 - pet's weight is stable but continues to have GI signs, and for last 3 weeks has been inappetent and also painful (appears to have cervical pain). CBC / Chem normal except Globs 5.4. U/A, GI panel and resting cortisol are pending

ULTRASONOGRAPHIC EXAMINATION OF THE ABDOMEN

Urinary System

The urinary bladder is moderately distended with anechoic urine. The Bladder wall, trigone, ureteral papillae and visible urethra (to a depth of 2cm) appear normal with no evidence of wall thickening, mucosal irregularities, masses or cystic calculi.

The left kidney has a normal shape and size (8.55 cm). Overall echogenicity is normal with adequate corticomedullary distinction and a typical 1:3 cortex:medulla ratio. There is no evidence of perinephric inflammation or effusion. There is no evidence of pyelectasia, nephroliths, infarcts or hydroureter. Renal vasculature is normal.

The right kidney has a normal shape and size (8.78 cm). Overall echogenicity is normal with adequate corticomedullary distinction and a typical 1:3 cortex:medulla ratio. There is no evidence of perinephric inflammation or effusion. There is no evidence of pyelectasia, nephroliths, infarcts or hydroureter. Renal vasculature is normal.

Adrenal Glands

The left adrenal gland is normal/borderline small in size measuring 0.38 cm at the caudal pole. It is observed in its normal position cranial to the left renal artery. It is normal in appearance (uniformly hypoechoic) and shape with no evidence of a mass effect.

The right adrenal gland is normal in size measuring 0.74 cm at the caudal pole. It is observed in its normal position between the cranial aspect of the right kidney and the caudal vena cava. It is normal in appearance (uniformly hypoechoic) and shape with no evidence of a mass effect.

Spleen

The spleen is subjectively normal in size, echotexture is homogenous, and the splenic capsule is smooth with no irregularities. The blood flow through the hilus and splenic parenchyma appears normal. No focal parenchymal abnormalities are visualized.

Liver

The liver is subjectively normal in size, and echogenicity with smooth peripheral margins. The parenchyma is homogenous echotexture. The visible portions of the vasculature and biliary tract appear normal. No focal nodules or cystic lesions are observed.

The gallbladder lumen is moderately distended. The wall of the gall bladder is not thickened and has a smooth mucosal surface. Luminal contents are primarily anechoic. The cystic and common bile ducts are normal/not visible.



PATIENT

Gastrointestinal

Ruba Lahoda

The stomach contains minimal luminal contents. It measures at a normal thickness of <0.7cm with some variability due to the presence of rugal folds. The distinction of the gastric wall layers is adequate and there is no impression of reduced peristaltic activity. No masses or focal lesions were observed.

SPECIES

Canine

The visualized areas of duodenum, jejunum and ileum have a relatively uniform diameter with minimal fluid distension. Wall thickness is normal. Bowel loops follow a curvilinear path with distinct wall layering maintaining the typical 1:3 muscularis:mucosa layer ratio. Duodenum wall measured 0.38 cm. Jejunum wall measured 0.28 cm. Visualized peristalsis appears appropriate. There were no focal lesions consistent with obstruction or a mass effect observed.

BREED

Great Dane

The ileocecal junction was visualized and exhibited normal intact wall layering and is subjectively of normal thickness. Sections of colon are visualized with formed fecal material and gas shadowing distally. There is no observed focal or generalized colon wall thickening or loss of layering. Colon wall measured 0.21 cm.

SEX

Spayed Female

Pancreas

AGE

6.8 Pounds

The pancreas is normal and isoechoic to surrounding mesentery. There is no evidence of nodules or cystic lesions. There is no evidence of regional mesenteric inflammation or fluid.

Free Abdomen

WEIGHT

128 Pounds

Evaluation of the peritoneal cavity did not reveal any evidence of effusion, or subjective lymphadenomegaly. The Medial iliac nodes appear normal and there was no evidence of a caudal aortic thrombus at the bifurcation. The omentum is of normal uniform echogenicity.

ULTRASONOGRAPHIC FINDINGS

- No significant ultrasonographic lesions visualized

INTERPRETED BY

Kathleen Sennello DVM,
MS, Diplomate ACVIM
(Small Animal Internal
Medicine)

INTERPRETATION OF THE FINDINGS & FURTHER RECOMMENDATIONS

No focal gastrointestinal lesions were visualized. Unfortunately, there are many causes for bloody diarrhea that cannot be diagnosed by ultrasound alone.

IMAGING PERFORMED BY

Dr. Tam Mengine

Consider potential metabolic causes such as Addison's disease, pancreatitis, etc. (baseline cortisol and GI panel are pending).

HOSPITAL NAME

Stoney Creek VH

If metabolic disease is thought unlikely, then consider primary GI causes such as dietary intolerance, stress colitis, GI parasitism, less likely IBD, or GI neoplasia.

Based on the history, I'm not clear as to whether this dog has large or small bowel diarrhea, or possibly a combination of the two.

REFERRING VET

Dr. Tam Mengine

- Consider a novel protein/hydrolyzed protein prescription diet.
- Consider chronic probiotic therapy.
- Consider additional fiber. This can help some dogs with diarrhea or make others worse.
- Consider empirical deworming with parasite testing (if not already done).
- Consider endoscopy (either upper and lower GI endoscopy, or if this purely large bowel diarrhea, just lower GI endoscopy).

INVOICE

35877

DATE

2/24/22



PATIENT

Ruba Lahoda

SPECIES

Canine

BREED

Great Dane

SEX

Spayed Female

AGE

6.8 Pounds

WEIGHT

128 Pounds

INTERPRETED BY

Kathleen Sennello DVM,
MS, Diplomate ACVIM
(Small Animal Internal
Medicine)

IMAGING PERFORMED BY

Dr. Tam Mengine

HOSPITAL NAME

Stoney Creek VH

REFERRING VET

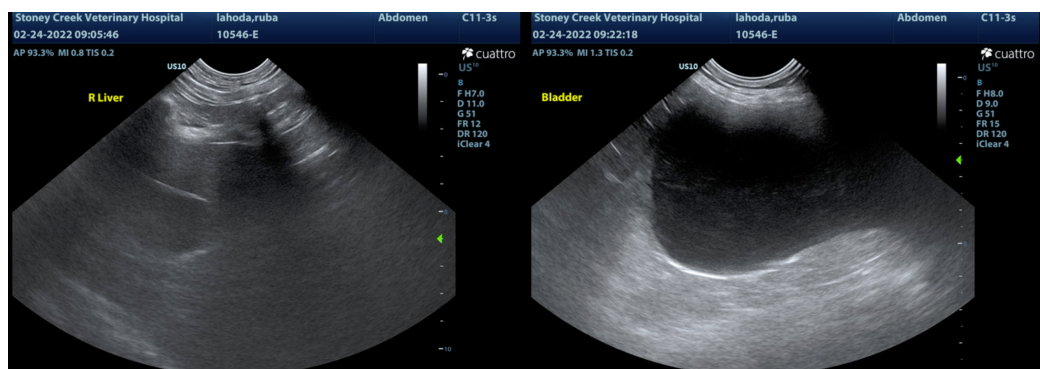
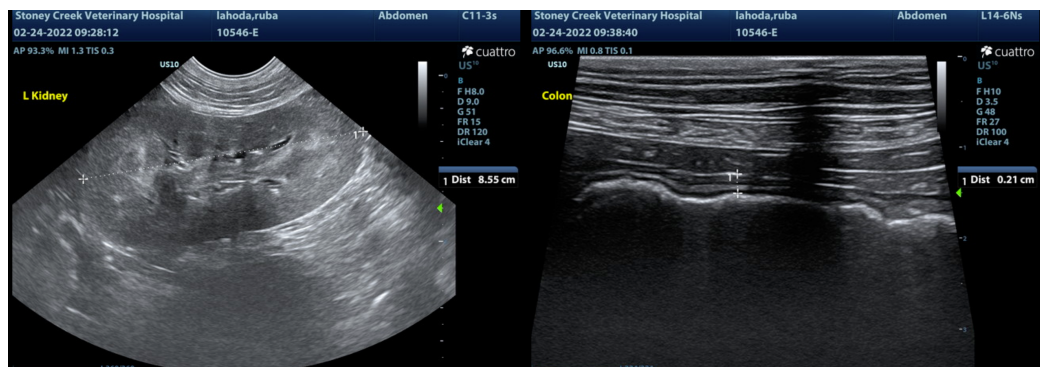
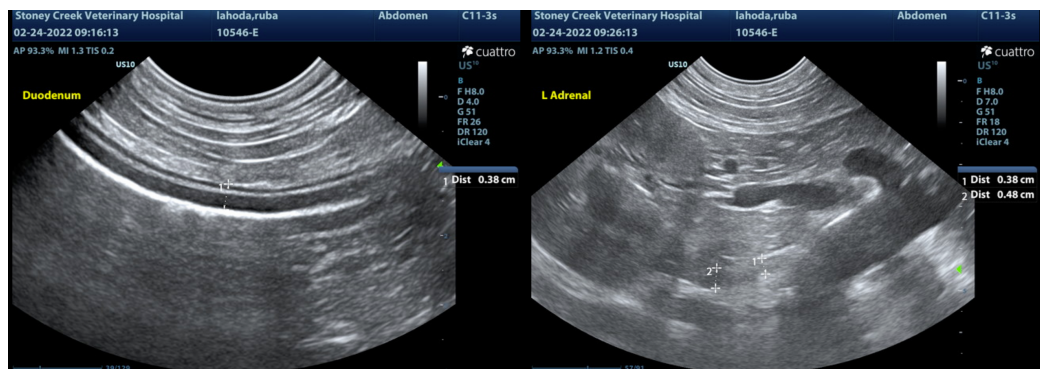
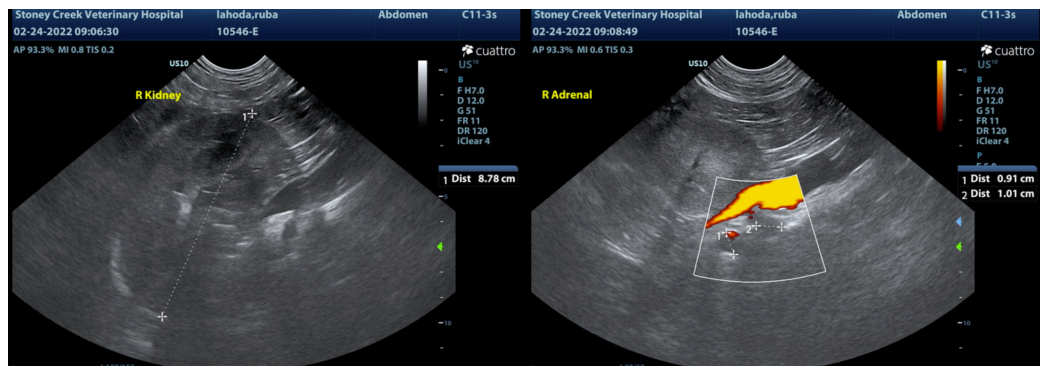
Dr. Tam Mengine

INVOICE

35877

DATE

2/24/22





PATIENT

Ruba Lahoda

SPECIES

Canine

BREED

Great Dane

SEX

Spayed Female

AGE

6.8 Pounds

WEIGHT

128 Pounds

INTERPRETED BY

Kathleen Sennello DVM,
MS, Diplomate ACVIM
(Small Animal Internal
Medicine)

**IMAGING
PERFORMED BY**

Dr. Tam Mengine

HOSPITAL NAME

Stoney Creek VH

REFERRING VET

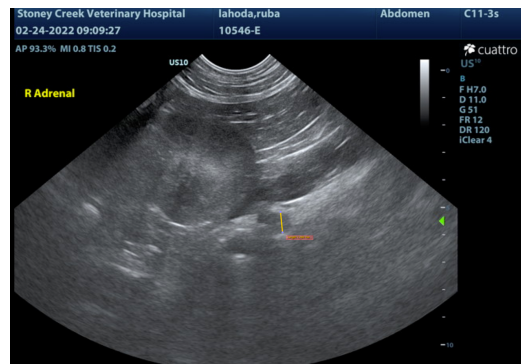
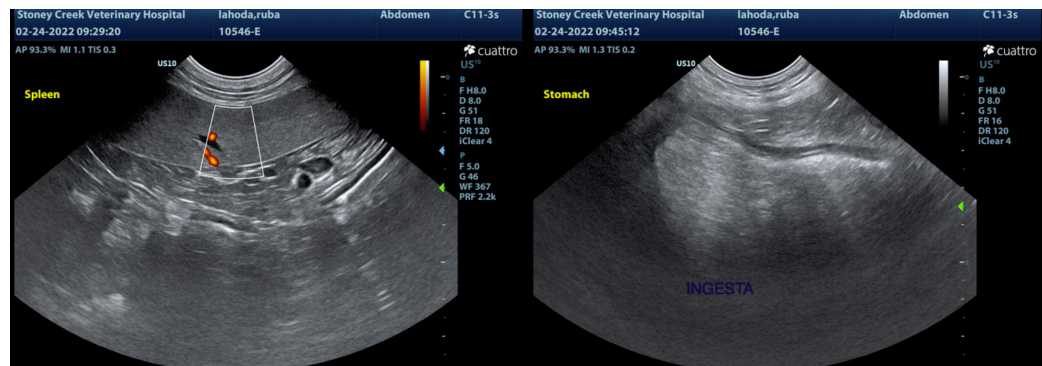
Dr. Tam Mengine

INVOICE

35877

DATE

2/24/22



The information and recommendations provided are based on the images presented by the referring veterinarian/sonographer. No evaluation can be communicated regarding pathology that was not visible in the image/video clips provided.

Thank you for this referral. If the clinical or image interpretation does not parallel your findings or if I can be of any further assistance please contact me.

Kathleen Sennello DVM,MS, Diplomate ACVIM (Small animal Internal Medicine)

kathleen.sennello@sonopath.com