

**DATE PRESENTING CLINICAL SIGNS**

2/24/22

Pet was treated for a gastric lymphoma (B-cell) with 19 week CHOP protocol starting in May of 2021. O's were unable to get post-treatment ultrasound due to a move to the area. Towards the end of CHOP treatment, mild azotemia was noted on bloodwork- Crea 2.2 (0.8-2.4).

**PATIENT**

Daene Walley

Current Medications: None listed.

Lab Results: Pending.

Date of Previous IntraPet Ultrasound: No previous.

**SPECIES**

Feline

Sedation: Not required to complete full diagnostic ultrasound.

Stat Report: Not requested.

**BREED**

Siamese X

**ULTRASONOGRAPHIC EXAMINATION OF THE ABDOMEN****Urinary System**

The urinary bladder is moderately distended with anechoic urine. The Bladder wall, trigone, ureteral papillae and visible urethra (to a depth of 2cm) appear normal with no evidence of wall thickening, mucosal irregularities, masses or cystic calculi.

**SEX**

Neutered Male

The left kidney has a normal shape and size (3.74 cm). Overall echogenicity is slightly hyperechoic with poor corticomedullary distinction and a typical 1:3 cortex:medulla ratio. There is no evidence of perinephric inflammation or effusion. There is no evidence of pyelectasia, nephroliths, infarcts or hydroureter. Renal vasculature is normal.

**AGE**

12/13/12

**WEIGHT**

13.12 Pounds

The right kidney has a normal shape and size (3.93 cm). Overall echogenicity is slightly hyperechoic with poor corticomedullary distinction and a typical 1:3 cortex:medulla ratio. There is no evidence of perinephric inflammation or effusion. There is no evidence of pyelectasia, nephroliths, infarcts or hydroureter. Renal vasculature is normal.

**INTERPRETED BY**

Kathleen Sennello DVM,  
MS, Diplomate ACVIM  
(Small Animal Internal  
Medicine)

**Adrenal Glands**

The left adrenal gland is normal in size measuring 0.38 cm at the caudal pole. It is observed in its normal position cranial to the left renal artery. It is normal in appearance (uniformly hypoechoic) and shape with no evidence of a mass effect.

**IMAGING PERFORMED BY**

Andi Parkinson RDMS

The right adrenal gland is normal in size measuring 0.38 cm at the caudal pole. It is observed in its normal position between the cranial aspect of the right kidney and the caudal vena cava. It is normal in appearance (uniformly hypoechoic) and shape with no evidence of a mass effect.

**HOSPITAL NAME**

Belvedere Vet Center

**Spleen**

The spleen is subjectively normal in size, echotexture is homogenous, and the splenic capsule is smooth with no irregularities. The blood flow through the hilus and splenic parenchyma appears normal. No focal parenchymal abnormalities are visualized.

**REFERRING VET**

Dr. Moulder

**Liver**

The liver is subjectively normal in size, and echogenicity with smooth peripheral margins. The parenchyma is homogenous echotexture. The visible portions of the vasculature and biliary tract appear normal. No focal nodules or cystic lesions are observed.

**INVOICE**

35854

The gallbladder lumen is moderately distended. The wall of the gall bladder is not thickened and has a smooth mucosal surface. Luminal contents are primarily anechoic. The cystic and common bile ducts are normal/not visible.

### ***Gastrointestinal***

The stomach contains minimal luminal contents. It measures at a normal thickness of <0.36cm with some variability due to the presence of rugal folds. The distinction of the gastric wall layers is adequate and there is no impression of reduced peristaltic activity. No focal mass lesions are visualized. The thickest portion of wall observed was along the lesser curvature, measuring 0.33 cm (which is still within normal limits). The previously recorded gastric wall thickness was 1.4 cm on 5/20/21.

The visualized areas of duodenum, jejunum and ileum have a relatively uniform diameter with minimal fluid distension. Wall thickness is normal. Bowel loops follow a curvilinear path with distinct wall layering maintaining the typical 1:3 muscularis:mucosa layer ratio. The duodenum measured as normal (between 0.13-0.38cm in wall thickness) and the jejunum measured as normal (between 0.15-0.36cm.) Visualized peristalsis appears appropriate. There were no focal lesions consistent with obstruction or a mass effect observed.

The ileocecal junction was visualized and exhibited normal intact wall layering and is subjectively of normal thickness. Sections of colon are visualized with formed fecal material and gas shadowing distally. There is no observed focal or generalized colon wall thickening or loss of layering.

### ***Pancreas***

The pancreas is normal and isoechoic to surrounding mesentery. There is no evidence of nodules or cystic lesions. There is no evidence of regional mesenteric inflammation or fluid.

### ***Free Abdomen***

Evaluation of the peritoneal cavity did not reveal any evidence of effusion. There is a prominent gastric lymph node visualized measuring 0.49 cm x 0.31 cm, surrounded by hyperechoic mesentery.

## **ULTRASONOGRAPHIC FINDINGS**

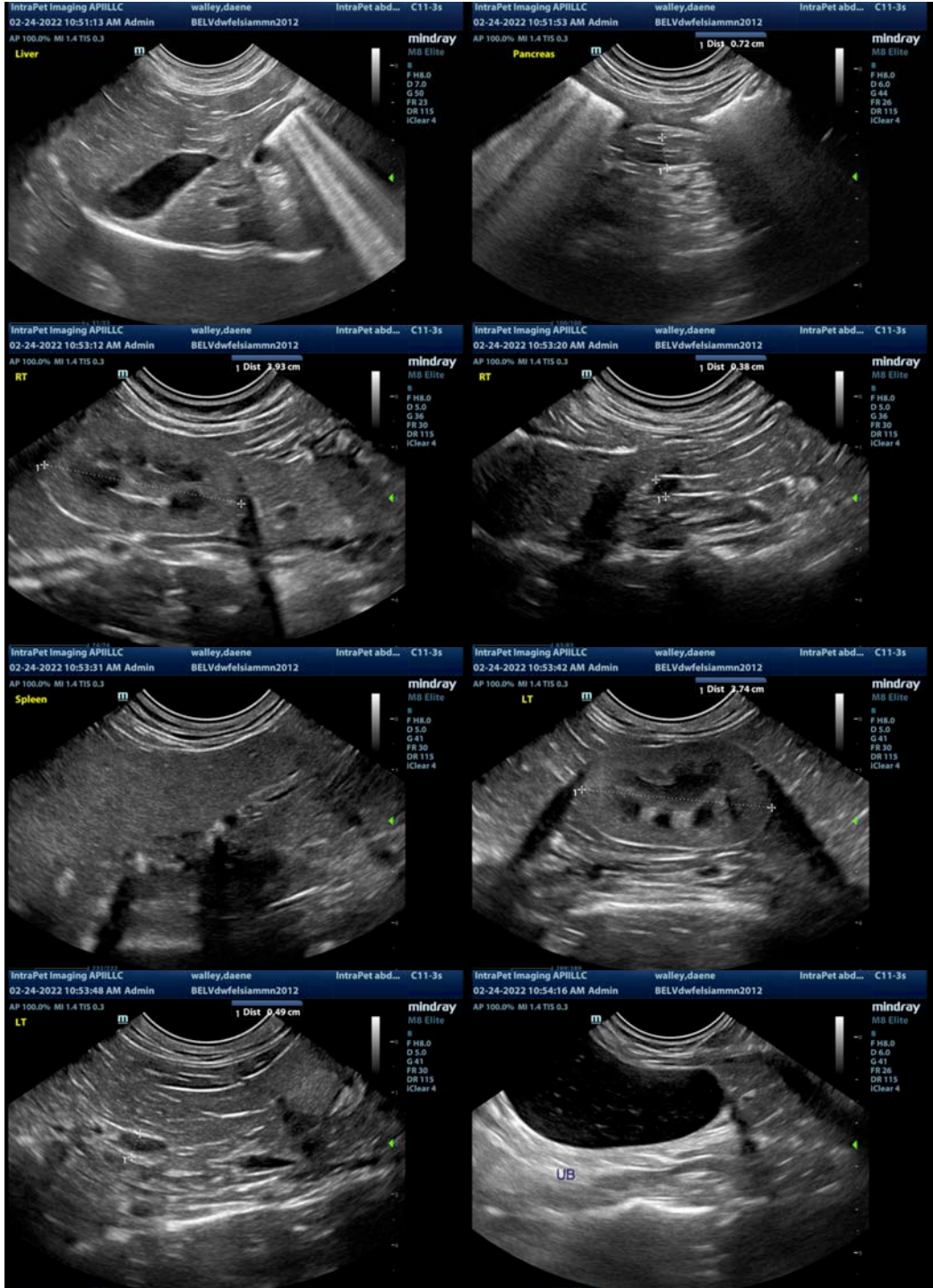
- Decreased corticomedullary distinction in both kidneys – Mild loss of corticomedullary distinction in both kidneys could be consistent with chronic degenerative disease or interstitial nephrosis.
- Prominent gastric lymph node – Differentials include inflammation, infection, or metastatic neoplasia.

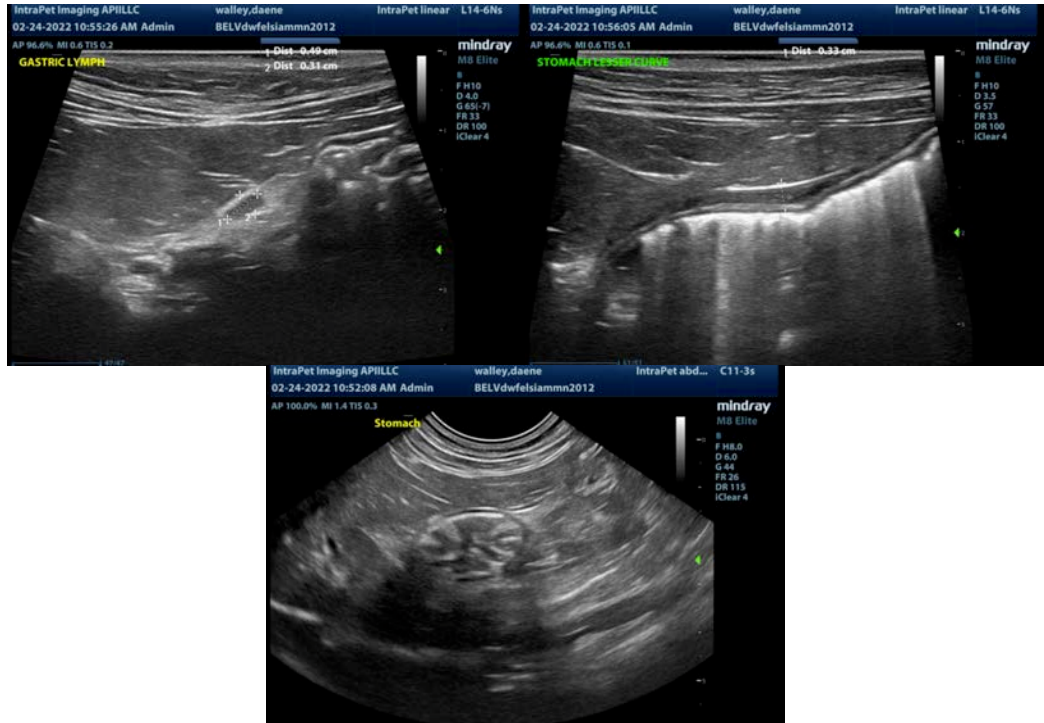
## **INTERPRETATION OF THE FINDINGS & FURTHER RECOMMENDATIONS**

The severe gastric wall thickening previously reported is no longer apparent on today's scan. There is a local prominent lymph node. The significance of this is unclear.

There is decreased corticomedullary distinction in both kidneys. These changes are consistent with chronic progressive renal disease. Recommend blood pressure evaluation and urinalysis and culture for screening purposes.

Recommend consultation with a veterinary oncologist regarding the plan for ongoing treatment and monitoring.





The information and recommendations provided are based on the images presented by the referring veterinarian/sonographer. No evaluation can be communicated regarding pathology that was not visible in the image/video clips provided.

Thank you for this referral. If the clinical or image interpretation does not parallel your findings or if I can be of any further assistance please contact me.

Kathleen Sennello DVM,MS, Diplomate ACVIM (Small animal Internal Medicine)  
kathleen.sennello@sonopath.com