

**DATE PRESENTING CLINICAL SIGNS**

2/23/23

P has been gradually losing weight- p over 15lbs 1 year ago. Appetite has been vigorous. No v/d/c/s noted. ALT was elevated at 294, but the rest of the chemistry panel, CBC, and urinalysis results fairly unremarkable.

PATIENT

Garfield Lowe

Current Medications: None.

Lab Results: Attached.

Date of Previous IntraPet Ultrasound: No previous.

SPECIES

Feline

Sedation: 0.1cc ketamine, dexdomitor, butorphanol IM.

Stat Report: Declined.

BREED

DSH

Imaging Performed By: Rachel Brillhart, RDMS.

SEX

Neutered Male

Urinary System

The urinary bladder is moderately distended with anechoic urine. The Bladder wall, trigone, ureteral papillae and visible urethra (to a depth of 2cm) appear normal with no evidence of wall thickening, mucosal irregularities, masses or cystic calculi.

AGE

10/30/20

The left kidney has a normal shape and size (3.15 cm). Overall echogenicity is normal with adequate corticomedullary distinction and a typical 1:3 cortex:medulla ratio. There is no evidence of focal perinephric inflammation or effusion. There is no evidence of pyelectasia, nephroliths, infarcts or hydroureter. Renal vasculature is normal.

WEIGHT

8.62 Pounds

The right kidney has a normal shape and size (3.78 cm). Overall echogenicity is normal with adequate corticomedullary distinction and a typical 1:3 cortex:medulla ratio. There is no evidence of focal perinephric inflammation or effusion. There is no evidence of pyelectasia, nephroliths, infarcts or hydroureter. Renal vasculature is normal.

INTERPRETED BY

Kathleen Sennello DVM,
MS, Diplomate ACVIM
(Small Animal Internal
Medicine)

Adrenal Glands

The left adrenal gland is normal in size measuring 0.37 cm at the caudal pole. It is observed in its normal position cranial to the left renal artery. It is normal in appearance (uniformly hypoechoic) and shape with no evidence of a mass effect.

HOSPITAL NAME

Fullerton AH

The right adrenal gland is normal in size measuring 0.46 cm at the caudal pole. It is observed in its normal position between the cranial aspect of the right kidney and the caudal vena cava. It is normal in appearance (uniformly hypoechoic) and shape with no evidence of a mass effect.

REFERRING VET

Dr. Levine

Spleen

The spleen is subjectively normal in size (0.74 cm), echotexture is homogenous, and the splenic capsule is smooth with no irregularities. The blood flow through the hilus and splenic parenchyma appears normal. No focal parenchymal abnormalities are visualized.

INVOICE

45459

Liver

The liver is subjectively normal in size, and echogenicity with smooth peripheral margins. The parenchyma is homogenous echotexture. The visible portions of the vasculature and biliary tract appear normal. No focal nodules or cystic lesions are observed.

The gallbladder lumen is moderately distended. The wall of the gall bladder is not thickened and has a smooth mucosal surface. Luminal contents are mild and primarily anechoic. The cystic duct appears somewhat prominent and dilated, measuring 0.38 cm. It is lost to follow up more distally.

Gastrointestinal

The stomach contains minimal luminal contents. It measures at a normal thickness of <0.36cm with some variability due to the presence of rugal folds. The distinction of the gastric wall layers is adequate and there is no impression of reduced peristaltic activity. No masses or focal lesions were observed.

The visualized areas of duodenum, jejunum and ileum have a uniform diameter with minimal fluid distension. Wall thickness is normal to slightly increased. Bowel loops follow a typical curvilinear path with distinct wall layering, but some areas display a prominent muscularis layer which does not display the typical 1:3 muscularis:mucosa layer ratio. Jejunum wall measures 0.32 cm. Visualized peristalsis appears appropriate. There is a section of small intestine that has a double lumen effect, most consistent with an intussusception. There is minimal surrounding inflammation, but there is generalized scant free abdominal fluid.

The ileocecal junction was visualized and exhibited normal intact wall layering and is subjectively of normal thickness. Sections of colon are visualized with formed fecal material and gas shadowing distally. There is no observed focal or generalized colon wall thickening or loss of layering.

Pancreas

The pancreas is normal and isoechoic to surrounding mesentery. There is no evidence of nodules or cystic lesions. There is no evidence of regional mesenteric inflammation or fluid.

Free Abdomen

Small amount of free abdominal fluid noted. There is a moderate diffuse lymphadenopathy present with mesenteric lymph nodes measuring 0.40 cm and 0.31 cm. The omentum is diffusely hyperechoic.

PRIMARY FINDINGS

- Diffusely thickened small intestine with a prominent muscularis layer – The small intestinal wall changes could be consistent with an underlying inflammatory process. These types of changes can sometimes be seen in normal older cats. Correlate with clinical signs.
- Double lumen effect visualized with the bowel – Findings are most consistent with a small bowel intussusception.
- Small volume free abdominal fluid.
- Mild lymphadenopathy – The prominent abdominal lymph nodes are most consistent with reactive lymphadenitis or lymphoid hyperplasia. Neoplastic infiltration is considered less likely.

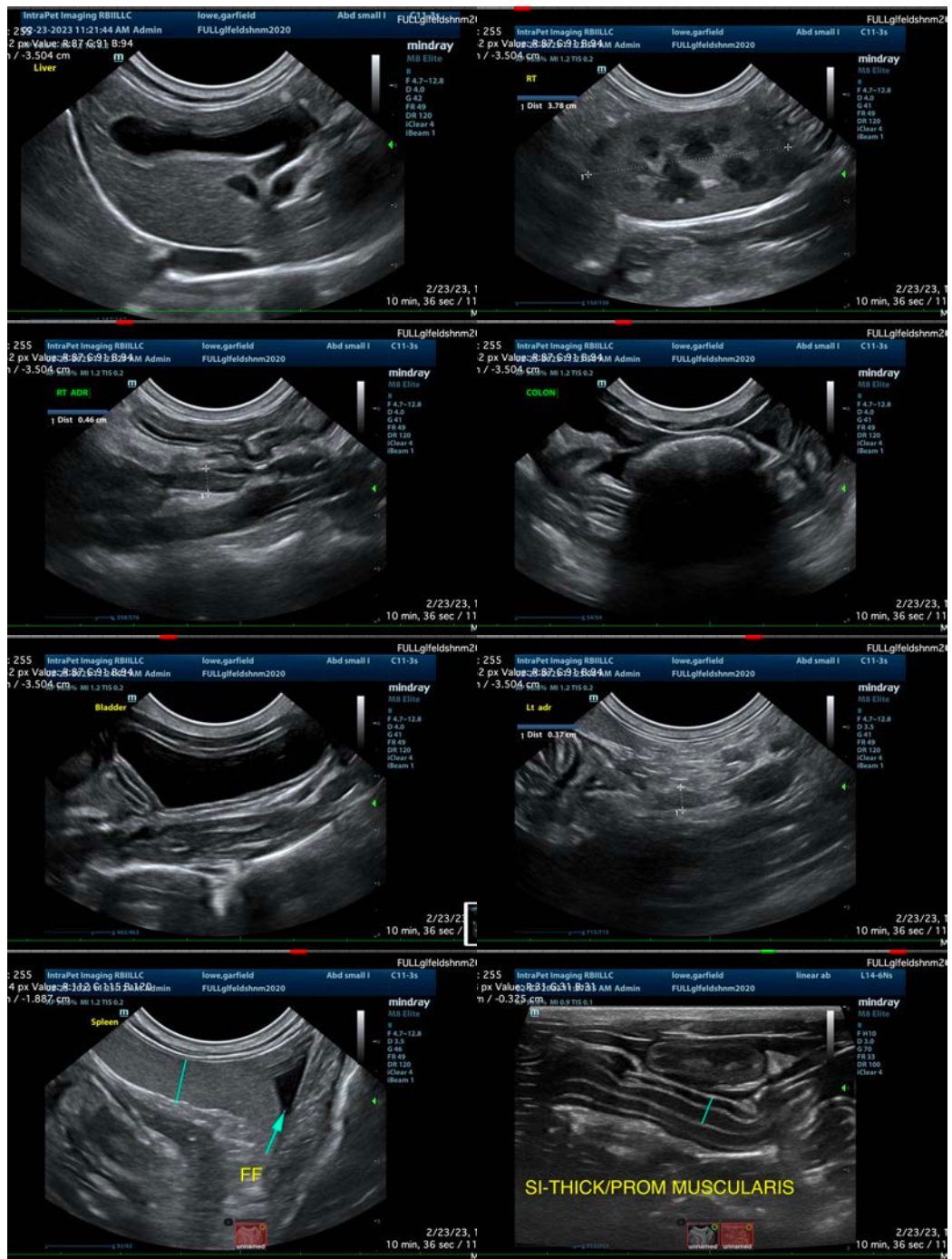
SECONDARY FINDINGS

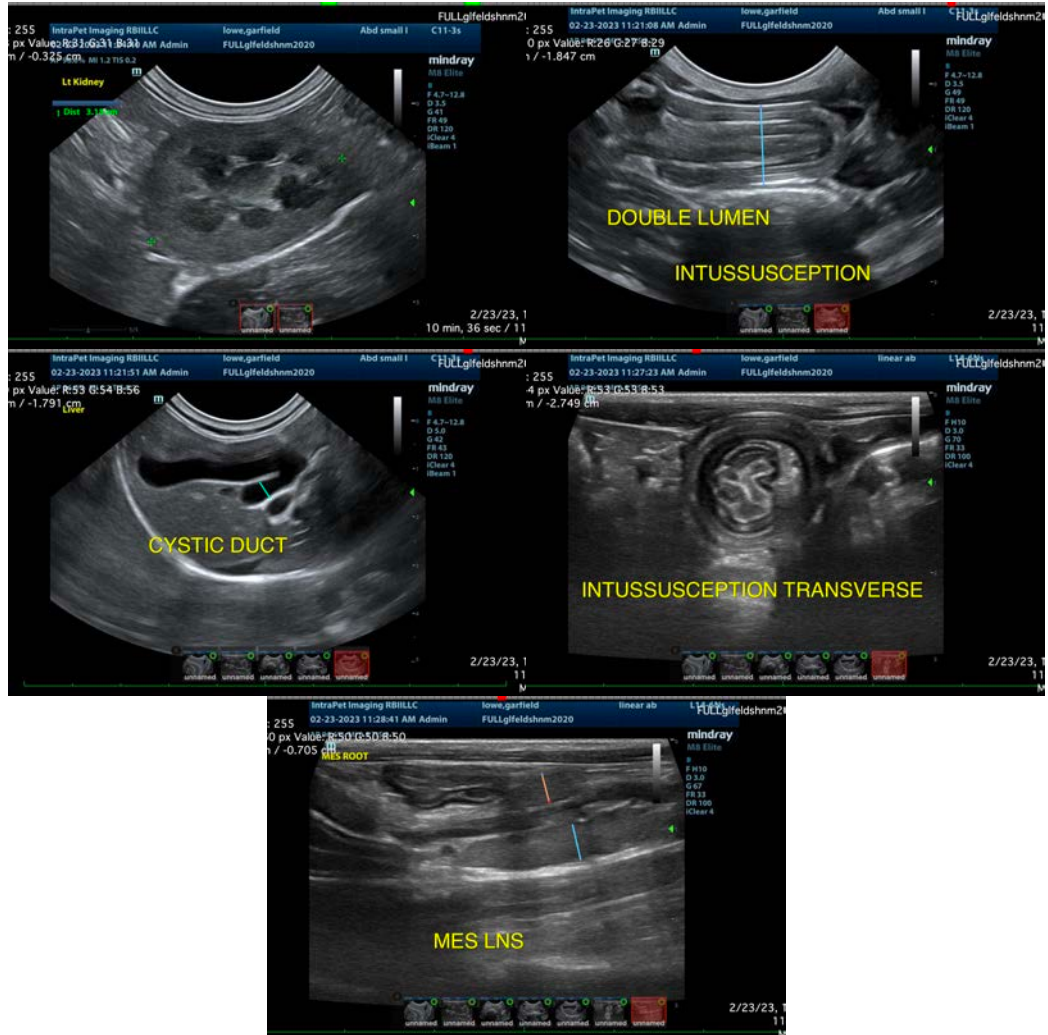
- Prominent cystic duct – There is no intraluminal debris visualized, and it cannot be followed more distally. The significance of this is currently unclear. Recommend continued monitoring.

INTERPRETATION OF THE FINDINGS & FURTHER RECOMMENDATIONS

The small bowel generally appears somewhat “ropey” with a prominent muscularis layer and measures as somewhat thickened. This is most consistent with inflammatory GI disease, which can be seen with food allergy/dietary indiscretion, GI parasitism, possibly dysbiosis, less likely IBD or neoplasia. Additionally, there is a focal intussusception present. Given the history of a 50% weight loss, it seems unlikely that the

intussusception has been chronic, and that primary gastrointestinal disease is the primary lesion with an intussusception developing because of this. Recommend surgery to reduce the intussusception and obtain GI biopsies. Additionally, consider obtaining hepatic biopsies due to the elevation in ALT reported.





The information and recommendations provided are based on the images presented by the referring veterinarian/sonographer. No evaluation can be communicated regarding pathology that was not visible in the image/video clips provided.

Thank you for this referral. If the clinical or image interpretation does not parallel your findings or if I can be of any further assistance please contact me.

Kathleen Sennello DVM,MS, Diplomate ACVIM (Small animal Internal Medicine)
 kathleen.sennello@sonopath.com