

**PATIENT PRESENTING CLINICAL SIGNS**

**Finn Smith**  
Diet-Hills KD- ~Evaluation of kidneys, r/o renal dysplasia vs uroliths vs other, persistent mild elevation of kidney values~ Relevant Medical History and Physical Exam findings: ~Patient presented for general evaluation and neuter. Pre-op bloodwork showed mild kidney values elevation that has persisted on post-op evaluations despite of diet changes. Recommended evaluation of urinary tract to rule out possible underlying disease~

**SPECIES**

Canine

**BREED**

Golden Ret

**ULTRASONOGRAPHIC EXAMINATION OF THE ABDOMEN**

**Urinary System**

**SEX**

Neutered Male

The urinary bladder is moderately distended with anechoic urine. The Bladder wall, trigone, ureteral papillae, and visible urethra (to a depth of 2cm) appear normal with no evidence of wall thickening, mucosal irregularities, masses, or cystic calculi.

**AGE**

2y5m

The prostate is large in size measuring 1.65 cm in width at sagittal view. The parenchyma is homogenous, and the external margins are smooth. The prostatic urethra appears normal with no evidence of irregularity, invasion, mass effect or calculi. This is likely normal for a dog that has been recently neutered.

**WEIGHT**

67lbs

The left kidney has a normal shape and size (5.1 cm). Overall echogenicity is slightly hyperechoic with mildly reduced corticomedullary distinction and a typical 1:3 cortex: medulla ratio. There is no evidence of focal perinephric inflammation or effusion. There is no evidence of pyelectasia, nephroliths, infarcts or hydroureter. Renal vasculature is normal.

**INTERPRETED BY**

Kathleen Sennello DVM,  
MS, Diplomate ACVIM  
(Small Animal Internal  
Medicine)

The right kidney has a normal shape and size (5.7 cm). Overall echogenicity is slightly hyperechoic with mildly reduced corticomedullary distinction and a typical 1:3 cortex: medulla ratio. There is no evidence of focal perinephric inflammation or effusion. There is no evidence of pyelectasia, nephroliths, infarcts or hydroureter. Renal vasculature is normal.

**IMAGING PERFORMED BY**

Loetitia Saint-Jacques,  
LVT

**Adrenal Glands**

The left adrenal gland is normal in size measuring 0.49 cm at the caudal pole. It is observed in its normal position cranial to the left renal artery. It is normal in appearance (uniformly hypoechoic) and shape with no evidence of a mass effect.

**HOSPITAL NAME**

Mountain View Animal  
Hospital

The right adrenal gland is normal in size measuring 0.75 cm at the caudal pole. It is observed in its normal position between the cranial aspect of the right kidney and the caudal vena cava. It is normal in appearance (uniformly hypoechoic) and shape with no evidence of a mass effect.

**REFERRING VET**

Dr. Sarah Kalivoda

**Spleen**

The spleen is subjectively normal in size, echotexture is homogenous, and the splenic capsule is smooth with no irregularities. The blood flow through the hilus and splenic parenchyma appears normal. No focal parenchymal abnormalities are visualized.

**INVOICE**

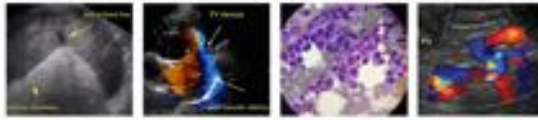
10069

**Liver**

**DATE**

2/23/2023

The liver is subjectively normal in size, and echogenicity with smooth peripheral margins. The parenchyma is homogenous echotexture. The visible portions of the vasculature and biliary tract appear normal. No focal nodules or cystic lesions are observed.



**PATIENT**

Finn Smith

The gallbladder lumen is moderately distended. The wall of the gall bladder is not thickened and has a smooth mucosal surface. Luminal contents are mild and primarily anechoic. The cystic and common bile ducts are normal/not visible.

**SPECIES**

Canine

**Gastrointestinal**

The stomach contains minimal luminal contents. It measures at a normal thickness of <0.7cm with some variability due to the presence of rugal folds. The distinction of the gastric wall layers is adequate and there is no impression of reduced peristaltic activity. No masses or focal lesions were observed.

**BREED**

Golden Ret

The visualized areas of duodenum, jejunum and ileum have a relatively uniform diameter with minimal fluid distension. Wall thickness is normal. Bowel loops follow a curvilinear path with distinct wall layering maintaining the typical 1:3 muscularis: mucosa layer ratio. Visualized peristalsis appears appropriate. There were no focal lesions consistent with obstruction or a mass effect observed.

**SEX**

Neutered Male

**AGE**

2y5m

The ileocecal junction was visualized and exhibited normal intact wall layering and is subjectively of normal thickness. Sections of colon are visualized with formed fecal material and gas shadowing distally. There is no observed focal or generalized colon wall thickening or loss of layering.

**WEIGHT**

67lbs

**Pancreas**

The pancreas is normal and isoechoic to surrounding mesentery. There is no evidence of nodules or cystic lesions. There is no evidence of regional mesenteric inflammation or fluid.

**INTERPRETED BY**

Kathleen Sennello DVM,  
MS, Diplomate ACVIM  
(Small Animal Internal  
Medicine)

**Free Abdomen**

Evaluation of the peritoneal cavity did not reveal any evidence of effusion. There is a small cluster of prominent lymph nodes visualized near the ileocecal junction, one such lymph node is measured at 1.3 cm x 2.89 cm. The omentum is of normal uniform echogenicity.

**IMAGING PERFORMED BY**

Loetitia Saint-Jacques,  
LVT

**PRIMARY FINDINGS**

- Questionable/mildly reduced corticomedullary distinction in both kidneys. Mild loss of corticomedullary distinction in both kidneys could be consistent with chronic degenerative disease or interstitial nephrosis.
- Prominent lymph nodes at the ileocecal junction. Differentials would include inflammation, infection, and less likely neoplastic change.

**HOSPITAL NAME**

Mountain View Animal  
Hospital

**REFERRING VET**

Dr. Sarah Kalivoda

**INTERPRETATION OF THE FINDINGS & FURTHER RECOMMENDATIONS**

No prominent lesions are visualized associated with the kidneys. There is questionable reduction in corticomedullary distinction for this young of a dog. There are no obvious signs of renal dysplasia, but mildly dysplastic kidneys could appear relatively normal. Histopathology is required for definitive diagnoses, and this is not recommended, as it can alter the remaining renal function. Recommend a blood pressure evaluation, urinalysis, and culture, looking for any concurrent issues. Also consider screening for Addison's Disease.

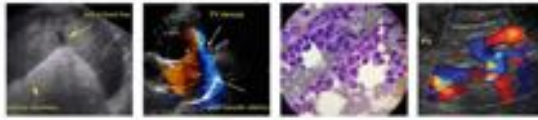
**INVOICE**

10069

**DATE**

2/23/2023

There are prominent hypoechoic lymph nodes visualized at the ileocecal junction. It is not uncommon to see prominent lymph nodes in young dogs, but this seems fairly focal. Correlate this with possible recent diarrhea, GI upset, etc. Options moving forward would include a fine needle aspirate of these



**PATIENT**

Finn Smith

lymph nodes or recheck in the future once possible inflammation has resolved (4-6 weeks?) Unfortunately, there are not a lot of therapeutic inventions for early renal disease other than a low protein diet, controlling hypertension, hydration, and in some instances calcitriol therapy. I would also consider screening for leptospirosis and performing full bloodwork if this has not already been done.

**SPECIES**

Canine

**BREED**

Golden Ret

**SEX**

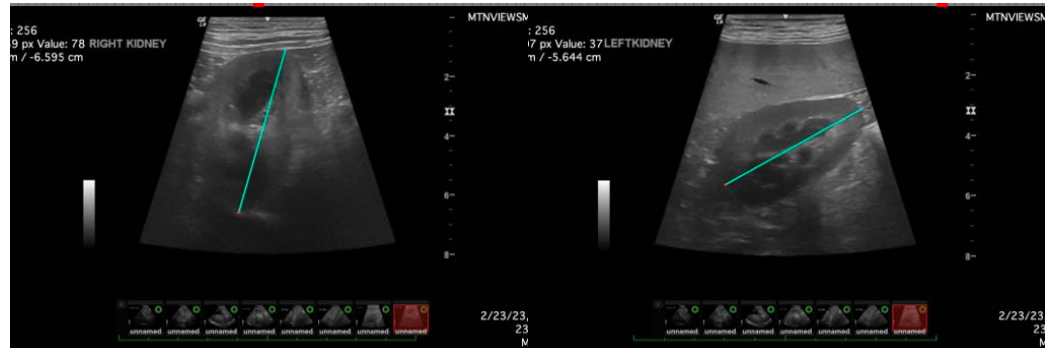
Neutered Male

**AGE**

2y5m

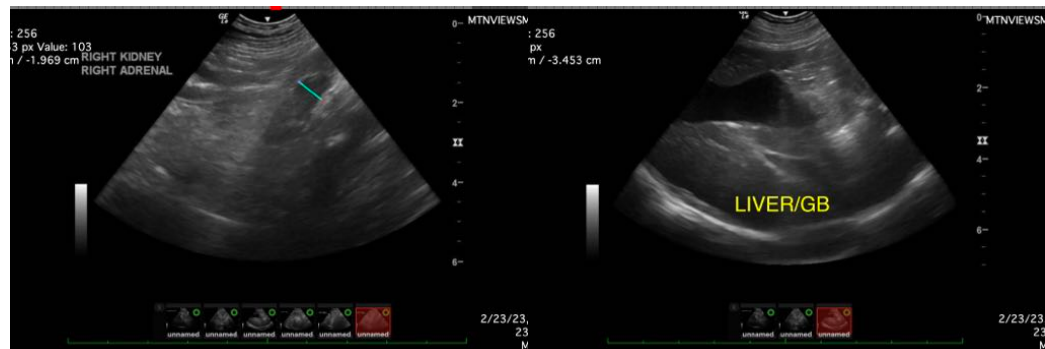
**WEIGHT**

67lbs



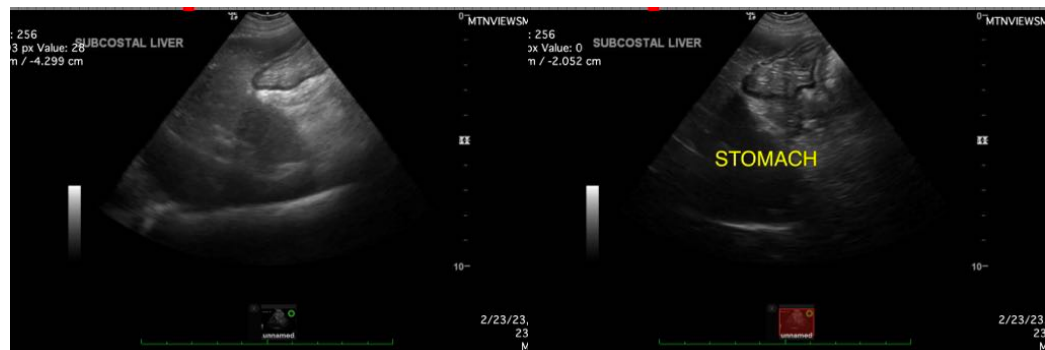
**INTERPRETED BY**

Kathleen Sennello DVM, MS, Diplomate ACVIM (Small Animal Internal Medicine)



**IMAGING PERFORMED BY**

Loetitia Saint-Jacques, LVT



**HOSPITAL NAME**

Mountain View Animal Hospital

**REFERRING VET**

Dr. Sarah Kalivoda

**INVOICE**

10069

**DATE**

2/23/2023



**PATIENT**

Finn Smith

**SPECIES**

Canine

**BREED**

Golden Ret

**SEX**

Neutered Male

**AGE**

2y5m

**WEIGHT**

67lbs

**INTERPRETED BY**

Kathleen Sennello DVM,  
MS, Diplomate ACVIM  
(Small Animal Internal  
Medicine)

**IMAGING  
PERFORMED BY**

Loetitia Saint-Jacques,  
LVT

**HOSPITAL NAME**

Mountain View Animal  
Hospital

**REFERRING VET**

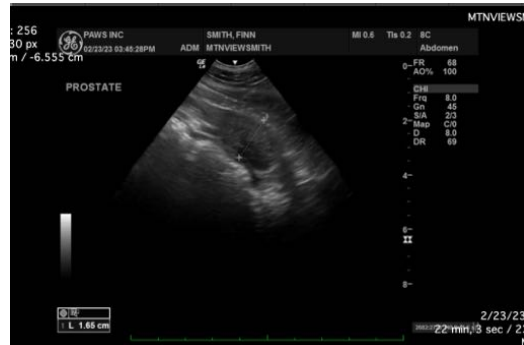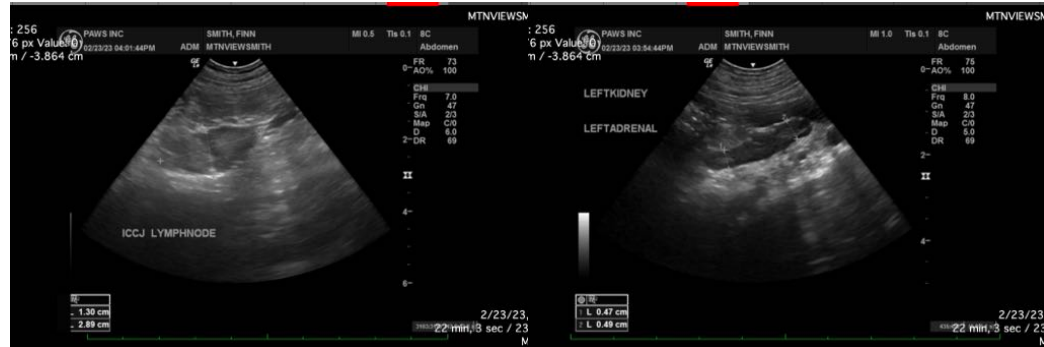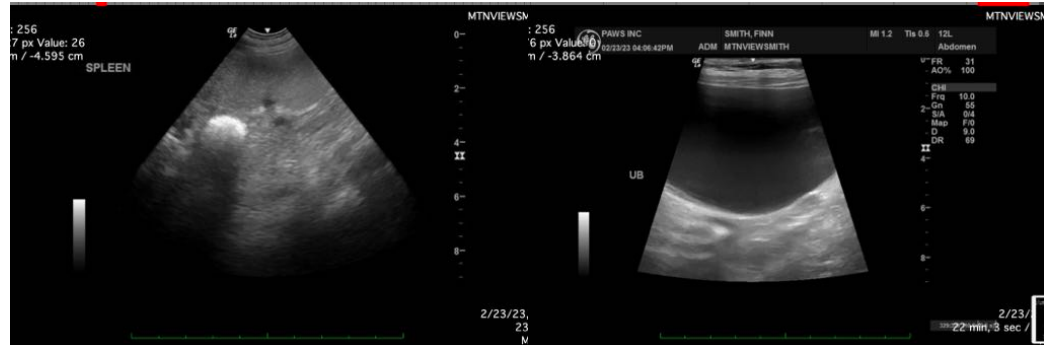
Dr. Sarah Kalivoda

**INVOICE**

10069

**DATE**

2/23/2023



The information and recommendations provided are based on the images presented by the referring veterinarian/sonographer. No evaluation can be communicated regarding pathology that was not visible in the image/video clips provided.

Thank you for this referral. If the clinical or image interpretation does not parallel your findings or if I can be of any further assistance, please contact me.

Kathleen Sennello DVM, MS, Diplomate ACVIM (Small animal Internal Medicine)

kathleen.sennello@sonopath.com