



PATIENT PRESENTING CLINICAL SIGNS

Coda Vanoverdijk Weak hind end, hypothermia, weight loss.

SPECIES Abnormal PE/Chem/CBC/UA Results: Bloodwork: CBC non regen anemia (mild), neutrophilia and monocytosis Chem 15 TP 66, Alb 27, glob 38 (all normal now) Lytes normal T4 grey zone SDMA mild increase cardiac ProBNP snap NORMAL

Feline

BREED ULTRASONOGRAPHIC EXAMINATION OF THE ABDOMEN

DSH

Urinary System

SEX

Spayed Female

The urinary bladder is moderately distended with anechoic urine. The Bladder wall, trigone, ureteral papillae and visible urethra (to a depth of 2cm) appear normal with no evidence of wall thickening, mucosal irregularities, masses or cystic calculi.

AGE

17 Years

The left kidney has a normal shape and size (4.15 cm). Overall echogenicity is normal with adequate corticomedullary distinction and a typical 1:3 cortex:medulla ratio. There is no evidence of focal perinephric inflammation or effusion. There is no evidence of pyelectasia, nephroliths, infarcts or hydroureter. Renal vasculature is normal.

WEIGHT

2.92 kg

The right kidney has a normal shape and size (4.26 cm). Overall echogenicity is normal with adequate corticomedullary distinction and a typical 1:3 cortex:medulla ratio. There is no evidence of focal perinephric inflammation or effusion. There is no evidence of pyelectasia, nephroliths, infarcts or hydroureter. Renal vasculature is normal.

INTERPRETED BY

Kathleen Sennello DVM,
MS, Diplomate ACVIM
(Small Animal Internal
Medicine)

Adrenal Glands

IMAGING PERFORMED BY

Kelly Reschny

The left adrenal gland is normal in size measuring 0.26 cm at the caudal pole. It is observed in its normal position cranial to the left renal artery. It is normal in appearance (uniformly hypoechoic) and shape with no evidence of a mass effect.

HOSPITAL NAME

Hamilton Region Vet
Emergency Clinic

The right adrenal gland is normal in size measuring 0.31 cm at the caudal pole. It is observed in its normal position between the cranial aspect of the right kidney and the caudal vena cava. It is normal in appearance (uniformly hypoechoic) and shape with no evidence of a mass effect.

REFERRING VET

Dr. Wattson

Spleen

The spleen is subjectively normal in size (0.64 cm in width at the level of the hilus), echotexture is homogenous, and the splenic capsule is smooth with no irregularities. The blood flow through the hilus and splenic parenchyma appears normal. No focal parenchymal abnormalities are visualized.

INVOICE

45450

Liver

The liver is subjectively normal in size, and echogenicity with smooth peripheral margins. The parenchyma is mildly heterogenous in echotexture with subtle, indistinct focal mottling. The visible portions of the vasculature and biliary tract appear normal. There is a focal area of parenchyma that appears to have ill-defined hypoechoic regions, almost a "moth eaten" appearance. This is adjacent to the gallbladder, along the ventral abdomen. This region measures at least 1.89 cm x 1.39 cm.

DATE

2/23/23

The gallbladder lumen is moderately distended. The wall of the gall bladder is not thickened and has a smooth mucosal surface. Luminal contents are mild and primarily anechoic. The cystic and common bile ducts are normal/not visible.


PATIENT
Gastrointestinal

Coda Vanoverdijk

The stomach appears empty of any ingesta or fluid. The gastric wall appears severely diffusely thickened with complete loss of layering, creating a large mass effect. The gastric wall in this region measures 1.64 cm in thickness. The mass effect measures approximately 3.57 cm x 3.66 cm. Findings are most consistent with a gastric mass effect due to infiltration of the gastric wall.

SPECIES

Feline

BREED

DSH

SEX

Spayed Female

The visualized areas of duodenum, jejunum and ileum have a relatively uniform diameter with minimal fluid distension. Wall thickness is normal. Bowel loops follow a curvilinear path with distinct wall layering maintaining the typical 1:3 muscularis:mucosa layer ratio. Jejunum wall measures 0.22 cm. Visualized peristalsis appears appropriate. There were no focal lesions consistent with obstruction or a mass effect observed.

AGE

17 Years

The ileocecal junction was visualized and exhibited normal intact wall layering and is subjectively of normal thickness. Sections of colon are visualized with formed fecal material and gas shadowing distally. There is no observed focal or generalized colon wall thickening or loss of layering.

WEIGHT

2.92 kg

Pancreas

The pancreas is normal and isoechoic to surrounding mesentery. There is no evidence of nodules or cystic lesions. There is no evidence of regional mesenteric inflammation or fluid.

Free Abdomen

Evaluation of the peritoneal cavity did not reveal any evidence of effusion. There is a prominent gastric lymph node in the cranial abdomen measuring 1.33 cm in diameter. The omentum is hyperechoic around the stomach.

INTERPRETED BY

 Kathleen Sennello DVM,
 MS, Diplomate ACVIM
 (Small Animal Internal
 Medicine)

ULTRASONOGRAPHIC FINDINGS

- Irregular, heterogeneous “moth eaten” area of liver – The significance of this is uncertain. Consider a fine needle aspirate of this region.
- Severely thickened gastric wall with complete loss of layering – Findings are concerning for round cell neoplasia, carcinoma, other. Recommend fine needle aspirate.
- Large, hypoechoic gastric lymph node – Findings are concerning for a metastatic lymph node, although a reactive lymph node is possible.

HOSPITAL NAME

 Hamilton Region Vet
 Emergency Clinic

INTERPRETATION OF THE FINDINGS & FURTHER RECOMMENDATIONS
REFERRING VET

Dr. Wattson

The gastric wall is severely thickened and abnormal with complete loss of layering. Recommend a fine needle aspirate of the gastric wall and cytologic evaluation. Additionally, there is a region of liver that has a somewhat “moth eaten” appearance. The significance of this is unclear, and it is a poorly defined region, but a fine needle aspirate could be considered to further evaluate.

INVOICE

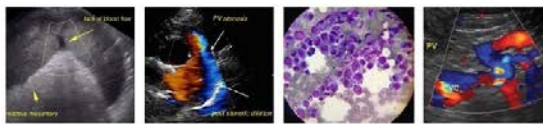
45450

Recommend three view thoracic radiographs to evaluate for possible concurrent thoracic disease/involvement.

DATE

2/23/23

If cytologic diagnosis can be obtained, recommend consultation with a veterinary oncologist regarding treatment options and prognosis. If a cytologic diagnosis cannot be obtained, surgical biopsies may be necessary, but this lesion is unlikely to be surgically resectable.



PATIENT

Coda Vanoverdijk

SPECIES

Feline

BREED

DSH

SEX

Spayed Female

AGE

17 Years

WEIGHT

2.92 kg

INTERPRETED BY

Kathleen Sennello DVM,
MS, Diplomate ACVIM
(Small Animal Internal
Medicine)

**IMAGING
PERFORMED BY**

Kelly Reschny

HOSPITAL NAME

Hamilton Region Vet
Emergency Clinic

REFERRING VET

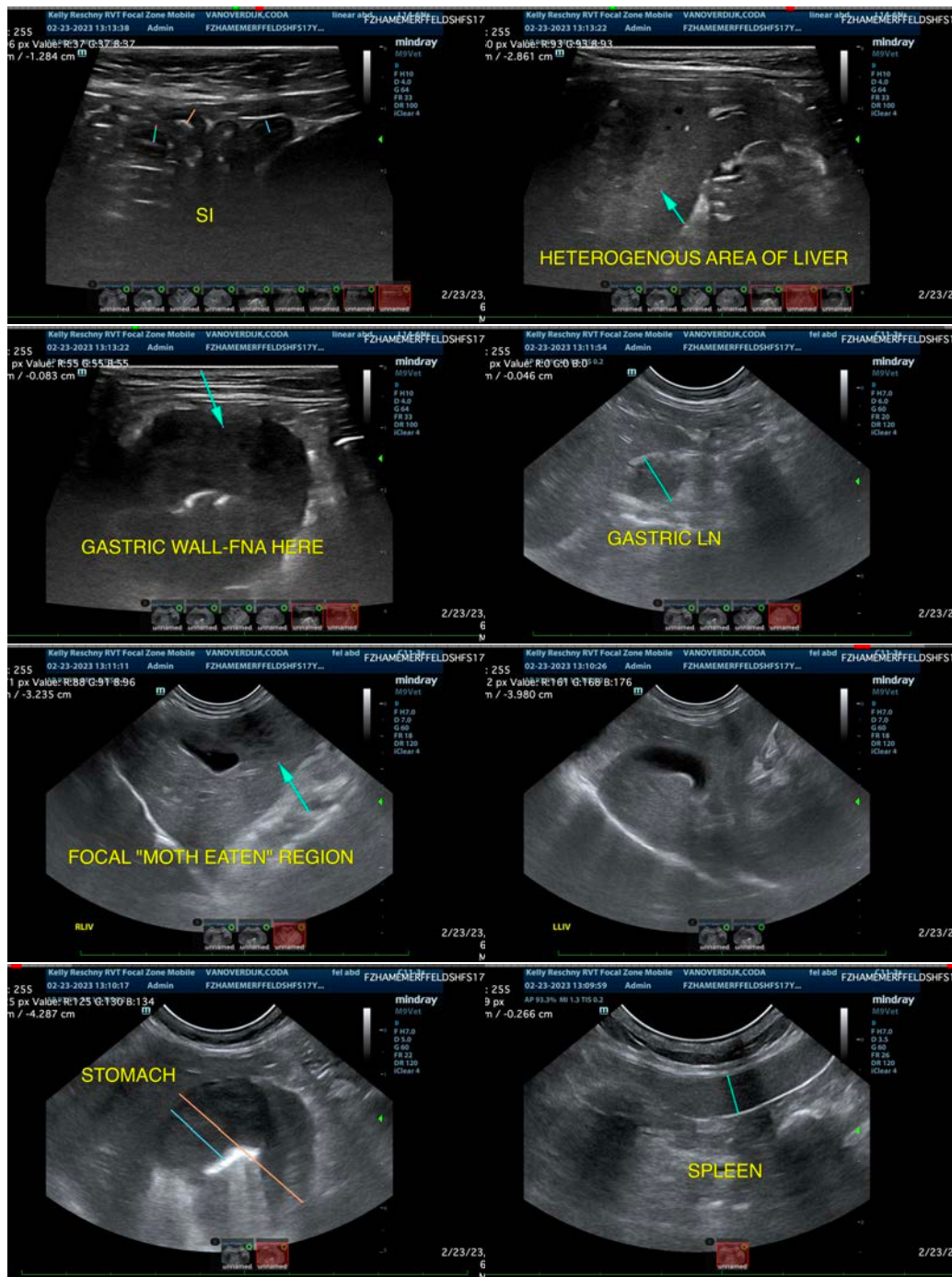
Dr. Wattson

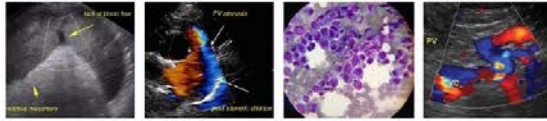
INVOICE

45450

DATE

2/23/23





PATIENT

Coda Vanoverdijk

SPECIES

Feline

BREED

DSH

SEX

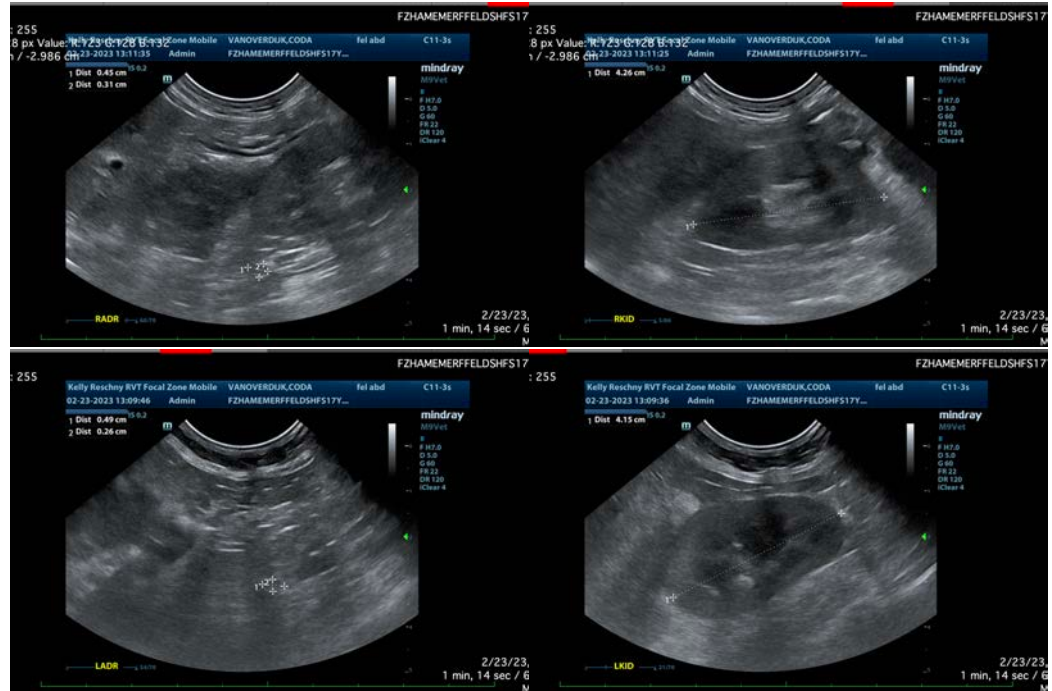
Spayed Female

AGE

17 Years

WEIGHT

2.92 kg



INTERPRETED BY

Kathleen Sennello DVM,
MS, Diplomate ACVIM
(Small Animal Internal
Medicine)

**IMAGING
PERFORMED BY**

Kelly Reschny

HOSPITAL NAME

Hamilton Region Vet
Emergency Clinic

REFERRING VET

Dr. Wattson

INVOICE

45450

DATE

2/23/23

The information and recommendations provided are based on the images presented by the referring veterinarian/sonographer. No evaluation can be communicated regarding pathology that was not visible in the image/video clips provided.

Thank you for this referral. If the clinical or image interpretation does not parallel your findings or if I can be of any further assistance please contact me.

Kathleen Sennello DVM,MS, Diplomate ACVIM (Small animal Internal Medicine)

kathleen.sennello@sonopath.com