



**PATIENT**

Bonnie Fannin

**SPECIES**

Canine

**BREED**

Chihuahua

**SEX**

Spayed Female

**AGE**

14 Years

**WEIGHT**

13 Pounds

**INTERPRETED BY**

Kathleen Sennello DVM,  
MS, Diplomate ACVIM  
(Small Animal Internal  
Medicine)

**IMAGING PERFORMED BY**

Shari Reffi, CVT

**HOSPITAL NAME**

North Jersey AH

**REFERRING VET**

Dr. Riedel

**INVOICE**

45454

**DATE**

2/23/23

**PRESENTING CLINICAL SIGNS**

Prev SP u/s 10/18/21 (attached). Continues to have problems with hematuria not responsive to ABx. Was on Zenequin in January.

Abnormal PE/Chem/CBC/UA Results: U/A-USG 1.038, rods, crystals, elevated wbc. Cysto collected today pending.

**ULTRASONOGRAPHIC EXAMINATION OF THE ABDOMEN**

**Urinary System**

The urinary bladder is moderately distended with mild primarily suspended echogenic debris present. The Bladder wall, trigone, ureteral papillae and visible urethra (to a depth of 2cm) appear normal with no evidence of wall thickening, mucosal irregularities, masses or calculi. Echogenic debris of this type can be associated with small crystals, cellular debris and proteinaceous debris.

The left kidney is normal in size (3.11 cm) but slightly irregular in shape. There is a large, irregular, mixed echogenic shadowing mass effect visualized within the cranial pole of the left kidney, measuring approximately 1.16 cm x 1.03 cm. This lesion shadows, obscuring evaluation of much of the renal parenchyma. Findings are concerning for the possibility of mineralized mass lesion. There is no evidence of pyelectasia, infarcts, or hydroureter. Renal vasculature is normal. (Previous shadowing mineralization noted in the left kidney measures 0.34 cm on 10/2021.)

The right kidney has a normal shape and size (3.0 cm). Overall echogenicity is normal with adequate corticomedullary distinction and a typical 1:3 cortex:medulla ratio. There is no evidence of focal perinephric inflammation or effusion. There is no evidence of pyelectasia, nephroliths, infarcts or hydroureter. Renal vasculature is normal.

**Adrenal Glands**

The left adrenal gland is normal in size measuring 0.52 cm at the caudal pole. It is observed in its normal position cranial to the left renal artery. It is normal in appearance (uniformly hypoechoic) and shape with no evidence of a mass effect.

The right adrenal gland is normal in size measuring 0.55 cm at the caudal pole. It is observed in its normal position between the cranial aspect of the right kidney and the caudal vena cava. It is normal in appearance (uniformly hypoechoic) and shape with no evidence of a mass effect.

**Spleen**

The spleen is subjectively normal in size, echotexture is homogenous, and the splenic capsule is smooth with no irregularities. The blood flow through the hilus and splenic parenchyma appears normal. No focal parenchymal abnormalities are visualized.

**Liver**

The liver is subjectively normal in size, and echogenicity with smooth peripheral margins. The parenchyma is homogenous echotexture. The visible portions of the vasculature and biliary tract appear normal. No focal nodules or cystic lesions are observed.

The gallbladder lumen is moderately distended. The wall of the gall bladder is not thickened and has a smooth mucosal surface. Luminal contents are mild and primarily anechoic. The cystic and common bile ducts are normal/not visible.



**PATIENT**

Bonnie Fannin

**SPECIES**

Canine

**BREED**

Chihuahua

**SEX**

Spayed Female

**AGE**

14 Years

**WEIGHT**

13 Pounds

**INTERPRETED BY**

Kathleen Sennello DVM,  
MS, Diplomate ACVIM  
(Small Animal Internal  
Medicine)

**IMAGING PERFORMED BY**

Shari Reffi, CVT

**HOSPITAL NAME**

North Jersey AH

**REFERRING VET**

Dr. Riedel

**INVOICE**

45454

**DATE**

2/23/23

**Gastrointestinal**

The stomach contains minimal luminal contents. It measures at a normal thickness of <0.7cm with some variability due to the presence of rugal folds. The distinction of the gastric wall layers is adequate and there is no impression of reduced peristaltic activity. No masses or focal lesions were observed.

The visualized areas of duodenum, jejunum and ileum have a relatively uniform diameter with minimal fluid distension. Wall thickness is normal. Bowel loops follow a curvilinear path with distinct wall layering maintaining the typical 1:3 muscularis:mucosa layer ratio. Duodenum wall measures 0.47 cm. Jejunum wall measures 0.28 cm. Visualized peristalsis appears appropriate. There is a focal section of small intestine that appears somewhat thickened and has a corrugated appearance with surrounding hyperechoic mesentery. In this region, the bowel measures at 0.47 cm. Findings are most consistent with focal enteritis, but infiltrative disease cannot be ruled out.

The ileocecal junction was visualized and exhibited normal intact wall layering and is subjectively of normal thickness. Sections of colon are visualized with formed fecal material and gas shadowing distally. There is no observed focal or generalized colon wall thickening or loss of layering.

**Pancreas**

The pancreas is normal and isoechoic to surrounding mesentery. There is no evidence of nodules or cystic lesions. There is no evidence of regional mesenteric inflammation or fluid.

**Free Abdomen**

Evaluation of the peritoneal cavity did not reveal any evidence of effusion, or subjective lymphadenomegaly. The Medial iliac nodes appear normal and there was no evidence of a caudal aortic thrombus at the bifurcation. The omentum is of normal uniform echogenicity.

**ULTRASONOGRAPHIC FINDINGS**

- Echogenic debris in the dependent portion of the urinary bladder – The echogenic debris in the bladder lumen could be consistent with cells, crystals, and/or mucus.
- Shadowing mass lesion visualized in the cranial pole of the left kidney – Findings are concerning for a mineralized mass lesion. Primary concern would be a carcinoma. Other differentials are possible.
- Focal section of bowel with thickening, corrugation, and surrounding hyperechoic mesentery – Findings are most consistent with focal enteritis but underlying infiltrative disease cannot be ruled out. Recommend reevaluation with ultrasound.

**INTERPRETATION OF THE FINDINGS & FURTHER RECOMMENDATIONS**

There is a large mineralized mass effect on the cranial pole of the left kidney on today's exam. These findings are concerning for a possible mineralized mass lesion. A primary renal carcinoma would be the most likely differential, although other possibilities exist. Recommend a blood pressure evaluation and a fine needle aspirate of this lesion, provided no hypertension is present. There was a hyperechoic focus on the previous exam 10/2021 measuring 0.36 cm (most consistent with a nephrolith). I suspect this represents progression of this lesion.

Additionally, consider 3-view thoracic radiographs and abdominal radiographs, looking for areas of mineralization. If there is no evidence of metastatic lesions, and bloodwork appears normal as well as a concentrated urine sample, you could consider referral to a veterinary surgeon for nephrectomy with histopathology and cultures.



**PATIENT**

Bonnie Fannin

**SPECIES**

Canine

**BREED**

Chihuahua

**SEX**

Spayed Female

**AGE**

14 Years

**WEIGHT**

13 Pounds

**INTERPRETED BY**

Kathleen Sennello DVM,  
MS, Diplomate ACVIM  
(Small Animal Internal  
Medicine)

**IMAGING PERFORMED BY**

Shari Reffi, CVT

**HOSPITAL NAME**

North Jersey AH

**REFERRING VET**

Dr. Riedel

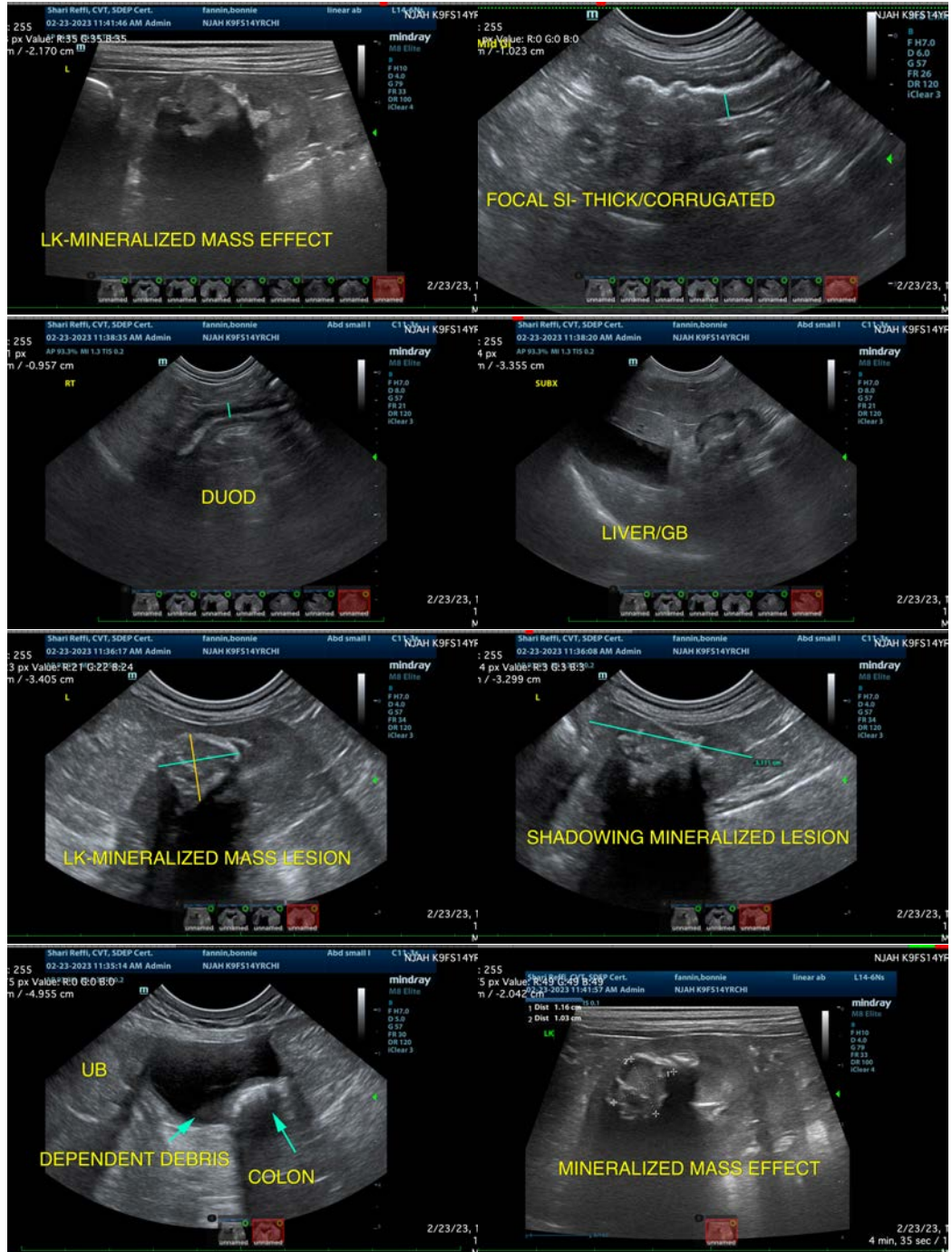
**INVOICE**

45454

**DATE**

2/23/23

There is a focal section of bowel that appears somewhat corrugated and thickened with surrounding hyperechoic mesentery. This is most consistent with focal enteritis. Correlate these findings with any symptoms of current GI disease. I cannot rule out the possibility that this could be early infiltrative disease considering this patient's other medical issues. Consider reevaluation of this area with ultrasound in 6-8 weeks or consider evaluation at the time of surgery and biopsy if this area can be identified.





**PATIENT**

Bonnie Fannin

**SPECIES**

Canine

**BREED**

Chihuahua

**SEX**

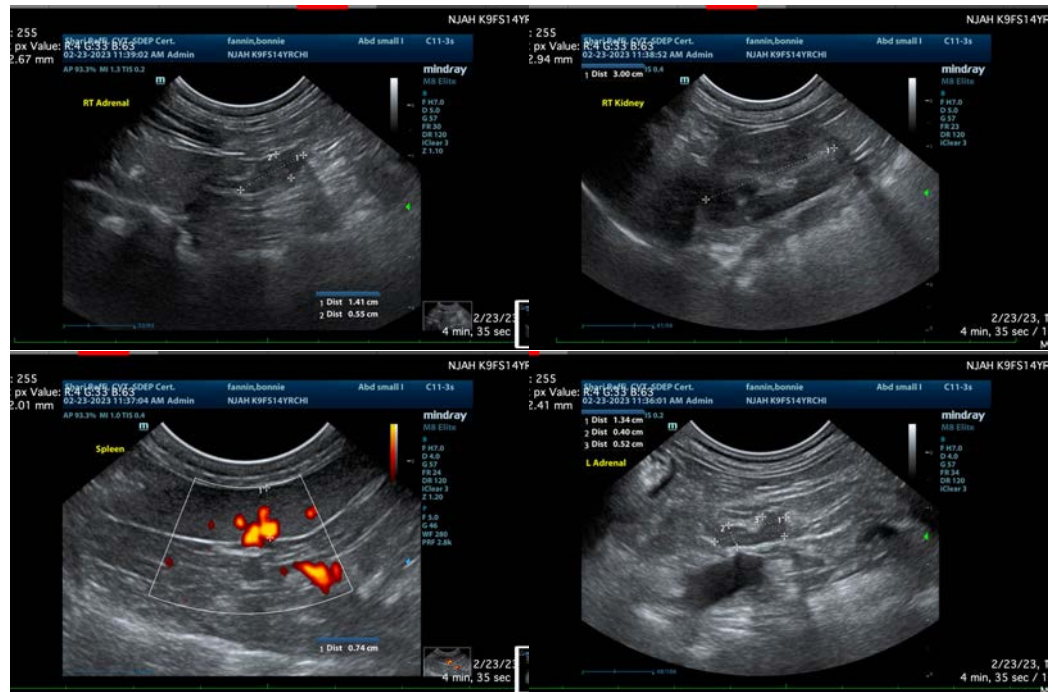
Spayed Female

**AGE**

14 Years

**WEIGHT**

13 Pounds



**INTERPRETED BY**

Kathleen Sennello DVM, MS, Diplomate ACVIM (Small Animal Internal Medicine)

**IMAGING PERFORMED BY**

Shari Reffi, CVT

**HOSPITAL NAME**

North Jersey AH

**REFERRING VET**

Dr. Riedel

**INVOICE**

45454

**DATE**

2/23/23

The information and recommendations provided are based on the images presented by the referring veterinarian/sonographer. No evaluation can be communicated regarding pathology that was not visible in the image/video clips provided.

Thank you for this referral. If the clinical or image interpretation does not parallel your findings or if I can be of any further assistance please contact me.

Kathleen Sennello DVM,MS, Diplomate ACVIM (Small animal Internal Medicine)

kathleen.sennello@sonopath.com