SonoPath
Clinical Sonography & Telecytology
EDUCATIONAL TELECONSULTATION SERVICES™
1-800-838-4268 info@sonopath.com SonoPath.com

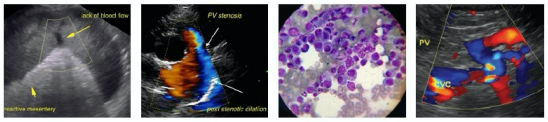

IMAGING PERFORMED BY
pawsonography@gmail.com 530-786-8340

PATIENT

Rizzo Burchmore

SPECIES

Canine

BREED

Min Pinscher

SEX

Neutered Male

AGE

8 Years

WEIGHT

35.4 Pounds

INTERPRETED BY

Kathleen Sennello DVM, MS, Diplomate ACVIM (Small Animal Internal Medicine)

IMAGING BY

Loetitia Saint-Jacques, LVT

HOSPITAL NAME

Valley Vet

REFERRING VET

Dr. Vannini

INVOICE

35826

DATE

2/23/22

PRESENTING CLINICAL SIGNS

Patients Name: Rizzo Owners first and last name: Deborah Burchmore Species: K9 Gender (altered?): neutered male Age: 8 yrs Weight (in lbs): 35.4 lbs Breed: miniature pinscher Chief Concern/Provisional Diagnosis: P chronic elevated WBC on bloodwork. No clinical signs. Diagnosis: DDX: atypical Cushing's disease, obese History/Physical Findings Physical exam: Mentation: BAR BCS: 8/9 Hydration status: euhydrated MM Pink, capillary refill time less than 2 seconds. Heart and lungs auscultate normal. OU appear normal. AU are clean in visible ear canal. Nose appears normal. Mouth appears to have grade 2/4 periodontal disease. LN are WNL. Abdomen palpates normally with no palpable masses. No signs of lameness. Most recent bw performed 12/2021, elevated WBC. P has had elevated WBC on his CBC for 1.5 years. Radiographic Abnormalities: No radiographs taken yet at this time.

ULTRASONOGRAPHIC EXAMINATION OF THE ABDOMEN

Urinary System

The urinary bladder is moderately to mildly distended with anechoic urine. The Bladder wall appears diffusely mildly thickened at 0.58 cm with an irregular mucosa. The area of the trigone, ureteral papillae and visible urethra (to a depth of 2cm) appear normal and free of any mass effects or calculi. The findings are most consistent with diffuse cystitis or lack of urine distention.

The prostate is normal in size (0.85 cm) and shape for this neutered male dog. The parenchyma is homogenous and the external margins are smooth. The prostatic urethra appears normal with no evidence of irregularity, invasion, mass effect or calculi.

The left kidney has a normal shape and size (5.41 cm). Overall echogenicity is normal with adequate corticomedullary distinction and a typical 1:3 cortex:medulla ratio. There is no evidence of perinephric inflammation or effusion. There is no evidence of pyelectasia, nephroliths, infarcts or hydroureter. Renal vasculature is normal.

The right kidney has a normal shape and size (5.65 cm). Overall echogenicity is normal with adequate corticomedullary distinction and a typical 1:3 cortex:medulla ratio. There is no evidence of perinephric inflammation or effusion. There is no evidence of pyelectasia, nephroliths, infarcts or hydroureter. Renal vasculature is normal.

Adrenal Glands

The left adrenal gland is normal in size measuring 0.52 cm at the caudal pole. It is observed in its normal position cranial to the left renal artery. It is normal in appearance (uniformly hypoechoic) and shape with no evidence of a mass effect.

The right adrenal gland is normal in size measuring 0.49 cm at the caudal pole. It is observed in its normal position between the cranial aspect of the right kidney and the caudal vena cava. It is normal in appearance (uniformly hypoechoic) and shape with no evidence of a mass effect.

Spleen

The spleen is subjectively normal in size, echotexture is homogenous, and the splenic capsule is smooth with no irregularities. The blood flow through the hilus and splenic parenchyma appears normal. No focal parenchymal abnormalities are visualized.

SonoPath
Clinical Sonography & Telecytology
EDUCATIONAL TELECONSULTATION SERVICES™
1-800-838-4268 info@sonopath.com SonoPath.com

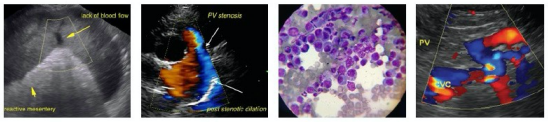

IMAGING PERFORMED BY
pawsonography@gmail.com 530-786-8340

PATIENT

Rizzo Burchmore

SPECIES

Canine

BREED

Min Pinscher

SEX

Neutered Male

AGE

8 Years

WEIGHT

35.4 Pounds

INTERPRETED BY

Kathleen Sennello DVM, MS, Diplomate ACVIM (Small Animal Internal Medicine)

IMAGING BY

Loetitia Saint-Jacques, LVT

HOSPITAL NAME

Valley Vet

REFERRING VET

Dr. Vannini

INVOICE

35826

DATE

2/23/22

Liver

The liver is large in size, and normal in echogenicity with smooth peripheral margins. The parenchyma is heterogenous in echotexture with subtle, indistinct focal mottling. The visible portions of the vasculature and biliary tract appear normal. There are numerous ill-defined hypoechoic nodules diffusely throughout the parenchyma measuring 0.77 cm, 0.88 cm, 0.64 cm, etc.

The gallbladder lumen is moderately distended. The wall of the gall bladder is not thickened and has a smooth mucosal surface. Luminal contents are primarily anechoic. The cystic and common bile ducts are normal/not visible.

Gastrointestinal

The stomach contains minimal luminal contents. It measures at a normal thickness of <0.7cm with some variability due to the presence of rugal folds. The distinction of the gastric wall layers is adequate and there is no impression of reduced peristaltic activity. No masses or focal lesions were observed.

The visualized areas of duodenum, jejunum and ileum have a relatively uniform diameter with minimal fluid distension. Wall thickness is normal. Bowel loops follow a curvilinear path with distinct wall layering maintaining the typical 1:3 muscularis:mucosa layer ratio. The duodenum measured as normal (between 0.3-0.5cm in wall thickness) and the jejunum measured as normal (between 0.2-0.47cm.) Visualized peristalsis appears appropriate. There were no focal lesions consistent with obstruction or a mass effect observed.

The ileocecal junction was visualized and exhibited normal intact wall layering and is subjectively of normal thickness. Sections of colon are visualized with formed fecal material and gas shadowing distally. There is no observed focal or generalized colon wall thickening or loss of layering.

Pancreas

The pancreas is prominent and hypoechoic as compared to the surrounding isoechoic mesentery. There is no evidence of nodules or cystic lesions. There is no evidence of regional mesenteric inflammation or fluid.

Free Abdomen

Evaluation of the peritoneal cavity did not reveal any evidence of effusion, or subjective lymphadenomegaly. The Medial iliac nodes appear normal and there was no evidence of a caudal aortic thrombus at the bifurcation. The omentum is of normal uniform echogenicity.

Other

A brief view of the heart was submitted. No significant pericardial effusion was seen.

ULTRASONOGRAPHIC FINDINGS

- Irregular bladder mucosa – The bladder mucosal changes could be consistent with cystitis or artifactual due to lack of adequate luminal distension. Bladder neoplasia cannot be ruled out but is considered unlikely in this patient.

- Prominent, hypoechoic pancreas – The pancreatic changes are most consistent with age-related parenchymal remodeling, potentially secondary to a prior inflammatory episode,

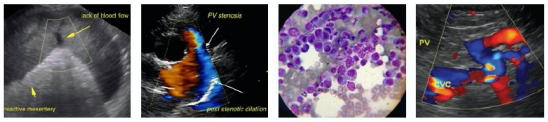

PATIENT

Rizzo Burchmore

SPECIES

Canine

BREED

Min Pinscher

SEX

Neutered Male

AGE

8 Years

WEIGHT

35.4 Pounds

INTERPRETED BY

Kathleen Sennello DVM, MS, Diplomate ACVIM (Small Animal Internal Medicine)

IMAGING BY

Loetitia Saint-Jacques, LVT

HOSPITAL NAME

Valley Vet

REFERRING VET

Dr. Vannini

INVOICE

35826

DATE

2/23/22

early fibrosis or chronic pancreatitis.

- Large, heterogeneous liver with diffuse hypoechoic nodules – The diffuse hepatic changes are non-specific and could be consistent with vacuolar hepatopathy, nodular hyperplasia, inflammatory/immune-mediated disease, fibrosis, extramedullary hematopoiesis, toxic hepatopathy (e.g., copper), infiltrative neoplasia (less likely) or other hepatopathy.

INTERPRETATION OF THE FINDINGS & FURTHER RECOMMENDATIONS

The liver appears large and heterogeneous, and has diffuse ill-defined hypoechoic nodules throughout it. Recommend a fine needle aspirate. If liver enzyme elevations are present, consider a liver function test, etc. (lab work not include to make further recommendations).

Additionally, the white blood cell count is reported to be elevated. If this is primarily lymphocytes, then consider pathologist review of the blood smear to look for atypical lymphocytes. Additionally, a pathologist review can be helpful in looking for atypical cells and characterizing the leukocytosis.

The bladder wall appears somewhat irregular. Recommend urinalysis and culture. This could be due to cystitis or lack of urine distention.

Consider three view thoracic radiographs to rule out concurrent thoracic disease/involvement.

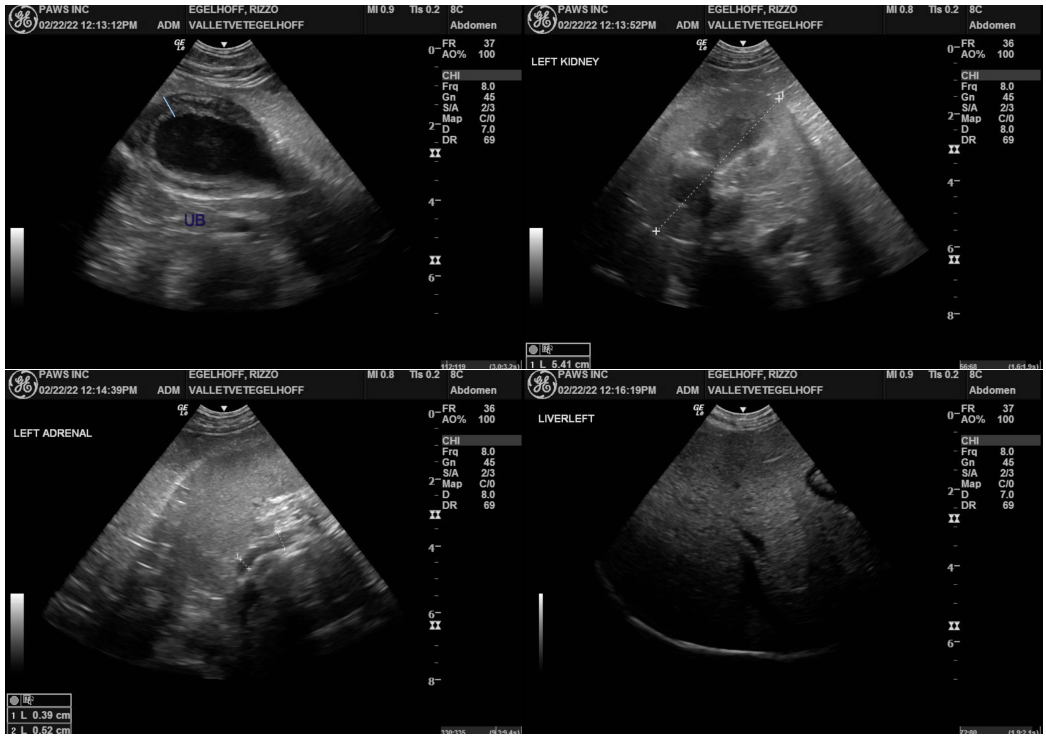

SonoPath
Clinical Sonography & Telecytology

EDUCATIONAL TELECONSULTATION SERVICES™
1-800-838-4268 info@sonopath.com SonoPath.com

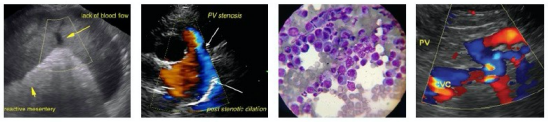

Portable Animal Western Sonography, Inc.

IMAGING PERFORMED BY
pawsonography@gmail.com 530-786-8340

PATIENT

Rizzo Burchmore

SPECIES

Canine

BREED

Min Pinscher

SEX

Neutered Male

AGE

8 Years

WEIGHT

35.4 Pounds

INTERPRETED BY

Kathleen Sennello DVM, MS, Diplomate ACVIM (Small Animal Internal Medicine)

IMAGING BY

Loetitia Saint-Jacques, LVT

HOSPITAL NAME

Valley Vet

REFERRING VET

Dr. Vannini

INVOICE

35826

DATE

2/23/22

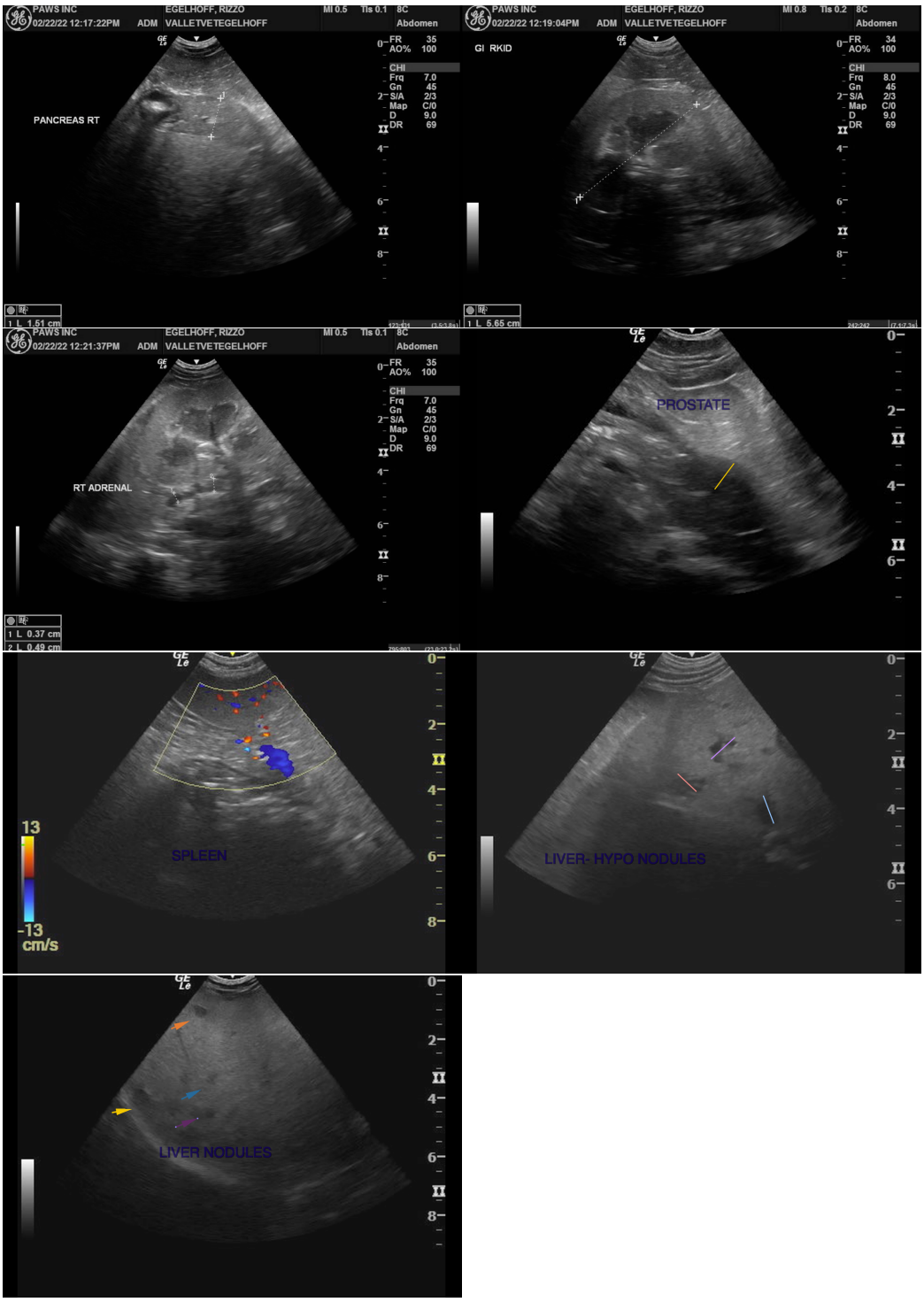

SonoPath
Clinical Sonography & Telecytology
EDUCATIONAL TELECONSULTATION SERVICES™
1-800-838-4268 info@sonopath.com SonoPath.com

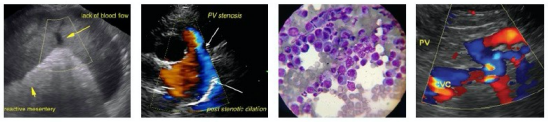

Portable Animal Western Sonography, Inc.
IMAGING PERFORMED BY
pawsonography@gmail.com 530-786-8340

PATIENT

Rizzo Burchmore

SPECIES

Canine

BREED

Min Pinscher

SEX

Neutered Male

AGE

8 Years

WEIGHT

35.4 Pounds

INTERPRETED BY

Kathleen Sennello DVM, MS, Diplomate ACVIM (Small Animal Internal Medicine)

IMAGING BY

Loetitia Saint-Jacques, LVT

HOSPITAL NAME

Valley Vet

REFERRING VET

Dr. Vannini

INVOICE

35826

DATE

2/23/22

The information and recommendations provided are based on the images presented by the referring veterinarian/sonographer. No evaluation can be communicated regarding pathology that was not visible in the image/video clips provided.

Thank you for this referral. If the clinical or image interpretation does not parallel your findings or if I can be of any further assistance please contact me.

Kathleen Sennello DVM,MS, Diplomate ACVIM (Small animal Internal Medicine)
kathleen.sennello@sonopath.com