

PATIENT PRESENTING CLINICAL SIGNS

Keisha Davidson chronic diarrhea (approx 2 months) not responsive to antibiotics, fecal PCR neg, started after dental in Dec 2021. currently on gabapentin.
Abnormal PE/Chem/CBC/UA Results: please see attached labs

SPECIES

Feline

ULTRASONOGRAPHIC EXAMINATION OF THE ABDOMEN

Urinary System

BREED

Devon Rex

The urinary bladder is moderately distended with anechoic urine. The Bladder wall, trigone, ureteral papillae and visible urethra (to a depth of 2cm) appear normal with no evidence of wall thickening, mucosal irregularities, masses or cystic calculi.

SEX

Spayed Female

The left kidney has a normal shape and size (3.72 cm). Overall echogenicity is normal with adequate corticomedullary distinction and a typical 1:3 cortex:medulla ratio. There is no evidence of perinephric inflammation or effusion. There is no evidence of pyelectasia, nephroliths, infarcts or hydronephrosis. Renal vasculature is normal.

AGE

8 Years

The right kidney has a normal shape and size (3.86 cm). Overall echogenicity is normal with adequate corticomedullary distinction and a typical 1:3 cortex:medulla ratio. There is no evidence of perinephric inflammation or effusion. There is no evidence of pyelectasia, nephroliths, infarcts or hydronephrosis. Renal vasculature is normal.

WEIGHT

4.79 kg

Adrenal Glands

The left adrenal gland is normal in size measuring 0.29 cm at the caudal pole. It is observed in its normal position cranial to the left renal artery. It is normal in appearance (uniformly hypoechoic) and shape with no evidence of a mass effect.

INTERPRETED BY

Kathleen Sennello DVM,
MS, Diplomate ACVIM
(Small Animal Internal
Medicine)

The right adrenal gland is normal in size measuring 0.19 cm at the caudal pole. It is observed in its normal position between the cranial aspect of the right kidney and the caudal vena cava. It is normal in appearance (uniformly hypoechoic) and shape with no evidence of a mass effect.

IMAGING PERFORMED BY

Kelly Reschny

Spleen

The spleen is subjectively normal in size (0.8 cm at the level of the hilus), echotexture is homogenous, and the splenic capsule is smooth with no irregularities. The blood flow through the hilus and splenic parenchyma appears normal. No focal parenchymal abnormalities are visualized.

HOSPITAL NAME

Sixteen Mile VC

Liver

The liver is subjectively normal in size, and echogenicity with smooth peripheral margins. The parenchyma is homogenous echotexture. The visible portions of the vasculature and biliary tract appear normal. No focal nodules or cystic lesions are observed.

REFERRING VET

Dr. Bile

The gallbladder lumen is moderately distended. The wall of the gall bladder is not thickened and has a smooth mucosal surface. Luminal contents are primarily anechoic. The cystic and common bile ducts are normal/not visible.

INVOICE

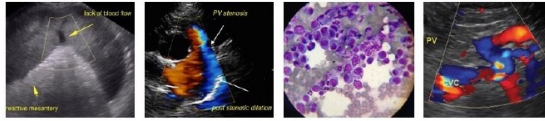
35836

Gastrointestinal

The stomach contains minimal luminal contents. It measures at a normal thickness of <0.36cm with some variability due to the presence of rugal folds. The distinction of the gastric wall layers is adequate and there is no impression of reduced peristaltic activity. No masses or focal lesions were observed.

DATE

2/23/22



PATIENT

Keisha Davidson

SPECIES

Feline

BREED

Devon Rex

SEX

Spayed Female

AGE

8 Years

WEIGHT

4.79 kg

INTERPRETED BY

Kathleen Sennello DVM,
MS, Diplomate ACVIM
(Small Animal Internal
Medicine)

IMAGING PERFORMED BY

Kelly Reschny

HOSPITAL NAME

Sixteen Mile VC

REFERRING VET

Dr. Bile

INVOICE

35836

DATE

2/23/22

The visualized areas of duodenum, jejunum and ileum have a uniform diameter with minimal fluid distension. Wall thickness is normal to slightly increased. Bowel loops follow a typical curvilinear path with distinct wall layering, but some areas display a prominent muscularis layer which does not display the typical 1:3 muscularis:mucosa layer ratio. Jejunum wall measured 0.28 cm. Visualized peristalsis appears appropriate. There were no focal lesions consistent with obstruction or a mass effect observed.

The ileocecal junction was visualized and exhibited normal intact wall layering and is subjectively of normal thickness. Sections of colon are visualized with formed fecal material and gas shadowing distally. There is no observed focal or generalized colon wall thickening or loss of layering.

Pancreas

The pancreas is normal and isoechoic to surrounding mesentery. There is no evidence of nodules or cystic lesions. There is no evidence of regional mesenteric inflammation or fluid.

Free Abdomen

Evaluation of the peritoneal cavity did not reveal any evidence of effusion, or subjective lymphadenomegaly. The Medial iliac nodes appear normal and there was no evidence of a caudal aortic thrombus at the bifurcation. The omentum is of normal uniform echogenicity.

ULTRASONOGRAPHIC FINDINGS

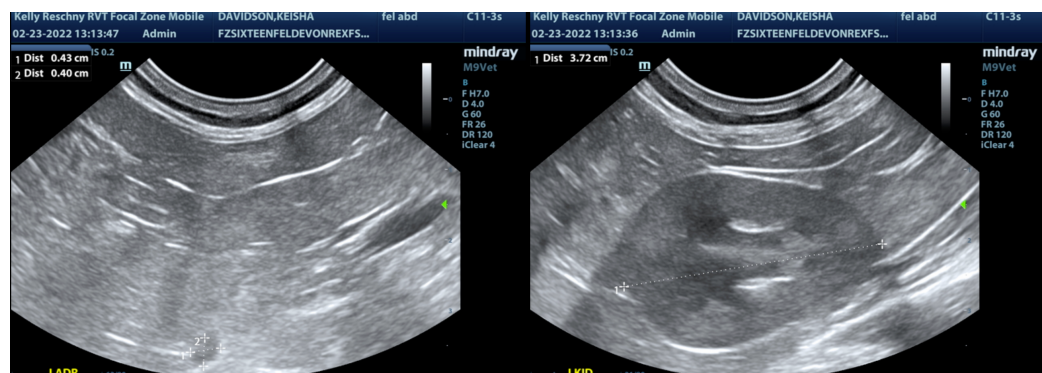
- Prominent muscularis layer to the small intestine – The small intestinal wall changes are most consistent with an inflammatory process (i.e., inflammatory bowel disease) with a low possibility of emerging lymphoma This can be a normal finding in older cats.

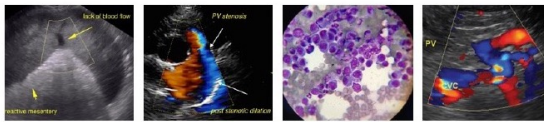
INTERPRETATION OF THE FINDINGS & FURTHER RECOMMENDATIONS

No focal lesions were visualized in the GI tract to explain the diarrhea reported in the history. Consider possible metabolic causes. Lab work appears relatively normal. Additionally consider testing for Addison's disease due to the elevated potassium level.

Primary GI signs are most likely. Differentials to consider would be food allergy/dietary intolerance, GI parasites (seems unlikely based on previous testing), bacterial dysbiosis, IBD, and less likely intestinal neoplasia. Bacterial dysbiosis would be more likely if it started after systemic antibiotics (were these dispensed at time of dental?).

- Consider a hydrolyzed protein/novel protein diet.
- Recommend chronic probiotic therapy. If already doing this, consider a different probiotic.
- If dysbiosis is thought likely, you could consider a fecal transplant.
- If there is no response to these therapies, recommend obtaining GI biopsies.
- Consider three view thoracic radiographs to rule out concurrent thoracic disease/involvement.





PATIENT

Keisha Davidson

SPECIES

Feline

BREED

Devon Rex

SEX

Spayed Female

AGE

8 Years

WEIGHT

4.79 kg

INTERPRETED BY

Kathleen Sennello DVM,
MS, Diplomate ACVIM
(Small Animal Internal
Medicine)

IMAGING PERFORMED BY

Kelly Reschny

HOSPITAL NAME

Sixteen Mile VC

REFERRING VET

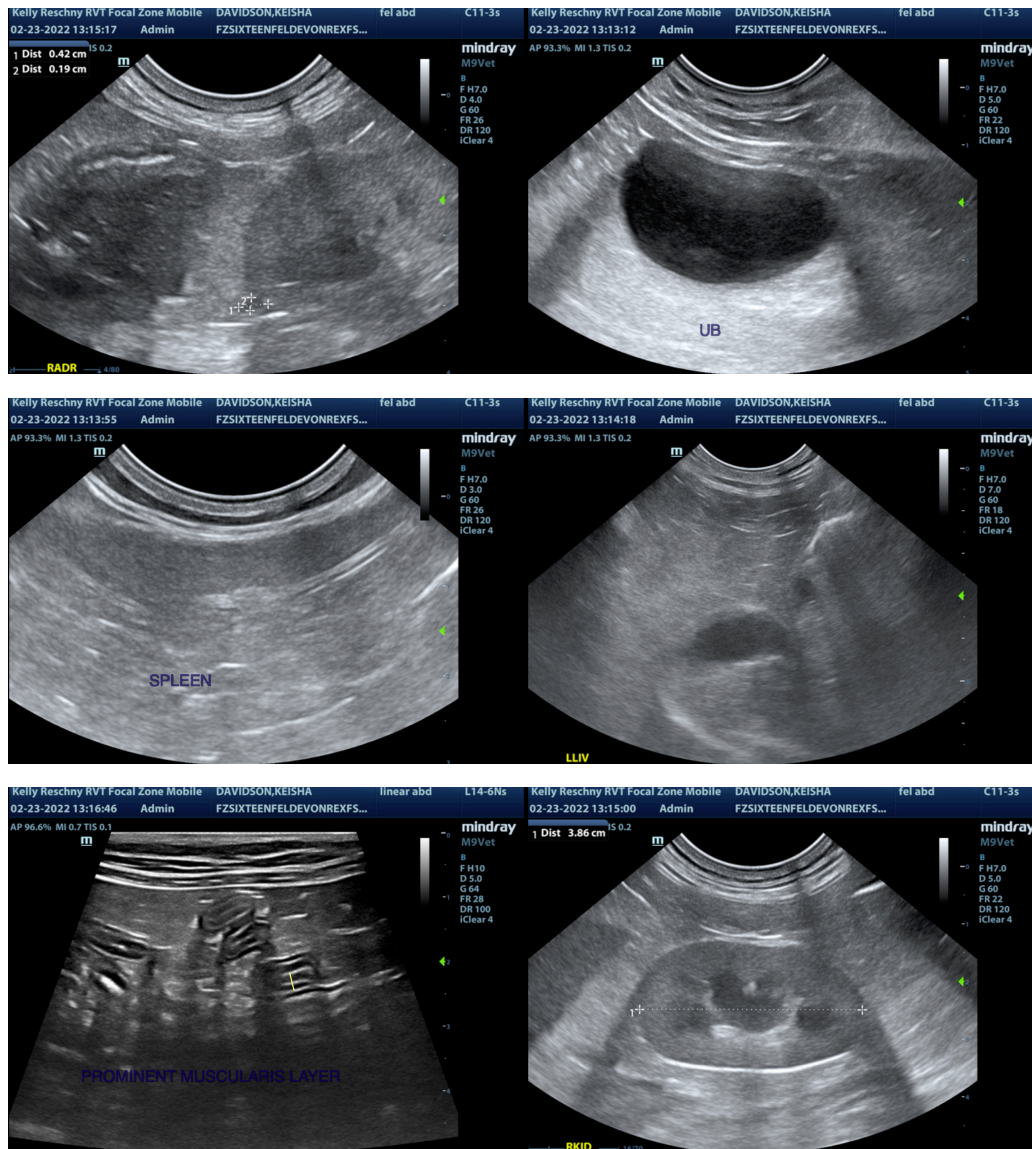
Dr. Bile

INVOICE

35836

DATE

2/23/22



The information and recommendations provided are based on the images presented by the referring veterinarian/sonographer. No evaluation can be communicated regarding pathology that was not visible in the image/video clips provided.

Thank you for this referral. If the clinical or image interpretation does not parallel your findings or if I can be of any further assistance please contact me.

Kathleen Sennello DVM,MS, Diplomate ACVIM (Small animal Internal Medicine)

kathleen.sennello@sonopath.com