



**PATIENT**

Holly Go Lightly  
Schragen

**SPECIES**

Feline

**BREED**

Ragdoll

**SEX**

Spayed Female

**AGE**

13 Years

**WEIGHT**

9.7 Pounds

**INTERPRETED BY**

Kathleen Sennello DVM,  
MS, Diplomate ACVIM  
(Small Animal Internal  
Medicine)

**IMAGING  
PERFORMED BY**

Dr. Sorbo

**HOSPITAL NAME**

Back Bay VC

**REFERRING VET**

Dr. Sorbo

**INVOICE**

35824

**DATE**

2/23/22

**PRESENTING CLINICAL SIGNS**

Unexplained weight loss over 4-6months. Soft stools on occasion.  
Abnormal PE/Chem/CBC/UA Results: Dental disease, but no overt lesions. Unremarkable except for weight loss. Very sweet cat. ALP mild elevation, UPC 0.3. Attached for reference.

**ULTRASONOGRAPHIC EXAMINATION OF THE ABDOMEN**

**Urinary System**

The urinary bladder is moderately distended with anechoic urine. The Bladder wall, trigone, ureteral papillae and visible urethra (to a depth of 2cm) appear normal with no evidence of wall thickening, mucosal irregularities, masses or cystic calculi.

The left kidney has a normal shape and size (3.8 cm). Overall echogenicity is normal with adequate corticomedullary distinction and a typical 1:3 cortex:medulla ratio. There is no evidence of perinephric inflammation or effusion. There is no evidence of pyelectasia, nephroliths, infarcts or hydroureter. Renal vasculature is normal.

The right kidney has a normal shape and size (4.0 cm). Overall echogenicity is normal with adequate corticomedullary distinction and a typical 1:3 cortex:medulla ratio. There is no evidence of perinephric inflammation or effusion. There is no evidence of pyelectasia, nephroliths, infarcts or hydroureter. Renal vasculature is normal.

**Adrenal Glands**

The left adrenal gland is normal in size measuring 0.37 cm at the caudal pole. It is observed in its normal position cranial to the left renal artery. It is normal in appearance (uniformly hypoechoic) and shape with no evidence of a mass effect.

The right adrenal gland is normal in size measuring 0.48 cm at the caudal pole. It is observed in its normal position between the cranial aspect of the right kidney and the caudal vena cava. It is normal in appearance (uniformly hypoechoic) and shape with no evidence of a mass effect.

**Spleen**

The spleen is subjectively normal in size, echotexture is homogenous, and the splenic capsule is smooth with no irregularities. The blood flow through the hilus and splenic parenchyma appears normal. There is a 0.3 cm hyperechoic nodule visualized within the parenchyma.

**Liver**

The liver is subjectively normal in size, and echogenicity with smooth peripheral margins. The parenchyma is homogenous echotexture. The visible portions of the vasculature and biliary tract appear normal. No focal nodules or cystic lesions are observed.

The gallbladder lumen is moderately distended. The wall of the gall bladder is not thickened and has a smooth mucosal surface. Luminal contents are primarily anechoic. The bile duct is visualized at measured at 0.22 cm.

**Gastrointestinal**

The stomach contains minimal luminal contents. It measures at a normal thickness of <0.36cm with some variability due to the presence of rugal folds. The distinction of the gastric wall layers is adequate and there is no impression of reduced peristaltic activity. No masses or focal lesions were observed.



**PATIENT**

Holly Go Lightly Schragen

**SPECIES**

Feline

**BREED**

Ragdoll

**SEX**

Spayed Female

**AGE**

13 Years

**WEIGHT**

9.7 Pounds

**INTERPRETED BY**

Kathleen Sennello DVM,  
MS, Diplomate ACVIM  
(Small Animal Internal  
Medicine)

**IMAGING  
PERFORMED BY**

Dr. Sorbo

**HOSPITAL NAME**

Back Bay VC

**REFERRING VET**

Dr. Sorbo

**INVOICE**

35824

**DATE**

2/23/22

The visualized areas of duodenum, jejunum and ileum have a uniform diameter with minimal fluid distension. Wall thickness is normal to slightly increased. Bowel loops follow a typical curvilinear path with distinct wall layering, but some areas display a prominent muscularis layer which does not display the typical 1:3 muscularis:mucosa layer ratio. Jejunum wall measured 0.30 cm. Visualized peristalsis appears appropriate. While wall layering is intact throughout the small intestine, some areas of bowel appear hypoechoic with reduced distinction of layering.

The ileocecal junction was visualized and exhibited normal intact wall layering and is subjectively of normal thickness. Sections of colon are visualized with formed fecal material and gas shadowing distally. There is no observed focal or generalized colon wall thickening or loss of layering.

***Pancreas***

The pancreas is normal and isoechoic to surrounding mesentery. There is no evidence of nodules or cystic lesions. There is no evidence of regional mesenteric inflammation or fluid.

***Free Abdomen***

Evaluation of the peritoneal cavity did not reveal any evidence of effusion. There is a diffuse mild mesenteric lymphadenopathy visualized with mesenteric lymph node measures 0.52 cm, 0.47 cm, 0.68 cm, 0.41 cm, 0.45 cm. The omentum is of increased echogenicity around the prominent mesenteric lymph nodes.

**ULTRASONOGRAPHIC FINDINGS**

- Hyperechoic nodule within the spleen – Findings could be consistent with either a benign or neoplastic lesion. Overall, this lesion has a somewhat benign appearance, but a fine needle aspirate would be necessary to differentiate.
- Thickened small intestine with prominent muscularis layer – The small intestinal wall changes are most consistent with an inflammatory process (i.e., inflammatory bowel disease) with a low possibility of emerging lymphoma.
- Prominent mesenteric lymph nodes – The prominent abdominal lymph nodes are most consistent with reactive lymphadenitis or lymphoid hyperplasia. Neoplastic infiltration is considered less likely.

**INTERPRETATION OF THE FINDINGS & FURTHER RECOMMENDATIONS**

No focal bowel masses or focal thickening was visualized, but there is the overall impression of diffuse thickening, prominent muscularis layer, and some areas are hypoechoic with a reduced distinction of wall layering. These changes are most consistent with inflammatory or infiltrative disease. In a cat this age, the primary differentials would be dietary intolerance/food allergy, IBD, or neoplasia. Prior to a GI workup, confirm there is no evidence of metabolic disease including thyroid and pancreatic function.

- Recommend a GI panel to Texas A&M for a qualitative fPLI, TLI, cobalamin and folate to further evaluate the small intestine and pancreas.
- Recommend a hydrolyzed protein or novel protein prescription diet.
- Recommend probiotic therapy.
- If symptoms persist, consider obtaining GI biopsies.
- A fine needle aspirate of a mesenteric lymph node could be attempted.
- Consider three view thoracic radiographs to rule out concurrent thoracic disease/involvement.



**PATIENT**

Holly Go Lightly  
Schragen

**SPECIES**

Feline

**BREED**

Ragdoll

**SEX**

Spayed Female

**AGE**

13 Years

**WEIGHT**

9.7 Pounds

**INTERPRETED BY**

Kathleen Sennello DVM,  
MS, Diplomate ACVIM  
(Small Animal Internal  
Medicine)

**IMAGING  
PERFORMED BY**

Dr. Sorbo

**HOSPITAL NAME**

Back Bay VC

**REFERRING VET**

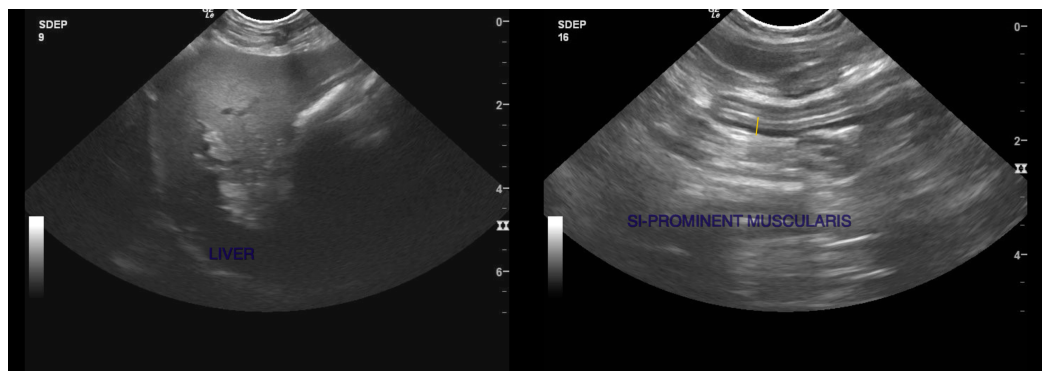
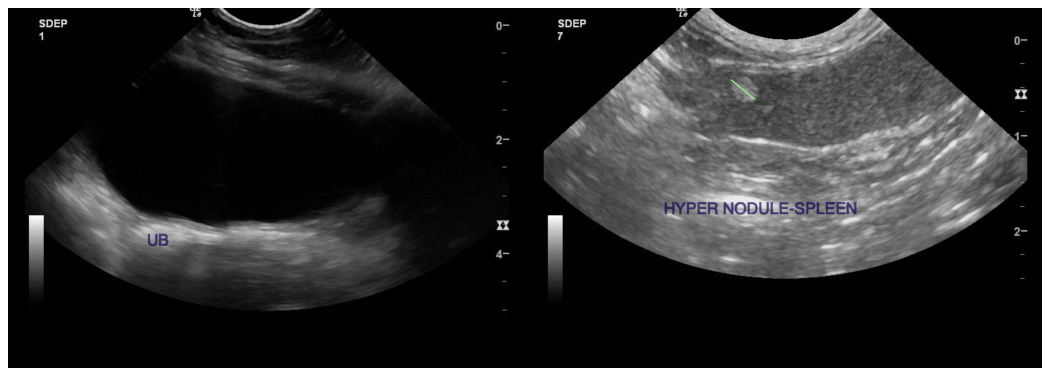
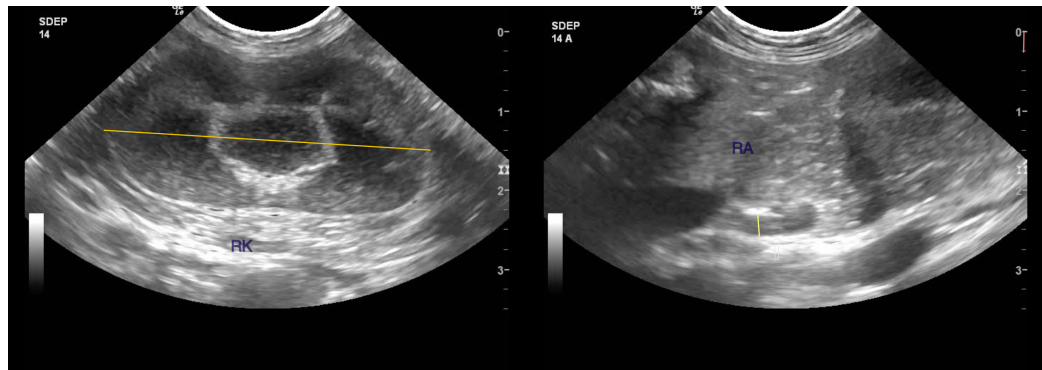
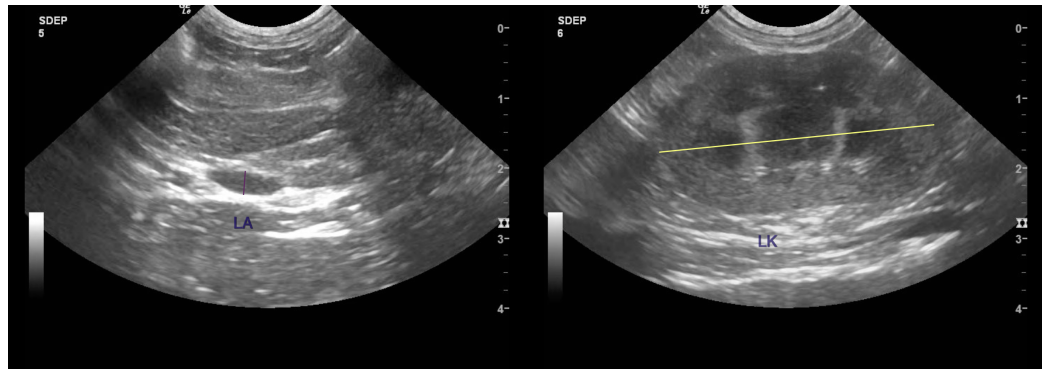
Dr. Sorbo

**INVOICE**

35824

**DATE**

2/23/22





**PATIENT**

Holly Go Lightly  
Schragen

**SPECIES**

Feline

**BREED**

Ragdoll

**SEX**

Spayed Female

**AGE**

13 Years

**WEIGHT**

9.7 Pounds

**INTERPRETED BY**

Kathleen Sennello DVM,  
MS, Diplomate ACVIM  
(Small Animal Internal  
Medicine)

**IMAGING  
PERFORMED BY**

Dr. Sorbo

**HOSPITAL NAME**

Back Bay VC

**REFERRING VET**

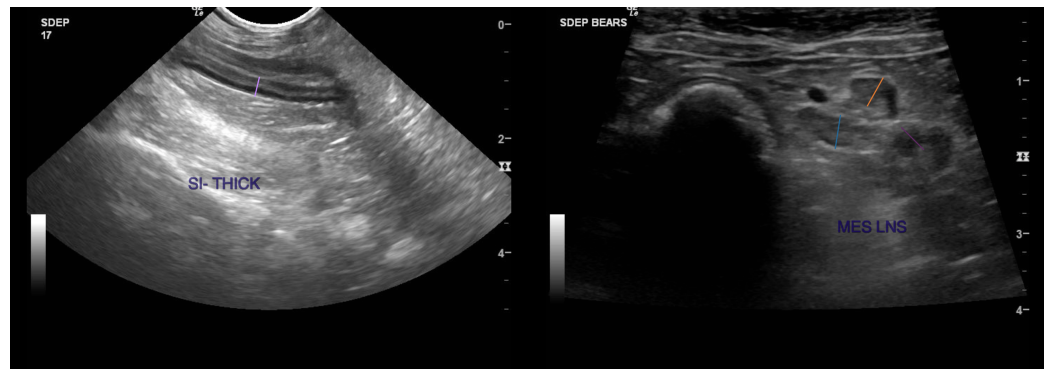Dr. Sorbo

**INVOICE**

35824

**DATE**

2/23/22



The information and recommendations provided are based on the images presented by the referring veterinarian/sonographer. No evaluation can be communicated regarding pathology that was not visible in the image/video clips provided.

Thank you for this referral. If the clinical or image interpretation does not parallel your findings or if I can be of any further assistance please contact me.

Kathleen Sennello DVM,MS, Diplomate ACVIM (Small animal Internal Medicine)

kathleen.sennello@sonopath.com