



PATIENT

Ginger Barnett

PRESENTING CLINICAL SIGNS

SPECIES

Feline

Pt presented today for abdominal ultrasound. Focusing on bladder pt has been having chronic UTI's since 12/13/21. Pt has tried multiple trials of different anti-biotics. Pt has had urinalysis and cultures done on urine and infection as never cleared up completely. Dr. Nolet recommended ultrasound to rule out bladder stones, and/or tumor

BREED

DLH

ULTRASONOGRAPHIC EXAMINATION OF THE ABDOMEN

Urinary System

The urinary bladder is moderately distended with anechoic urine. The Bladder wall, trigone, ureteral papillae and visible urethra (to a depth of 2cm) appear normal with no evidence of wall thickening, mucosal irregularities, or masses. In the dependent portion of the urinary bladder, there is a small line of mineralized shadowing sandy debris and mild mucosal irregularity. Findings are most consistent with cystitis and mild dependent sandy debris/small stones.

SEX

Spayed Female

AGE

2 Years 8 Months

The left kidney has a normal shape and size (4.07 cm). Overall echogenicity is normal with adequate corticomedullary distinction and a typical 1:3 cortex:medulla ratio. There is no evidence of perinephric inflammation or effusion. There is no evidence of pyelectasia, nephroliths, infarcts or hydroureter. Renal vasculature is normal.

WEIGHT

11.4 Pounds

The right kidney has a normal shape and size (3.54 cm). Overall echogenicity is normal with adequate corticomedullary distinction and a typical 1:3 cortex:medulla ratio. There is no evidence of perinephric inflammation or effusion. There is no evidence of pyelectasia, nephroliths, infarcts or hydroureter. Renal vasculature is normal.

INTERPRETED BY

Kathleen Sennello DVM,
MS, Diplomate ACVIM
(Small Animal Internal
Medicine)

Adrenal Glands

The left adrenal gland is normal in size measuring 0.36 cm at the caudal pole. It is observed in its normal position cranial to the left renal artery. It is normal in appearance (uniformly hypoechoic) and shape with no evidence of a mass effect.

The right adrenal gland is normal in size measuring 0.37 cm at the caudal pole. It is observed in its normal position between the cranial aspect of the right kidney and the caudal vena cava. It is normal in appearance (uniformly hypoechoic) and shape with no evidence of a mass effect.

IMAGING BY

Loetitia Saint-Jacques,
LVT

Spleen

The spleen is subjectively normal in size, echotexture is homogenous, and the splenic capsule is smooth with no irregularities. The blood flow through the hilus and splenic parenchyma appears normal. No focal parenchymal abnormalities are visualized.

HOSPITAL NAME

Pine Creek VC

Liver

The liver is subjectively normal in size, and echogenicity with smooth peripheral margins. The parenchyma is homogenous echotexture. The visible portions of the vasculature and biliary tract appear normal. No focal nodules or cystic lesions are observed.

REFERRING VET

Dr. Denny Nolet

The gallbladder It has the appearance of 3 separate lobes. Some of these can be visualized opening directly into a bile duct. The wall of the gallbladder appears normal and not thickened, with a smooth mucosal surface. Luminal contents are primarily anechoic. The cystic and common bile ducts are normal/not visible.

INVOICE

35852

DATE

2/23/22



PATIENT

Ginger Barnett

SPECIES

Feline

BREED

DLH

SEX

Spayed Female

AGE

2 Years 8 Months

WEIGHT

11.4 Pounds

INTERPRETED BY

Kathleen Sennello DVM,
MS, Diplomate ACVIM
(Small Animal Internal
Medicine)

IMAGING BY

Loetitia Saint-Jacques,
LVT

HOSPITAL NAME

Pine Creek VC

REFERRING VET

Dr. Denny Nolet

INVOICE

35852

DATE

2/23/22

Gastrointestinal

The stomach contains minimal luminal contents. It measures at a normal thickness of <0.36cm with some variability due to the presence of rugal folds. The distinction of the gastric wall layers is adequate and there is no impression of reduced peristaltic activity. No masses or focal lesions were observed.

The visualized areas of duodenum, jejunum and ileum have a relatively uniform diameter with minimal fluid distension. Wall thickness is normal. Bowel loops follow a curvilinear path with distinct wall layering maintaining the typical 1:3 muscularis:mucosa layer ratio. Jejunum wall measured 0.21 cm. Visualized peristalsis appears appropriate. There is a section of jejunum where the wall layering detail appears somewhat hazy and indistinct. Recommend re-evaluation if GI signs or weight loss occurs.

The ileocecal junction was visualized and exhibited normal intact wall layering and is subjectively of normal thickness. Sections of colon are visualized with formed fecal material and gas shadowing distally. There is no observed focal or generalized colon wall thickening or loss of layering.

Pancreas

The pancreas is normal and isoechoic to surrounding mesentery. There is no evidence of nodules or cystic lesions. There is no evidence of regional mesenteric inflammation or fluid.

Free Abdomen

Evaluation of the peritoneal cavity did not reveal any evidence of effusion. There are prominent mesenteric lymph nodes, particularly around the ileocecal junction, measuring 0.34 cm and 0.37 cm. The omentum is of normal echogenicity.

Other


A brief view of the heart was submitted. No significant pericardial effusion was seen.

PRIMARY FINDINGS

- Trilobed gallbladder – Likely an incidental finding, but there is some concern with a congenital anomaly that there could be additional congenital anomalies.
- Mineralized/sandy debris (small stones?) in the dependent portion of the urinary bladder – Correlate with abdominal radiographs and urinalysis findings.
- Prominent mesenteric lymph nodes – The prominent abdominal lymph nodes are most consistent with reactive lymphadenitis or lymphoid hyperplasia. Neoplastic infiltration is considered less likely. This can be a common finding in younger animals.

SECONDARY FINDINGS

- Questionable reduced detail of the small intestine



PATIENT

Ginger Barnett

INTERPRETATION OF THE FINDINGS & FURTHER RECOMMENDATIONS

SPECIES

Feline

No dramatic lesions were visualized associated with the urinary tract. There is some dependent sandy debris and irregularity present. Correlate with abdominal radiographs to try to determine if these are visible. I suspect this mineralization is small enough to be passed. If able to evaluate a urinalysis on a fresh voided sample, you may be more likely to get information regarding the mineralization. Recommend diligent culture and sensitivity testing and treatment based on these results to avoid resistance. I typically recommend treating based on culture and sensitivity results, a recheck culture mid treatment to ensure the infection is being addressed, and then another culture one-week post-treatment.

BREED

DLH

SEX

Spayed Female

Possible considerations in a young animal like this would be an ectopic ureter or portosystemic shunt, particularly with the gallbladder anomaly observed. I do not see evidence of these lesions, but they can be very small and difficult to pick up without contrast. Consider a liver function test. If bile acids are significantly elevated, consider a contrast CT scan of the liver. If bile acids are normal, you could consider a contrast CT scan of the kidneys and bladder to look for a small ectopic ureter. Additionally, consider vaginal exam to look for any anatomic abnormalities.

AGE

2 Years 8 Months

WEIGHT

11.4 Pounds

INTERPRETED BY

Kathleen Sennello DVM,
MS, Diplomate ACVIM
(Small Animal Internal
Medicine)

IMAGING BY

Loetitia Saint-Jacques,
LVT

HOSPITAL NAME

Pine Creek VC

REFERRING VET

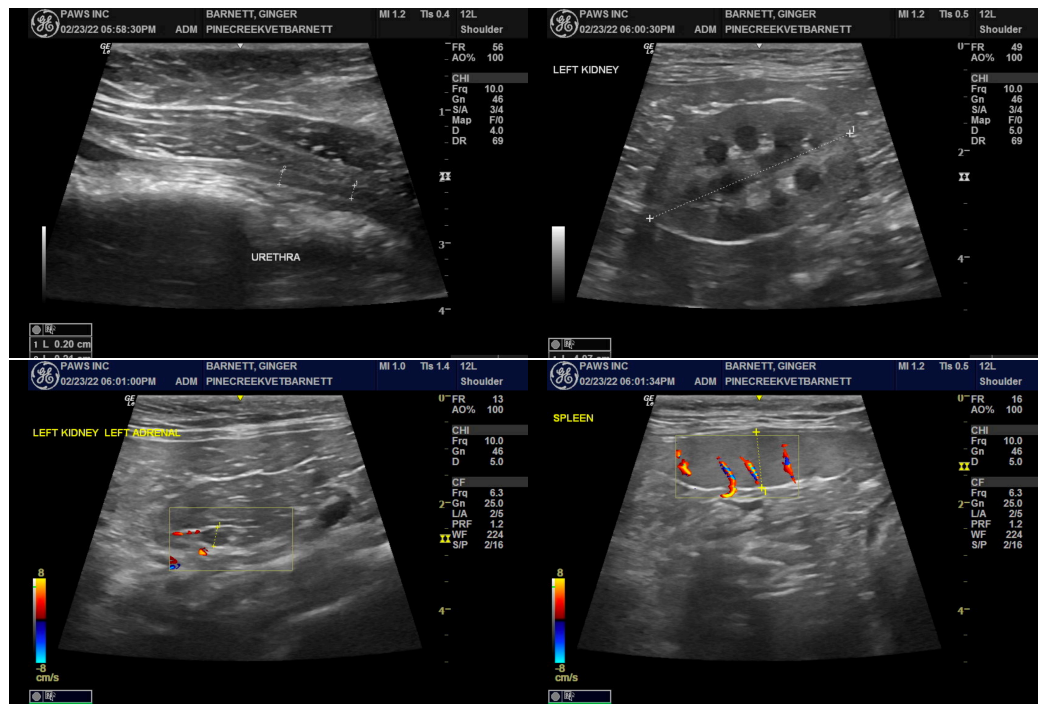
Dr. Denny Nolet

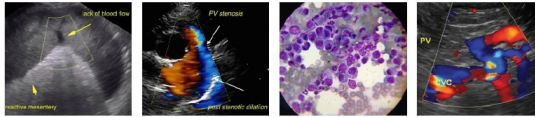
INVOICE

35852

DATE

2/23/22





PATIENT

Ginger Barnett

SPECIES

Feline

BREED

DLH

SEX

Spayed Female

AGE

2 Years 8 Months

WEIGHT

11.4 Pounds

INTERPRETED BY

Kathleen Sennello DVM,
MS, Diplomate ACVIM
(Small Animal Internal
Medicine)

IMAGING BY

Loetitia Saint-Jacques,
LVT

HOSPITAL NAME

Pine Creek VC

REFERRING VET

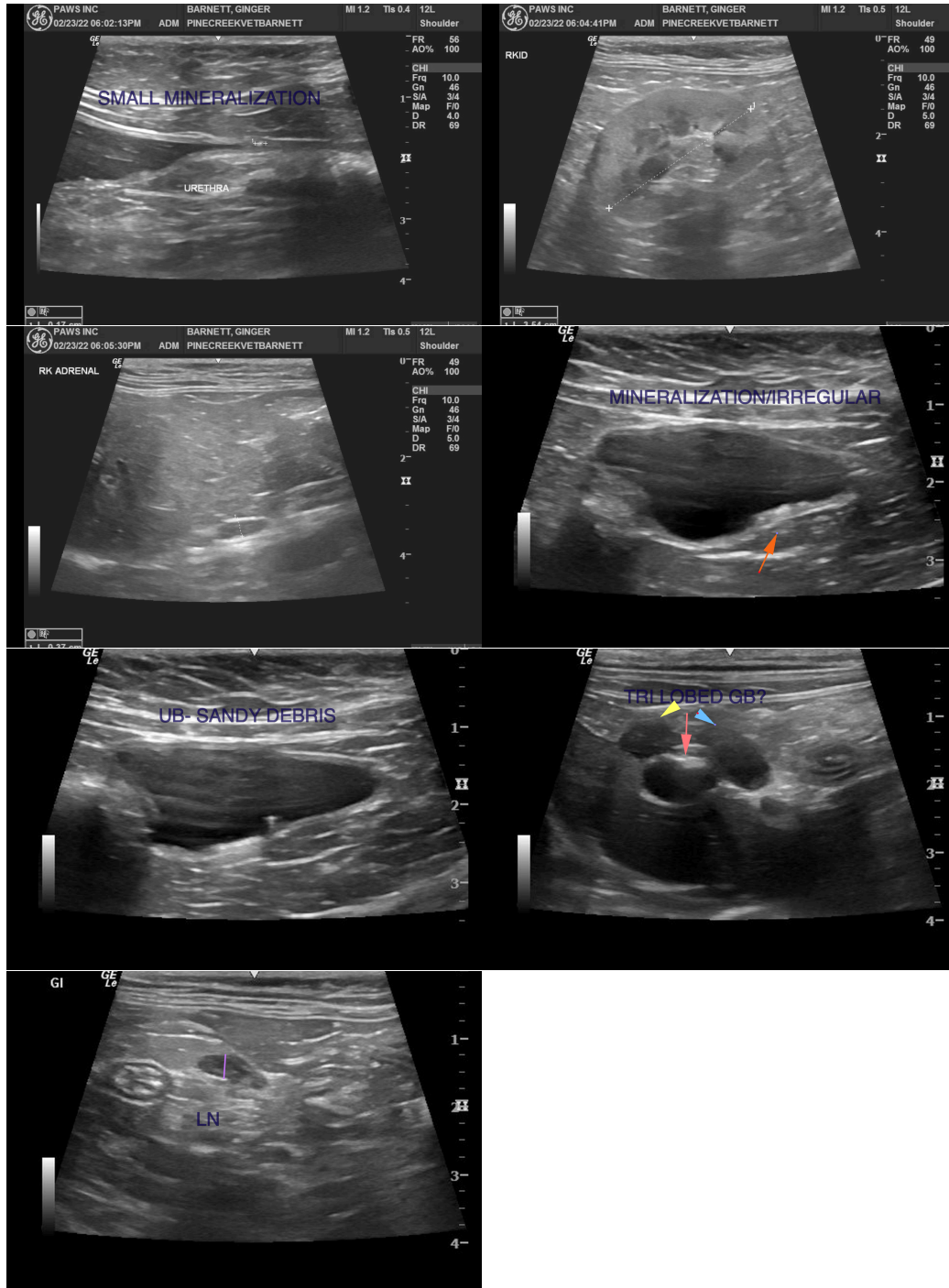
Dr. Denny Nolet

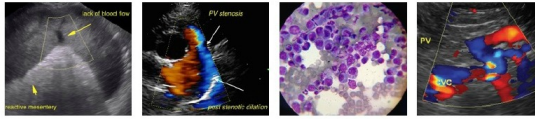
INVOICE

35852

DATE

2/23/22





PATIENT

Ginger Barnett

The information and recommendations provided are based on the images presented by the referring veterinarian/sonographer. No evaluation can be communicated regarding pathology that was not visible in the image/video clips provided.

SPECIES

Feline

Thank you for this referral. If the clinical or image interpretation does not parallel your findings or if I can be of any further assistance please contact me.

BREED

DLH

Kathleen Sennello DVM,MS, Diplomate ACVIM (Small animal Internal Medicine)
kathleen.sennello@sonopath.com

SEX

Spayed Female

AGE

2 Years 8 Months

WEIGHT

11.4 Pounds

INTERPRETED BY

Kathleen Sennello DVM,
MS, Diplomate ACVIM
(Small Animal Internal
Medicine)

IMAGING BY

Loetitia Saint-Jacques,
LVT

HOSPITAL NAME

Pine Creek VC

REFERRING VET

Dr. Denny Nolet

INVOICE

35852

DATE

2/23/22