

**DATE PRESENTING CLINICAL SIGNS**

2/22/23 Vomiting, lethargy, hyporexia x3 days, NSF on PE.
Current Medications: None.

PATIENT Lab Results: None performed (pending).

Jessie Nizzardini Date of Previous IntraPet Ultrasound:
Sedation: Not required to complete full diagnostic ultrasound.
Stat Report: Not requested.

SPECIES Imaging Performed By: Andi Parkinson, RDMS.

Feline

ULTRASONOGRAPHIC EXAMINATION OF THE ABDOMEN**BREED** *Urinary System*

DSH

The urinary bladder is moderately distended with anechoic urine. The Bladder wall, trigone, ureteral papillae and visible urethra (to a depth of 2cm) appear normal with no evidence of wall thickening, mucosal irregularities, masses or cystic calculi.

SEX

Spayed Female

The left kidney has a normal shape and size (3.4 cm). Overall echogenicity is normal with adequate corticomedullary distinction and a typical 1:3 cortex:medulla ratio. There is no evidence of focal perinephric inflammation or effusion. There is no evidence of pyelectasia, nephroliths, infarcts or hydroureter. Renal vasculature is normal.

AGE

8/6/11

The right kidney is normal in size (3.93 cm) but slightly irregular in shape, likely due to previous infarct. Overall echogenicity is normal with adequate corticomedullary distinction and a typical 1:3 cortex:medulla ratio. There is no evidence of focal perinephric inflammation or effusion. There is no evidence of pyelectasia, nephroliths or hydroureter. Renal vasculature is normal.

WEIGHT

11.5 Pounds

INTERPRETED BY

Kathleen Sennello DVM,
MS, Diplomate ACVIM
(Small Animal Internal
Medicine)

Adrenal Glands

The region of left adrenal (Cranial to left renal artery) is unremarkable but the adrenal is not distinctly visualized. No evidence of a mass effect is visualized.

The region of the right adrenal (between right cranial kidney and vena cava) is unremarkable, but the adrenal is not distinctly visualized. No evidence of a mass effect is visualized.

HOSPITAL NAME

Timonium AH

Spleen

The spleen is subjectively normal in size (1.09 cm), echotexture is homogenous, and the splenic capsule is smooth with no irregularities. The blood flow through the hilus and splenic parenchyma appears normal. No focal parenchymal abnormalities are visualized.

REFERRING VET

Dr. Montessi

Liver

The liver is subjectively normal in size, and echogenicity with slightly irregular shape. The parenchyma is homogenous echotexture. The visible portions of the vasculature and biliary tract appear normal. On the left dorsal lateral medial aspect of the liver, there is a slightly hyperechoic rounded mass lesion visualized measuring 3.09 cmx 2.8 cm.

INVOICE

45427

The gallbladder lumen is moderately distended. The wall of the gall bladder is not thickened and has a smooth mucosal surface. Luminal contents are mild and primarily anechoic. The cystic and common bile ducts are normal/not visible.

Gastrointestinal

The stomach contains moderate shadowing ingesta. It measures at a normal thickness of <0.36cm with some variability due to the presence of rugal folds. The distinction of the gastric wall layers is adequate and there is no impression of reduced peristaltic activity. No masses or focal lesions were observed.

The visualized areas of duodenum, jejunum and ileum have a uniform diameter with mild to moderate fluid/chyme distension. Wall thickness is normal to slightly increased. Bowel loops follow a typical curvilinear path with distinct wall layering, but some areas display a prominent muscularis layer which does not display the typical 1:3 muscularis:mucosa layer ratio. Jejunum wall measures 0.20 cm. Visualized peristalsis appears appropriate. There were no focal lesions consistent with obstruction or a mass effect observed.

The ileocecal junction was visualized and exhibited normal intact wall layering and is subjectively of normal thickness. Sections of colon are visualized with formed fecal material and gas shadowing distally. There is no observed focal or generalized colon wall thickening or loss of layering.

Pancreas

The right limb of the pancreas is prominent and hypoechoic as compared to the surrounding isoechoic mesentery. There is no evidence of nodules or cystic lesions. There is no evidence of regional mesenteric inflammation or fluid.

Free Abdomen

Evaluation of the peritoneal cavity did not reveal any evidence of effusion. There is a cluster of prominent mesenteric lymph nodes surrounded by hyperechoic mesentery, measuring 0.59, 0.47, 0.51 cm.

PRIMARY FINDINGS

- Slightly hyperechoic rounded mass effect on the left side of the liver – The appearance of this lesion favors a primary hepatic mass. Consider fine needle aspirates.
- Large, shadowing ingesta within the gastric lumen – Correlate with feeding history. If the patient was adequately fasted, then consider such differentials as delayed gastric emptying, partial outflow tract obstruction, etc. (none observed).
- Prominent muscularis layer to the small intestine – The small intestinal wall changes could be consistent with an underlying inflammatory process. These types of changes can sometimes be seen in normal older cats. Correlate with clinical signs.
- Cluster of prominent mesenteric lymph nodes surrounded by hyperechoic mesentery – The prominent abdominal lymph nodes are most consistent with reactive lymphadenitis or lymphoid hyperplasia. Neoplastic infiltration is considered less likely.

SECONDARY FINDINGS

- Prominent, hypoechoic right limb of the pancreas – The pancreatic changes are most consistent with mild pancreatitis or a recent episode of pancreatic inflammation.

INTERPRETATION OF THE FINDINGS & FURTHER RECOMMENDATIONS

There is a mass effect in the liver. This is a well-defined lesion and is most consistent with a primary hepatic mass lesion. This could represent a benign mass (adenoma) or a cancerous mass lesion, carcinoma, etc. Consider a fine needle aspirate and correlate with lab work findings. I suspect this mass effect is unrelated to the current clinical signs exhibited. Once this patient is feeling better, evaluation for possible surgical removal could be considered +/- contrast CT scan for surgical planning.

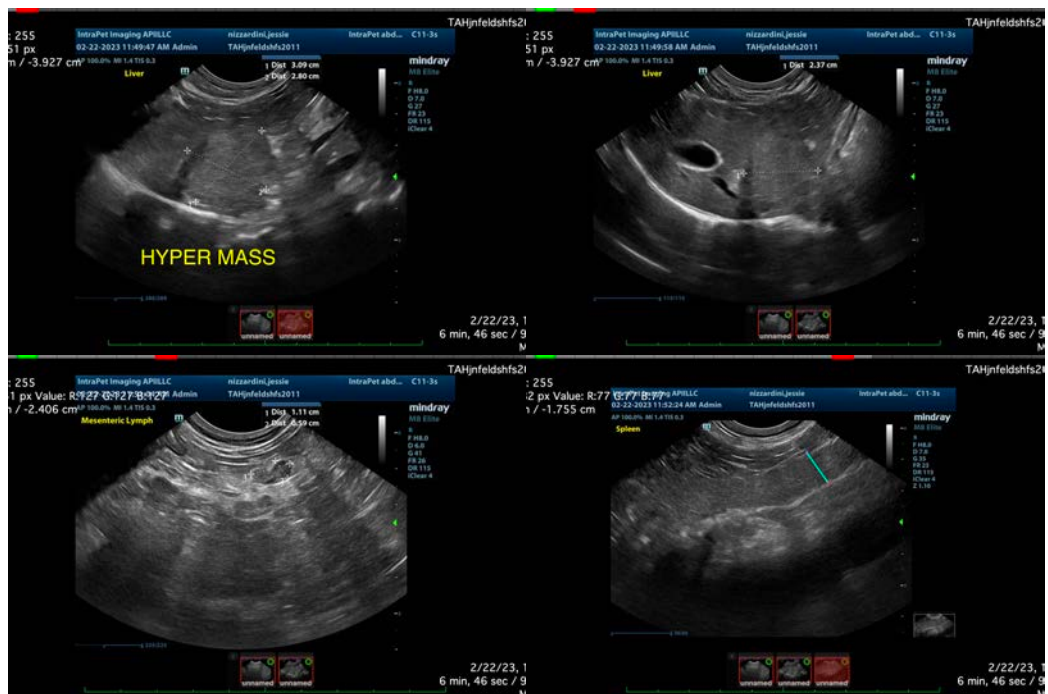
Recommend three view thoracic radiographs to evaluate for possible concurrent thoracic disease/involvement.

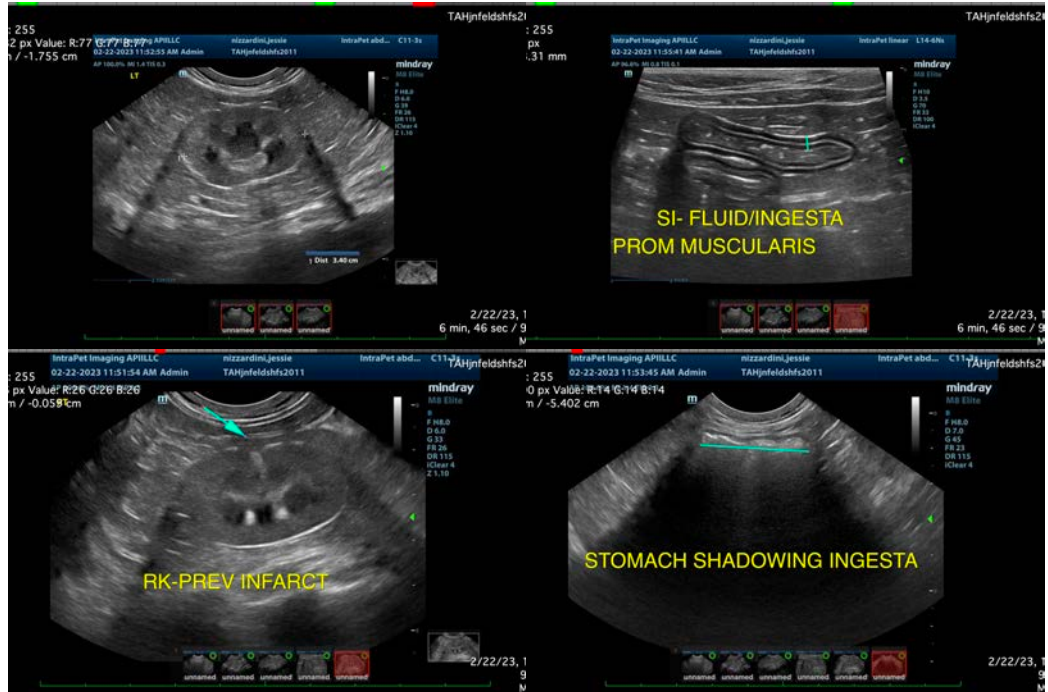
The small bowel appears somewhat “ropy” with a prominent muscularis layer. Additionally, there are clusters of prominent mesenteric lymph nodes. These changes are likely consistent with inflammatory changes, although underlying neoplastic change cannot be ruled out.

Additionally, the pancreas is visible but does not appear overtly inflamed.

There is ingesta visualized in the stomach and in the small bowel, correlate this with feeding history. If the patient was adequately fasted, then this could represent ileus, less likely an obstructive process, etc.

- Recommend treatment for acute gastroenteritis/pancreatitis.
- Consider a GI panel to Texas A&M for evaluation of B12 levels, folate, PLI/TLI etc.. to further evaluate for pancreatic/small intestinal disease.
- Consider probiotic therapy.
- If symptoms persist and lab work is relatively normal, consider serial imaging (radiographs +/- ultrasound) and further evaluation for obstruction, etc. GI biopsies may be indicated. If this considered, possible hepatic mass removal could be considered at the same time by a veterinary surgeon.





The information and recommendations provided are based on the images presented by the referring veterinarian/sonographer. No evaluation can be communicated regarding pathology that was not visible in the image/video clips provided.

Thank you for this referral. If the clinical or image interpretation does not parallel your findings or if I can be of any further assistance please contact me.

Kathleen Sennello DVM,MS, Diplomate ACVIM (Small animal Internal Medicine)
 kathleen.sennello@sonopath.com