

PATIENT PRESENTING CLINICAL SIGNS

Dasher Lauinger
SPECIES Sedated Dex/Torb IM- Intermittent acting off/ADR per O. O says he will spike a fever & then it will resolve an hour later but this has not been documented. Intermittent vomiting & lethargy. P is hyperthyroid & on methimazole & currently controlled. Persistently elevated ALT (was 187 1/23/23). GI dz/IBD vs underlying hepatopathy, P was a feral so concern of underlying congenital/genetic issue

Feline

BREED

DSH

SEX

Neutered Male

AGE

9/15/14

WEIGHT

5.2 kg

INTERPRETED BY

Kathleen Sennello DVM,
MS, Diplomate ACVIM
(Small Animal Internal
Medicine)

IMAGING PERFORMED BY

Loetitia Saint-Jacques,
LVT

HOSPITAL NAME

Desert Hills AH

REFERRING VET

Dr. Michelle Caldwell

INVOICE

45407

DATE

2/22/23

Abnormal PE/Chem/CBC/UA Results: Not overtly painful on abdominal palpation, not distended.- Able to examine in the morning but needed sedation by afternoon for ultrasound and radiographs- (Labwork run 1/28/23: Superchem- ALT=187, Triglyceride=245 CBC- RBC=10.4, Platelet Count=85,000-clumping noted, platelet estimate adequate T4=2.1-WNL),

ULTRASONOGRAPHIC EXAMINATION OF THE ABDOMEN

Urinary System

The urinary bladder is moderately distended with mild primarily suspended echogenic debris present. The Bladder wall, trigone, ureteral papillae and visible urethra (to a depth of 2cm) appear normal with no evidence of wall thickening, mucosal irregularities, masses or calculi. Echogenic debris of this type can be associated with small crystals, cellular debris and proteinaceous debris.

The left kidney is normal in size (3.15 cm) but irregular in shape (likely due to previous infarcts). Overall echogenicity is normal with adequate corticomedullary distinction and a typical 1:3 cortex:medulla ratio. There is no evidence of focal perinephric inflammation or effusion. There is no evidence of pyelectasia, nephroliths, infarcts or hydroureter. Renal vasculature is normal.

The right kidney is normal in size (4.13 cm) but irregular in shape (likely due to previous infarcts). Overall echogenicity is normal with adequate corticomedullary distinction and a typical 1:3 cortex:medulla ratio. There is no evidence of focal perinephric inflammation or effusion. There is no evidence of pyelectasia, nephroliths, infarcts or hydroureter. Renal vasculature is normal.

Adrenal Glands

The left adrenal gland is normal in size measuring 0.41 cm at the caudal pole. It is observed in its normal position cranial to the left renal artery. It is normal in appearance (uniformly hypoechoic) and shape with no evidence of a mass effect.

The right adrenal gland is normal in size measuring 0.46 cm at the caudal pole. It is observed in its normal position between the cranial aspect of the right kidney and the caudal vena cava. It is normal in appearance (uniformly hypoechoic) and shape with no evidence of a mass effect.

Spleen

The spleen is normal/borderline large in size (1.16 cm), echotexture is homogenous, and the splenic capsule is smooth with no irregularities. The blood flow through the hilus and splenic parenchyma appears normal. No focal parenchymal abnormalities are visualized.

Liver

The liver is subjectively normal in size, and echogenicity with smooth peripheral margins. The parenchyma is mildly heterogenous in echotexture with subtle, indistinct focal mottling. The visible



PATIENT

Dasher Lauinger

portions of the vasculature and biliary tract appear normal. No focal nodules or cystic lesions are observed.

SPECIES

Feline

The gallbladder lumen is moderately distended. The wall of the gall bladder is not thickened and has a smooth mucosal surface. Luminal contents are mild and primarily anechoic. The cystic and common bile ducts are normal/not visible.

Gastrointestinal

BREED

DSH

The stomach contains moderate fluid and gas. It measures at a normal thickness of <0.36cm with some variability due to the presence of rugal folds. The distinction of the gastric wall layers is adequate and there is no impression of reduced peristaltic activity. No masses or focal lesions were observed.

SEX

Neutered Male

The visualized areas of duodenum, jejunum and ileum have a relatively uniform diameter with minimal fluid distension. Wall thickness is normal. Bowel loops follow a curvilinear path with distinct wall layering maintaining the typical 1:3 muscularis:mucosa layer ratio. Duodenum wall measures 0.21 cm. Jejunum wall measures 0.19 cm. Visualized peristalsis appears appropriate. There were no focal lesions consistent with obstruction or a mass effect observed.

AGE

9/15/14

The ileocecal junction was visualized and exhibited normal intact wall layering and is subjectively of normal thickness. Sections of colon are visualized with formed fecal material and gas shadowing distally. There is no observed focal or generalized colon wall thickening or loss of layering.

WEIGHT

5.2 kg

Pancreas

INTERPRETED BY

Kathleen Sennello DVM,
MS, Diplomate ACVIM
(Small Animal Internal
Medicine)

The pancreas is prominent and hypoechoic as compared to the surrounding isoechoic mesentery. There is no evidence of nodules or cystic lesions. There is no evidence of regional mesenteric inflammation or fluid. Prominent pancreatic duct noted at 0.17 cm.

Free Abdomen

IMAGING PERFORMED BY

Loetitia Saint-Jacques,
LVT

Evaluation of the peritoneal cavity did not reveal any evidence of effusion. There are occasional prominent mesenteric lymph nodes. The pancreaticoduodenal lymph node measures at 0.50 cm. A lymph node near the ileocecal junction measures 0.31 cm. The omentum is generally of normal echogenicity.

PRIMARY FINDINGS

HOSPITAL NAME

Desert Hills AH

- Irregular kidneys – Findings are most consistent with previous infarcts. The renal lesion identified is ill defined and hyperechoic, this could be consistent with a previous renal infarct and can be an indicator of current or previous renal disease.

REFERRING VET

Dr. Michelle Caldwell

- Hypoechoic, prominent pancreas with a prominent pancreatic duct – The pancreatic changes are most consistent with mild pancreatitis or a recent episode of pancreatic inflammation.

INVOICE

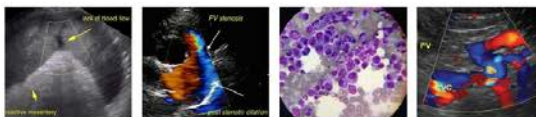
45407

- Mildly heterogeneous liver – Hepatic changes are non-specific and could be consistent with inflammation/infection (cholangiohepatitis), infiltrative neoplasia, lipidosis or other hepatopathy.

DATE

2/22/23

- Prominent mesenteric lymph nodes – The prominent abdominal lymph nodes are most consistent with reactive lymphadenitis or lymphoid hyperplasia. Neoplastic infiltration is considered less likely.



PATIENT

Dasher Lauinger

- Gas distended stomach – This is likely due to anxiety during imaging. Unfortunately, gas artifact reduces the ability to evaluate nearby structures.

SPECIES

Feline

SECONDARY FINDINGS

- Mildly echogenic debris in the urinary bladder – The echogenic debris in the bladder lumen could be consistent with cells, crystals, and/or mucus.

BREED

DSH

- Borderline large spleen – The spleen otherwise appears relatively normal, and this is a large cat, so I suspect this is within normal limits.

SEX

Neutered Male

INTERPRETATION OF THE FINDINGS & FURTHER RECOMMENDATIONS

No definitive focal lesions are visualized to explain the vomiting and lethargy reported. The pancreas is slightly prominent but not overtly inflamed. Correlate these findings with a quantitative fPLI level. You could consider empirical treatment for pancreatic inflammation.

AGE

9/15/14

The liver is very mildly heterogeneous and the significance of this is uncertain. Consider the following for further evaluation.

WEIGHT

5.2 kg

- Consider close evaluation of history for possible toxic changes examine medications, diet, dietary indiscretion etc.

- Recommend thyroid evaluation (if not already done)

INTERPRETED BY

Kathleen Sennello DVM,
MS, Diplomate ACVIM
(Small Animal Internal
Medicine)

- If not already done consider pre and post prandial bile acids to evaluate liver function

- Consider Fine needle aspirate if round cell neoplasia is on your differential list (25 g needle, normal coags)

- Consider liver biopsy with samples obtained for histopathology and culture

IMAGING PERFORMED BY

Loetitia Saint-Jacques,
LVT

- If triaditis is suspected consider therapy for cholangiohepatitis, testing for pancreatitis and evaluation for IBD (GI panel to Texas A&M GI lab)

HOSPITAL NAME

Desert Hills AH

Based on the history of this being a feral cat, you could consider infectious disease screening for diseases such as toxoplasmosis.

REFERRING VET

Dr. Michelle Caldwell

Unfortunately, despite having a relatively normal scan, you can still have significant gastrointestinal disease present. If this is strongly suspected, then consider a GI panel to Texas A&M for a qualitative fPLI, TLI, cobalamin and folate for further evaluation. Consider probiotic therapy and switching to a novel protein/hydrolyzed protein prescription diet.

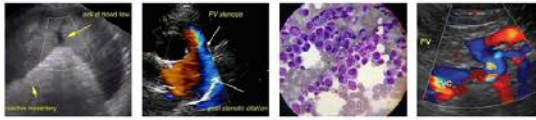
INVOICE

45407

Recommend three view thoracic radiographs to evaluate for possible concurrent thoracic disease/involvement.

DATE

2/22/23



PATIENT

Dasher Lauinger

SPECIES

Feline

BREED

DSH

SEX

Neutered Male

AGE

9/15/14

WEIGHT

5.2 kg

INTERPRETED BY

Kathleen Sennello DVM,
MS, Diplomate ACVIM
(Small Animal Internal
Medicine)

IMAGING PERFORMED BY

Loetitia Saint-Jacques,
LVT

HOSPITAL NAME

Desert Hills AH

REFERRING VET

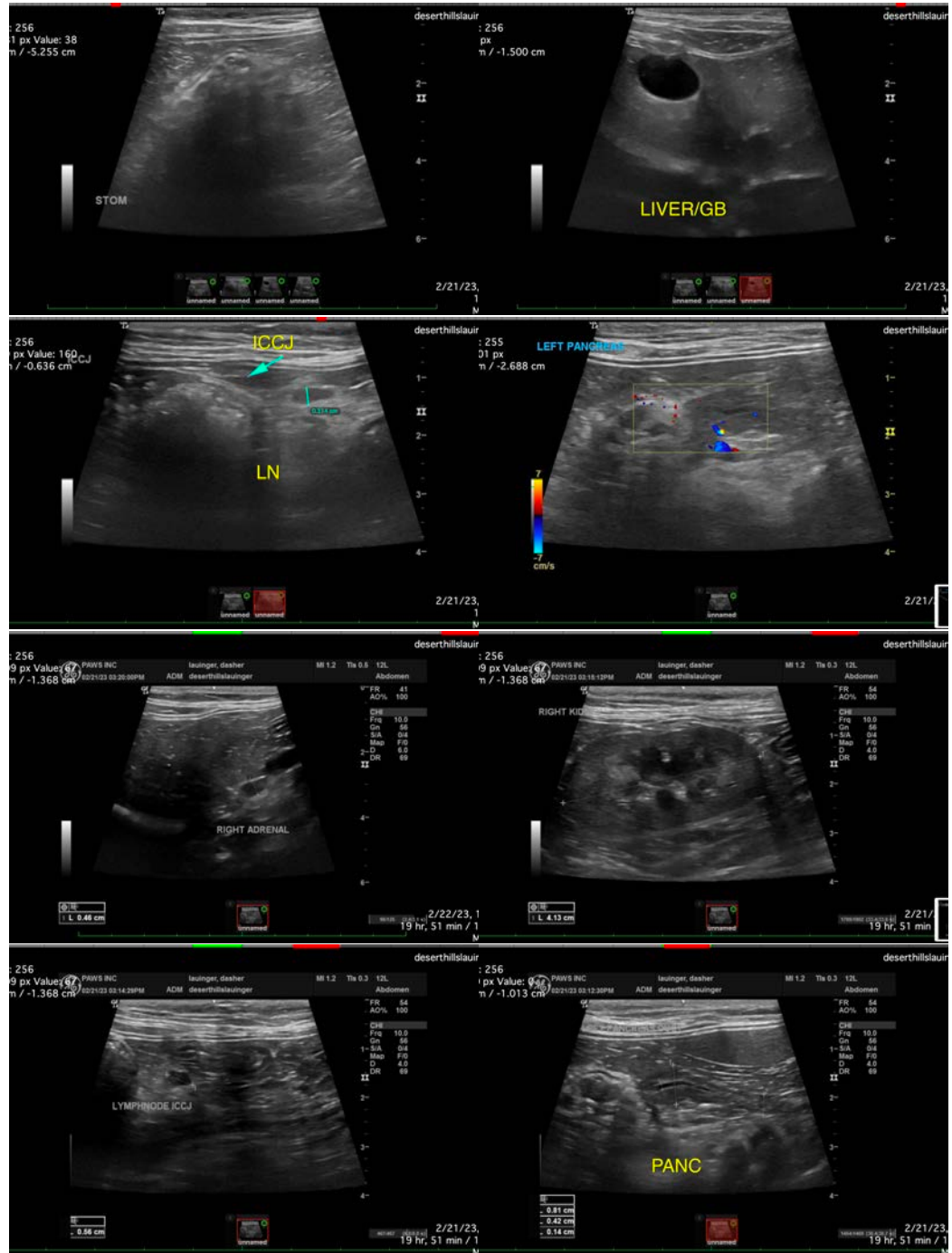
Dr. Michelle Caldwell

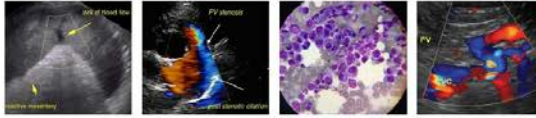
INVOICE

45407

DATE

2/22/23





PATIENT

Dasher Lauinger

SPECIES

Feline

BREED

DSH

SEX

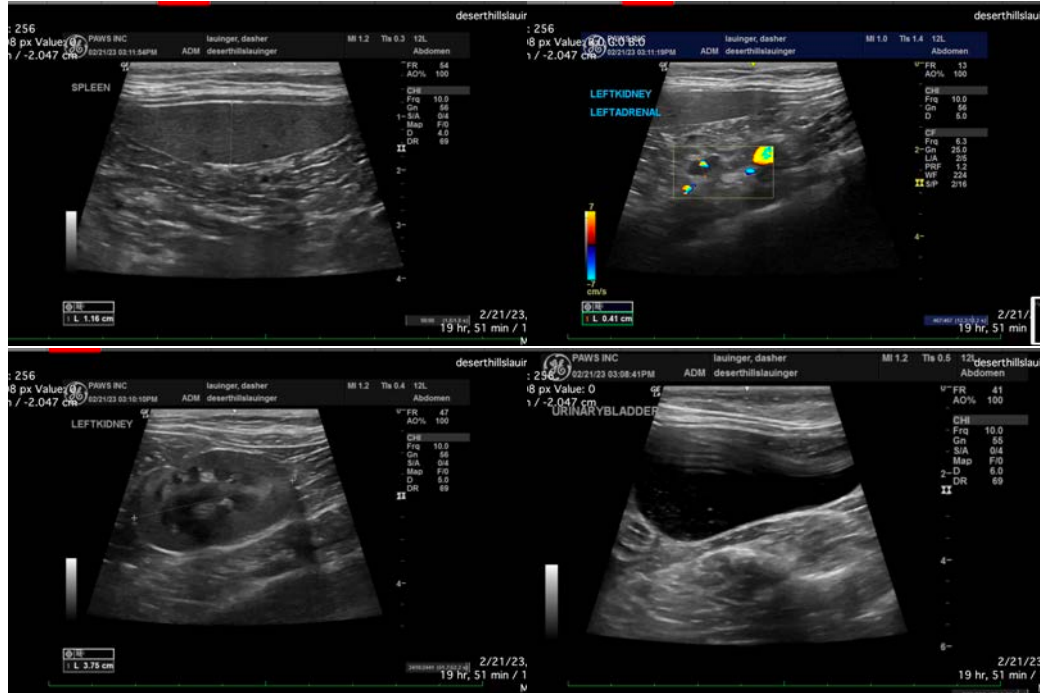
Neutered Male

AGE

9/15/14

WEIGHT

5.2 kg



INTERPRETED BY

Kathleen Sennello DVM,
MS, Diplomate ACVIM
(Small Animal Internal
Medicine)

IMAGING PERFORMED BY

Loetitia Saint-Jacques,
LVT

HOSPITAL NAME

Desert Hills AH

REFERRING VET

Dr. Michelle Caldwell

INVOICE

45407

DATE

2/22/23

The information and recommendations provided are based on the images presented by the referring veterinarian/sonographer. No evaluation can be communicated regarding pathology that was not visible in the image/video clips provided.

Thank you for this referral. If the clinical or image interpretation does not parallel your findings or if I can be of any further assistance please contact me.

Kathleen Sennello DVM,MS, Diplomate ACVIM (Small animal Internal Medicine)

kathleen.sennello@sonopath.com