

**PATIENT**

Olive Hershenow

**SPECIES**

Canine

**BREED**

American Foxhound

**SEX**

Spayed Female

**AGE**

13.7y

**WEIGHT**

53lbs

**INTERPRETED BY**

Kathleen Sennello DVM,  
MS, Diplomate ACVIM  
(Small Animal Internal  
Medicine)

**IMAGING  
PERFORMED BY**

Loetitia Saint-Jacques,  
LVT

**HOSPITAL NAME**

Truckee Meadows  
Veterinary Hospital

**REFERRING VET**

Dr. Rachel

**INVOICE**

10060

**DATE**

2/21/2023

**PRESENTING CLINICAL SIGNS**

HX OF ELEVATED RENAL VALUES- resolved. Moderate periodontal dx- weight loss- vomiting- Hypothyroid-

**ULTRASONOGRAPHIC EXAMINATION OF THE ABDOMEN**

**Urinary System**

The urinary bladder is moderately distended with anechoic urine. The Bladder wall, trigone, ureteral papillae, and visible urethra (to a depth of 2cm) appear normal with no evidence of wall thickening, mucosal irregularities, masses, or cystic calculi.

The left kidney has a normal shape and size (5.79 cm). Overall echogenicity is normal with adequate corticomedullary distinction and a typical 1:3 cortex: medulla ratio. There is no evidence of focal perinephric inflammation or effusion. There is no evidence of pyelectasia, nephroliths, infarcts or hydroureter. Renal vasculature is normal.

The right kidney has a normal shape and size (4.62 cm). Overall echogenicity is normal with adequate corticomedullary distinction and a typical 1:3 cortex: medulla ratio. There is no evidence of focal perinephric inflammation or effusion. There is no evidence of pyelectasia, nephroliths, infarcts or hydroureter. Renal vasculature is normal.

**Adrenal Glands**

The left adrenal gland is normal in size measuring 0.48 cm at the caudal pole. It is observed in its normal position cranial to the left renal artery. It is normal in appearance (uniformly hypoechoic) and shape with no evidence of a mass effect.

The right adrenal gland is large and irregular in shape measuring 3.9 cm in the cranial pole and 1.71 cm at the caudal pole and 4.63 cm in length. It is visualized in its normal position between the right kidney and the caudal vena cava, it is abnormal in that it is large and irregular. Additionally, there is visible extension into the caudal vena cava, with an intraluminal mass effect measuring 3.17 cm x 1.37 cm with significant obstruction of the caudal vena cava.

**Spleen**

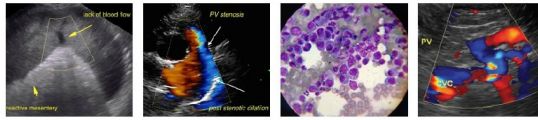
The spleen is large and somewhat irregular with homogenous echotexture. The blood flow through the hilus and splenic parenchyma appears normal. There is a cavitated hypoechoic mass lesion visualized arising from the spleen measuring 4.17 cm x 4.52 cm. Additionally, there is a small intraparenchymal hypoechoic nodule visualized measuring 0.94 cm.

**Liver**

The liver is large in size, and normal in echogenicity with smooth peripheral margins. The parenchyma is heterogenous in echotexture with subtle, indistinct focal mottling. The visible portions of the vasculature and biliary tract appear normal. No focal nodules or cystic lesions are observed.

The gall bladder lumen is moderately distended. The wall of the gall bladder is not thickened and has a smooth mucosal surface. There is a moderate amount of non-organized echogenic debris. The cystic and common bile ducts are normal/not visible.

**Gastrointestinal**



**PATIENT**

Olive Hershenow

The stomach contains minimal luminal contents. It measures at a normal thickness of <0.7cm with some variability due to the presence of rugal folds. The distinction of the gastric wall layers is adequate and there is no impression of reduced peristaltic activity. No masses or focal lesions were observed.

**SPECIES**

Canine

The visualized areas of duodenum, jejunum and ileum have a uniform diameter with minimal fluid distension. Wall appears subjectively, mildly increased. Bowel loops follow a typical curvilinear path with distinct wall layering. Visualized peristalsis appears appropriate. There were no focal lesions consistent with obstruction or a mass effect observed. The jejunum measures at 0.46 cm, duodenal speckling is noted.

**BREED**

American Foxhound

**SEX**

Spayed Female

The ileocecal junction was visualized and exhibited normal intact wall layering and is subjectively of normal thickness. Sections of colon are visualized with formed fecal material and gas shadowing distally. There is no observed focal or generalized colon wall thickening or loss of layering.

**AGE**

13.7y

**Pancreas**

The pancreas is normal and isoechoic to surrounding mesentery. There is no evidence of nodules or cystic lesions. There is no evidence of regional mesenteric inflammation or fluid.

**WEIGHT**

53lbs

**Free Abdomen**

Evaluation of the peritoneal cavity did reveal a scant amount free abdominal fluid. An occasional prominent lymph node one of which measures at 0.63 cm, and diffuse hyperechoic mesentery. The omentum is of normal uniform echogenicity.

**INTERPRETED BY**

Kathleen Sennello DVM,  
MS, Diplomate ACVIM  
(Small Animal Internal  
Medicine)

**OTHER**

The right auricle and pericardium were visualized and were unremarkable. No obvious pathology is visualized. If cardiac function evaluation is desired a full echocardiogram is warranted.

**IMAGING PERFORMED BY**

Loetitia Saint-Jacques,  
LVT

**PRIMARY FINDINGS**

- Cavitated splenic mass and small hypoechoic splenic nodule. A large, heterogenous mass with cavitations is present within the splenic parenchyma. The mass distorts the splenic capsule. Differentials for the mass include neoplasia (e.g., hemangiosarcoma, hemangioma), hematoma, abscess, other. A neoplastic process is favored.

**HOSPITAL NAME**

Truckee Meadows  
Veterinary Hospital

- Large heterogenous liver. The diffuse hepatic changes are non-specific and could be consistent with vacuolar hepatopathy, nodular hyperplasia, inflammatory/immune-mediated disease, fibrosis, extramedullary hematopoiesis, toxic hepatopathy (e.g., copper), infiltrative neoplasia (less likely) or other hepatopathy.

**REFERRING VET**

Dr. Rachel

- Moderate gallbladder debris. The significance of the aggregated gallbladder debris is unclear. This could represent an early mucocele, cholestasis, or may be secondary to fasting but seems unlikely to be causing a current issue. Recommend continued monitoring.

**INVOICE**

10060

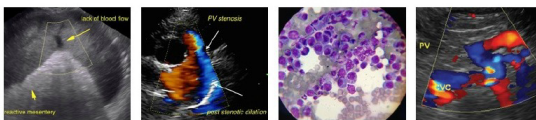
- Right adrenal mass lesion with invasion into the caudal vena cava. Differentials would include pheochromocytoma, carcinoma, adenoma, other.

**DATE**

2/21/2023

- Scant free abdominal fluid.

- Subjectively thickened small intestine with mucosal speckling. Bright mucosal speckling has



**PATIENT**

Olive Hershenow

been postulated to represent dilated lacteals or focal accumulations of mucus, cellular debris, etc. in the mucosal crypts.

**SPECIES**

Canine

**INTERPRETATION OF THE FINDINGS & FURTHER RECOMMENDATIONS**

There are two significant lesions observed, one being the cavitated splenic mass lesion. This could be benign or malignant in nature but based on the size and cavitation splenectomy with removal is recommended. Additionally, there is large right sided adrenal mass lesion with invasion into the vena cava. In some of these situations surgical removal is still possible but is high risk and a preoperative CT scan is necessary to evaluate for the degree of invasion and to look for any evidence of smaller metastatic lesions. Given these two combined lesions the prognosis is very guarded.

**BREED**

American Foxhound

**SEX**

Spayed Female

Recommend three view thoracic radiographs looking for any evidence of metastatic lesions and a blood pressure evaluation. If the blood pressure is elevated consider measuring catecholamine levels looking for possible pheochromocytoma, which would affect your anesthetic plan if surgery is pursued.

**AGE**

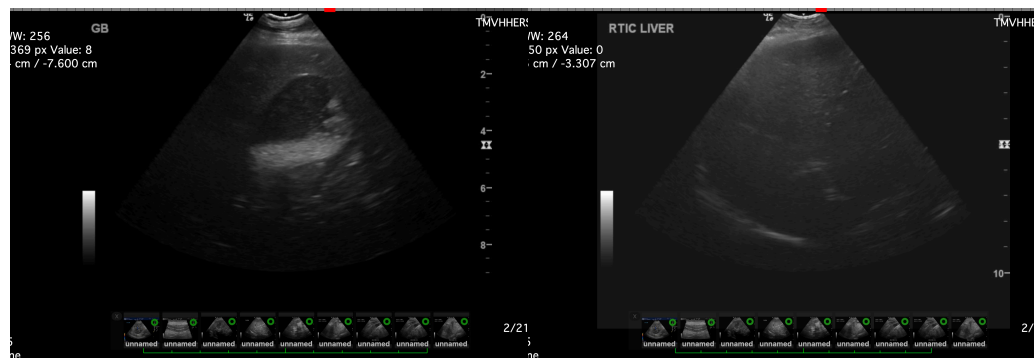
13.7y

**WEIGHT**

53lbs

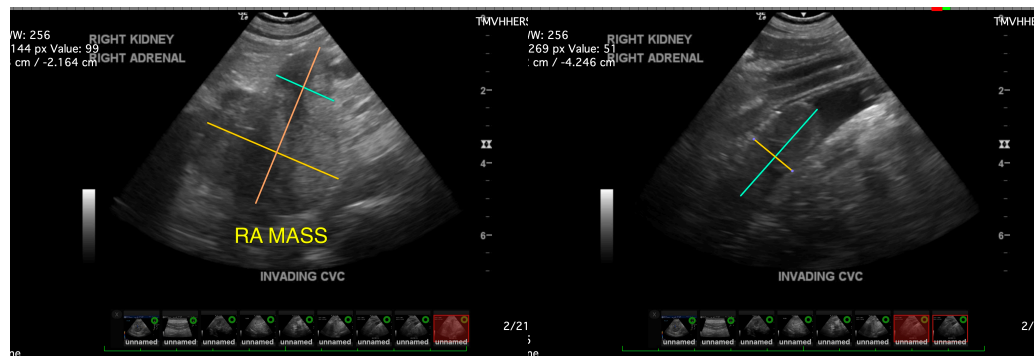
**INTERPRETED BY**

Kathleen Sennello DVM,  
MS, Diplomate ACVIM  
(Small Animal Internal  
Medicine)



**IMAGING PERFORMED BY**

Loetitia Saint-Jacques,  
LVT



**HOSPITAL NAME**

Truckee Meadows  
Veterinary Hospital

**REFERRING VET**

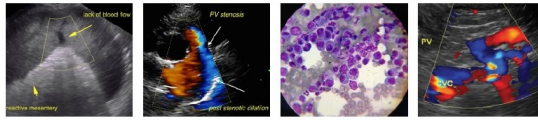
Dr. Rachel

**INVOICE**

10060

**DATE**

2/21/2023



**PATIENT**

Olive Hershenow

**SPECIES**

Canine

**BREED**

American Foxhound

**SEX**

Spayed Female

**AGE**

13.7y

**WEIGHT**

53lbs

**INTERPRETED BY**

Kathleen Sennello DVM,  
MS, Diplomate ACVIM  
(Small Animal Internal  
Medicine)

**IMAGING  
PERFORMED BY**

Loetitia Saint-Jacques,  
LVT

**HOSPITAL NAME**

Truckee Meadows  
Veterinary Hospital

**REFERRING VET**

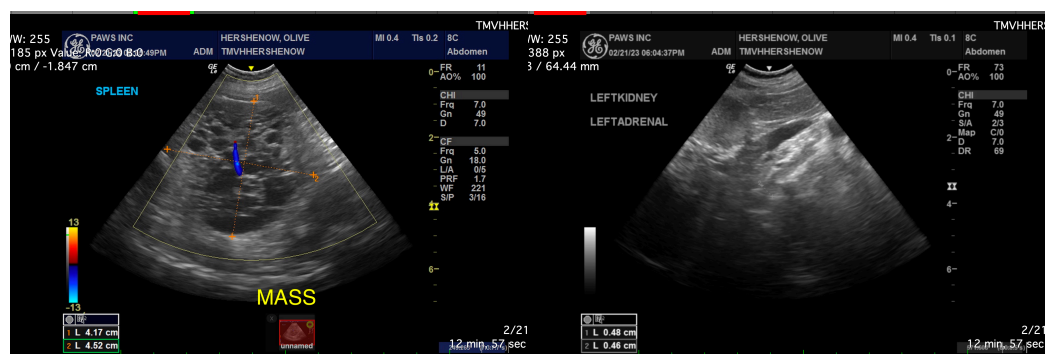
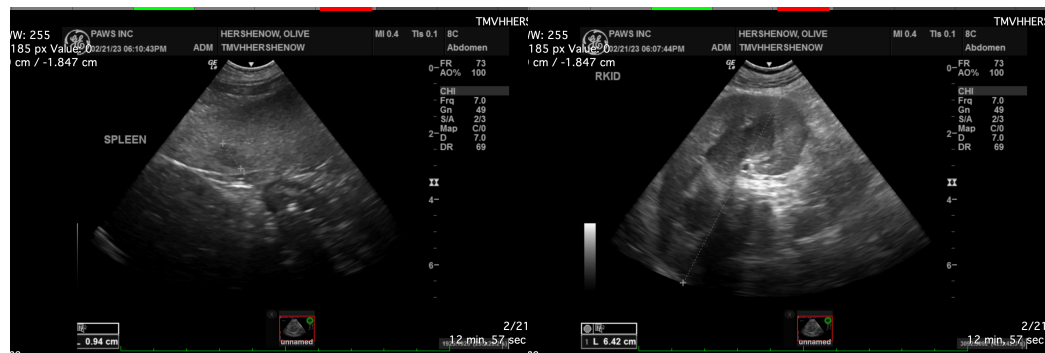
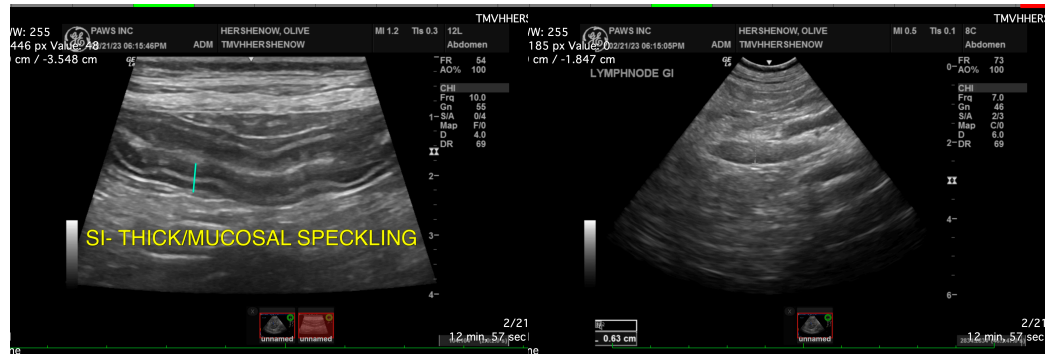
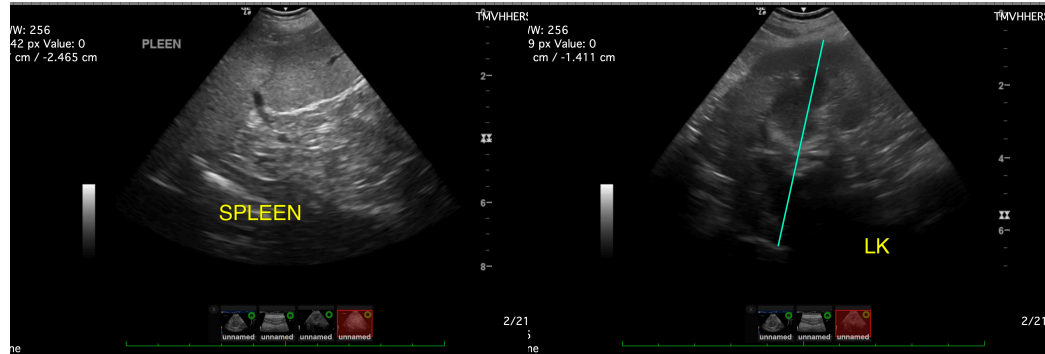
Dr. Rachel

**INVOICE**

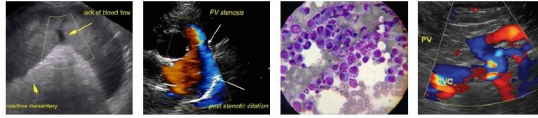
10060

**DATE**

2/21/2023



The information and recommendations provided are based on the images presented by the referring veterinarian/sonographer. No evaluation can be communicated regarding pathology that was not



**PATIENT**

Olive Hershenow

visible in the image/video clips provided.

Thank you for this referral. If the clinical or image interpretation does not parallel your findings or if I can be of any further assistance, please contact me.

**SPECIES**

Canine

Kathleen Sennello DVM, MS, Diplomate ACVIM (Small animal Internal Medicine)

kathleen.sennello@sonopath.com

**BREED**

American Foxhound

**SEX**

Spayed Female

**AGE**

13.7y

**WEIGHT**

53lbs

**INTERPRETED BY**

Kathleen Sennello DVM,  
MS, Diplomate ACVIM  
(Small Animal Internal  
Medicine)

**IMAGING  
PERFORMED BY**

Loetitia Saint-Jacques,  
LVT

**HOSPITAL NAME**

Truckee Meadows  
Veterinary Hospital

**REFERRING VET**

Dr. Rachel

**INVOICE**

10060

**DATE**

2/21/2023