

**DATE PRESENTING CLINICAL SIGNS**

2/21/23 Three (3) lb weight loss. Was 12 lbs , is now 9 lbs. Ingrown nail causing cellulitis. All nails very thickened. No heart murmur ausculted, unkempt hair coat  
 PATIENT Teeth not painful

Charles Johnson Current Medications: Convenia - 0.42 ml, Zorbium topical- Both used for cellulitis of toe.  
 Lab Results: ALT - 204 U/L (was 80 in 2021), cholesterol - 86 mg/dl (low) , was 121 in 2021, T4 - 1.5, globulin - 5.9 g/dl (high end of normal)  
 SPECIES Date of Previous IntraPet Ultrasound: No previous.  
 Feline Sedation: Not required to complete full diagnostic ultrasound.  
 BREED Stat Report: Not requested.  
 Imaging Performed By: Rachel Brillhart, RDMS.

**ULTRASONOGRAPHIC EXAMINATION OF THE ABDOMEN**

Balinese/Siamese X

**SEX Urinary System**

Neutered Male The urinary bladder is moderately distended with mild primarily suspended echogenic debris and some dependent shadowing/sandy debris present. The Bladder wall, trigone, ureteral papillae and visible urethra (to a depth of 2cm) appear normal with no evidence of wall thickening, mucosal irregularities, masses or calculi. Echogenic debris of this type can be associated with small crystals, sandy debris or small calculi. Correlate findings with abdominal radiographs, urinalysis and culture.

**AGE**

1/3/08

**WEIGHT**

9 Pounds

The left kidney has a normal shape and size (3.8 cm). Overall echogenicity is slightly hyperechoic with poor corticomedullary distinction and a typical 1:3 cortex:medulla ratio. There is no evidence of focal perinephric inflammation or effusion. There is no evidence of pyelectasia, nephroliths, infarcts or hydroureter. Renal vasculature is normal.

**INTERPRETED BY**

Kathleen Sennello DVM,  
 MS, Diplomate ACVIM  
 (Small Animal Internal  
 Medicine)

The right kidney has a normal shape and size (3.91 cm). Overall echogenicity is slightly hyperechoic with poor corticomedullary distinction and a typical 1:3 cortex:medulla ratio. There is no evidence of focal perinephric inflammation or effusion. There is no evidence of pyelectasia, nephroliths, infarcts or hydroureter. Renal vasculature is normal.

**HOSPITAL NAME**

Chadwell AH

**Adrenal Glands**

The left adrenal gland is normal in size measuring 0.45 cm at the caudal pole. It is observed in its normal position cranial to the left renal artery. It is normal in appearance (uniformly hypoechoic) and shape with no evidence of a mass effect.

**REFERRING VET**

Dr. Schaupp

The right adrenal gland is normal in size measuring 0.41 cm at the caudal pole. It is observed in its normal position between the cranial aspect of the right kidney and the caudal vena cava. It is normal in appearance (uniformly hypoechoic) and shape with no evidence of a mass effect.

**INVOICE**

45380

**Spleen**

The spleen is subjectively normal in size (0.46 cm), echotexture is homogenous, and the splenic capsule is smooth with no irregularities. The blood flow through the hilus and splenic parenchyma appears normal. No focal parenchymal abnormalities are visualized.

**Liver**

The liver is subjectively normal in size, and echogenicity with smooth peripheral margins. The parenchyma is heterogenous in echotexture with subtle, indistinct focal mottling. The visible portions of the vasculature and biliary tract appear normal. No focal nodules or cystic lesions are observed.

The gall bladder lumen is moderately distended. The wall of the gall bladder is not thickened and has a smooth mucosal surface. There is a moderate amount of non-organized echogenic debris and hyperechoic shadowing foci, most consistent with small choleliths. The cystic and common bile ducts are normal/not visible.

### ***Gastrointestinal***

The stomach contains minimal luminal contents. It measures at a normal thickness of <0.36cm with some variability due to the presence of rugal folds. The distinction of the gastric wall layers is adequate and there is no impression of reduced peristaltic activity. No masses or focal lesions were observed.

The visualized areas of duodenum, jejunum and ileum have a uniform diameter with minimal fluid distension. Wall thickness is normal to slightly increased. Bowel loops follow a typical curvilinear path with distinct wall layering, but some areas display a prominent muscularis layer which does not display the typical 1:3 muscularis:mucosa layer ratio. Jejunum wall measures 0.22 cm. Visualized peristalsis appears appropriate. There were no focal lesions consistent with obstruction or a mass effect observed.

The ileocecal junction was visualized and exhibited normal intact wall layering and is subjectively of normal thickness. Sections of colon are visualized with formed fecal material and gas shadowing distally. There is no observed focal or generalized colon wall thickening or loss of layering.

### ***Pancreas***

The pancreas is normal and isoechoic to surrounding mesentery. There is no evidence of nodules or cystic lesions. There is no evidence of regional mesenteric inflammation or fluid.

### ***Free Abdomen***

Evaluation of the peritoneal cavity did not reveal any evidence of effusion. There is an occasional prominent isoechoic lymph node in the region of the mesenteric lymph node. One of these lymph nodes measures 0.67 cm. The omentum is of normal echogenicity.

## **ULTRASONOGRAPHIC FINDINGS**

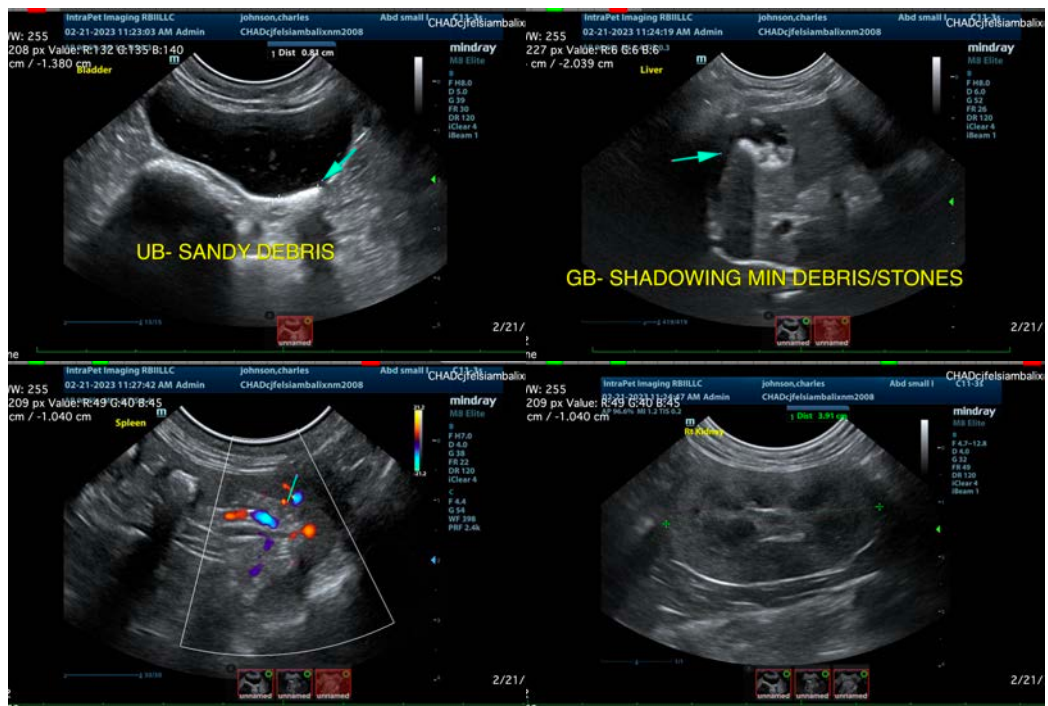
- Sandy debris visualized within the urinary bladder – The echogenic debris in the bladder lumen could be consistent with cells, small stones, crystals, and/or mucus.
- Decreased corticomedullary distinction in both kidneys – The bilateral renal findings are consistent with age-related change.
- Heterogeneous liver – Hepatic changes are non-specific and could be consistent with inflammation/infection (cholangiohepatitis), infiltrative neoplasia, lipidosis or other hepatopathy.
- Hyperechoic shadowing foci visualized within the gallbladder – Findings are most consistent with choleliths. This could be incidental or associated with cholecystitis.
- Mildly prominent muscularis layer to the small intestine – The small intestinal wall changes could be consistent with an underlying inflammatory process. These types of changes can sometimes be seen in normal older cats. Correlate with clinical signs.
- Occasional prominent mesenteric lymph nodes – The prominent abdominal lymph nodes are most consistent with reactive lymphadenitis or lymphoid hyperplasia. Neoplastic infiltration is considered less likely.

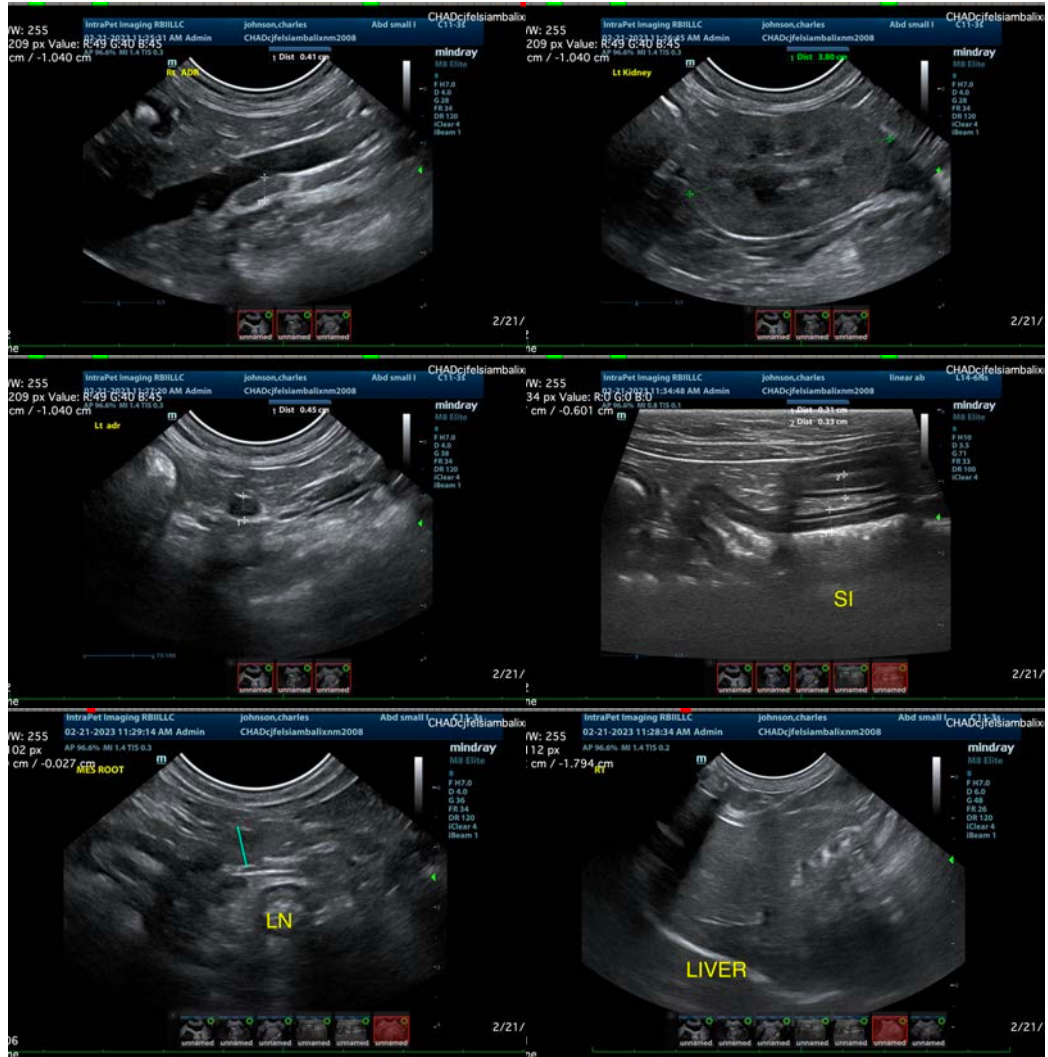
## INTERPRETATION OF THE FINDINGS & FURTHER RECOMMENDATIONS

No focal lesions are visualized associated with the liver to explain elevation in ALT reported. There are some small choleliths visualized. This could be an incidental finding or could be associated with cholecystitis. It is also possible that the ALT elevation is secondary to systemic inflammation and the reported cellulitis, etc. Consider a recheck once this is significantly improved and the patient is off antibiotics. If this persists, you could consider adding in Ursodiol and consider the following:

- Consider close evaluation of history for possible toxic changes examine medications, diet, dietary indiscretion etc.
- Recommend thyroid evaluation (if not already done)
- Consider screening for toxoplasmosis
- If not already done consider pre and post prandial bile acids to evaluate liver function
- Consider Fine needle aspirate if round cell neoplasia is on your differential list (25 g needle, normal coags)
- Consider liver biopsy with samples obtained for histopathology and culture
- If triaditis is suspected consider therapy for cholangiohepatitis, testing for pancreatitis and evaluation for IBD (GI panel to Texas A&M GI lab)

The small bowel appears slightly “ropy”. This is likely within normal limits for a geriatric cat, but underlying gastrointestinal disease can be present with minimal ultrasonographic changes. If this is suspected based on the weight loss, etc., you could consider a GI panel to Texas A&M for a qualitative fPLI, TLI, cobalamin and folate for further evaluation and consideration of the need for further GI workup.





The information and recommendations provided are based on the images presented by the referring veterinarian/sonographer. No evaluation can be communicated regarding pathology that was not visible in the image/video clips provided.

Thank you for this referral. If the clinical or image interpretation does not parallel your findings or if I can be of any further assistance please contact me.

Kathleen Sennello DVM,MS, Diplomate ACVIM (Small animal Internal Medicine)  
 kathleen.sennello@sonopath.com