



**DATE PRESENTING CLINICAL SIGNS**

2/20/26 **Patient History:** Losing weight.

**PATIENT Current Medications:** None listed.

Hole Shot Eney **Labwork Results:** Labwork attached.

**Date of Previous IntraPet Ultrasound:** No previous.

**Sedation:** Not required to complete full diagnostic ultrasound.

**Stat Report:** Not requested.

**SPECIES Imaging Performed by:** Stephanie Warga RDCS, RVT.

Feline

**ULTRASONOGRAPHIC EXAMINATION OF THE ABDOMEN**

**BREED Urinary System**

Bengal The urinary bladder is moderately distended with mild primarily suspended echogenic debris present. The Bladder wall, trigone, ureteral papillae and visible urethra (to a depth of 2cm) appear normal with no evidence of wall thickening, mucosal irregularities, masses or calculi. Echogenic debris of this type can be associated with small crystals, cellular debris and proteinaceous debris.

**SEX**

Neutered Male

The left kidney has a normal shape and size (3.49 cm). Overall echogenicity is normal with adequate corticomedullary distinction and a typical 1:3 cortex:medulla ratio. There is no evidence of focal perinephric inflammation or effusion. There is no evidence of pyelectasia, nephroliths, infarcts or hydroureter. Renal vasculature is normal.

**AGE**

8/26/10

**WEIGHT**

7.8 lbs

The right kidney has a normal shape and size (3.66 cm). Overall echogenicity is normal with adequate corticomedullary distinction and a typical 1:3 cortex:medulla ratio. There is no evidence of focal perinephric inflammation or effusion. There is no evidence of pyelectasia, nephroliths, infarcts or hydroureter. Renal vasculature is normal.

**INTERPRETED BY**

Kathleen Sennello DVM,  
MS, Diplomate ACVIM  
(Small Animal Internal  
Medicine)

**Adrenal Glands**

The left adrenal gland is normal in size measuring 0.35 cm at the caudal pole. It is observed in its normal position cranial to the left renal artery. It is normal in appearance (uniformly hypoechoic) and shape with no evidence of a mass effect.

**HOSPITAL NAME**

Animal Medical Center  
of Bel Air

The right adrenal gland is normal in size measuring 0.38 cm at the caudal pole. It is observed in its normal position between the cranial aspect of the right kidney and the caudal vena cava. It is normal in appearance (uniformly hypoechoic) and shape with no evidence of a mass effect.

**REFERRING VET**

Dr. Chaudhry

**Spleen**

The spleen is subjectively normal in size (0.70 cm), echotexture is homogenous, and the splenic capsule is smooth with no irregularities. The blood flow through the hilus and splenic parenchyma appears normal. No focal parenchymal abnormalities are visualized.

**INVOICE**

73129

**Liver**

The liver is subjectively normal in size, and echogenicity with smooth peripheral margins. The parenchyma is homogenous echotexture. The visible portions of the vasculature and biliary tract appear normal. No focal nodules or cystic lesions are observed.

The gall bladder lumen is moderately distended. The wall of the gall bladder is not thickened and has a smooth mucosal surface. Luminal contents are mild and likely incidental at this time. The common bile duct is slightly prominent, measuring at 0.16 cm.

### ***Gastrointestinal***

The stomach contains minimal luminal contents. It measures at a normal thickness of <0.36cm with some variability due to the presence of rugal folds. The distinction of the gastric wall layers is adequate and there is no impression of reduced peristaltic activity. No masses or focal lesions were observed.

The visualized areas of duodenum, jejunum and ileum have a uniform diameter with minimal fluid distension. Wall thickness is normal to slightly increased. Bowel loops follow a typical curvilinear path with distinct wall layering, but some areas display a prominent muscularis layer which does not display the typical 1:3 muscularis:mucosa layer ratio. Jejunum wall measures 0.16 cm. Visualized peristalsis appears appropriate. There were no focal lesions consistent with obstruction or a mass effect observed.

Sections of colon are visualized with formed fecal material and gas shadowing distally. There is no observed focal or generalized colon wall thickening or loss of layering.

### ***Pancreas***

The left limb of the pancreas is large and hypoechoic to surrounding mesentery. There is no evidence of nodules or cystic lesions. There is evidence of regional mesenteric inflammation. Consistent with mild pancreatitis. Prominent pancreatic duct noted at 0.17 cm.

### ***Free Abdomen***

Evaluation of the peritoneal cavity did not reveal any evidence of effusion. There is a mild mesenteric lymphadenopathy with clusters of prominent hypoechoic lymph nodes particularly at the mesenteric root. An example measures 0.52 cm x 1.87 cm. The omentum is hyperechoic around the prominent lymph nodes.

## **PRIMARY FINDINGS**

- Pancreatic changes most consistent with mild pancreatitis in the left limb.
- Mild small intestinal thickening with some areas displaying a prominent muscularis layer – The small intestinal wall changes could be consistent with an underlying inflammatory process. These types of changes can sometimes be seen in normal older cats. Correlate with clinical signs.
- Mild mesenteric lymphadenopathy – Findings are most consistent with reactive lymph nodes, although early neoplastic lymph nodes cannot be ruled out.

## **SECONDARY FINDINGS**

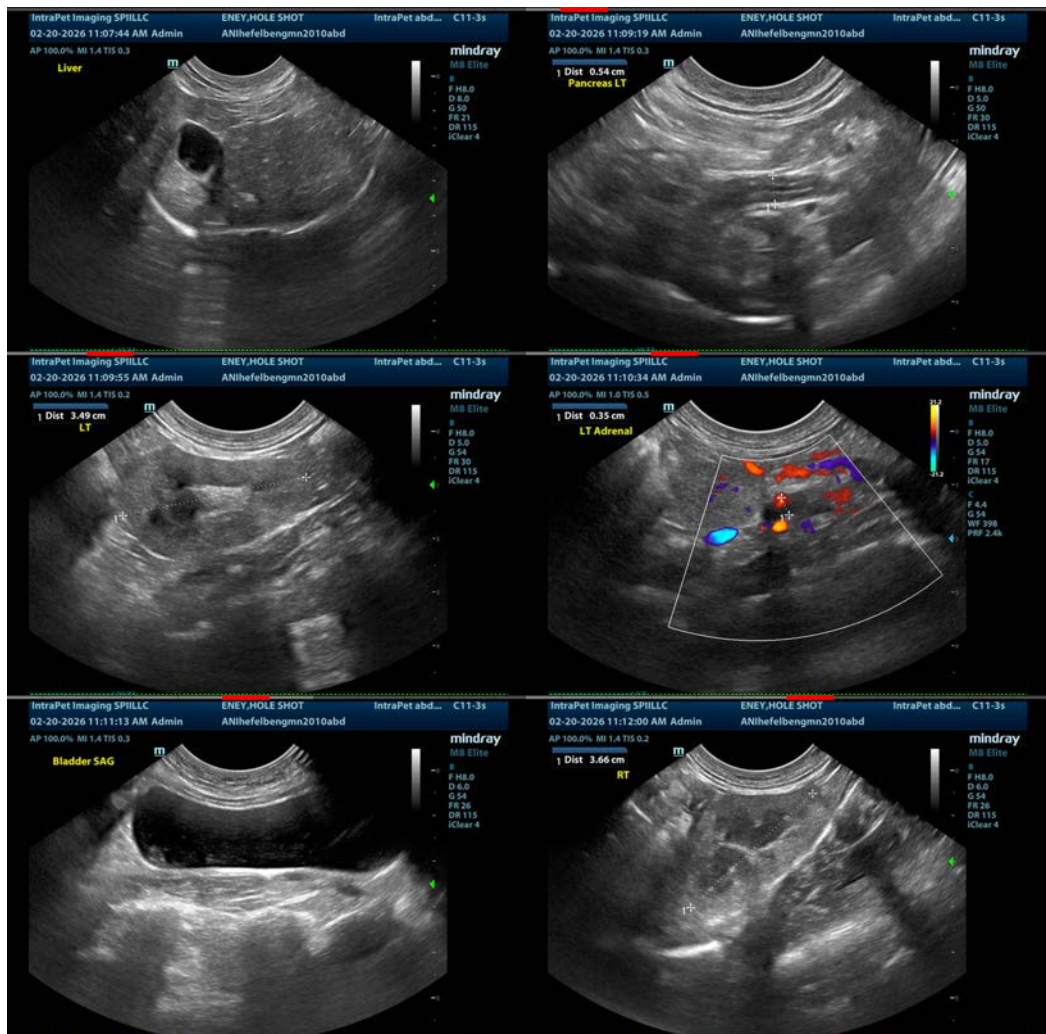
- Mild suspended echogenic debris in the urinary bladder – The echogenic debris in the bladder lumen could be consistent with cells, crystals, and/or mucus.

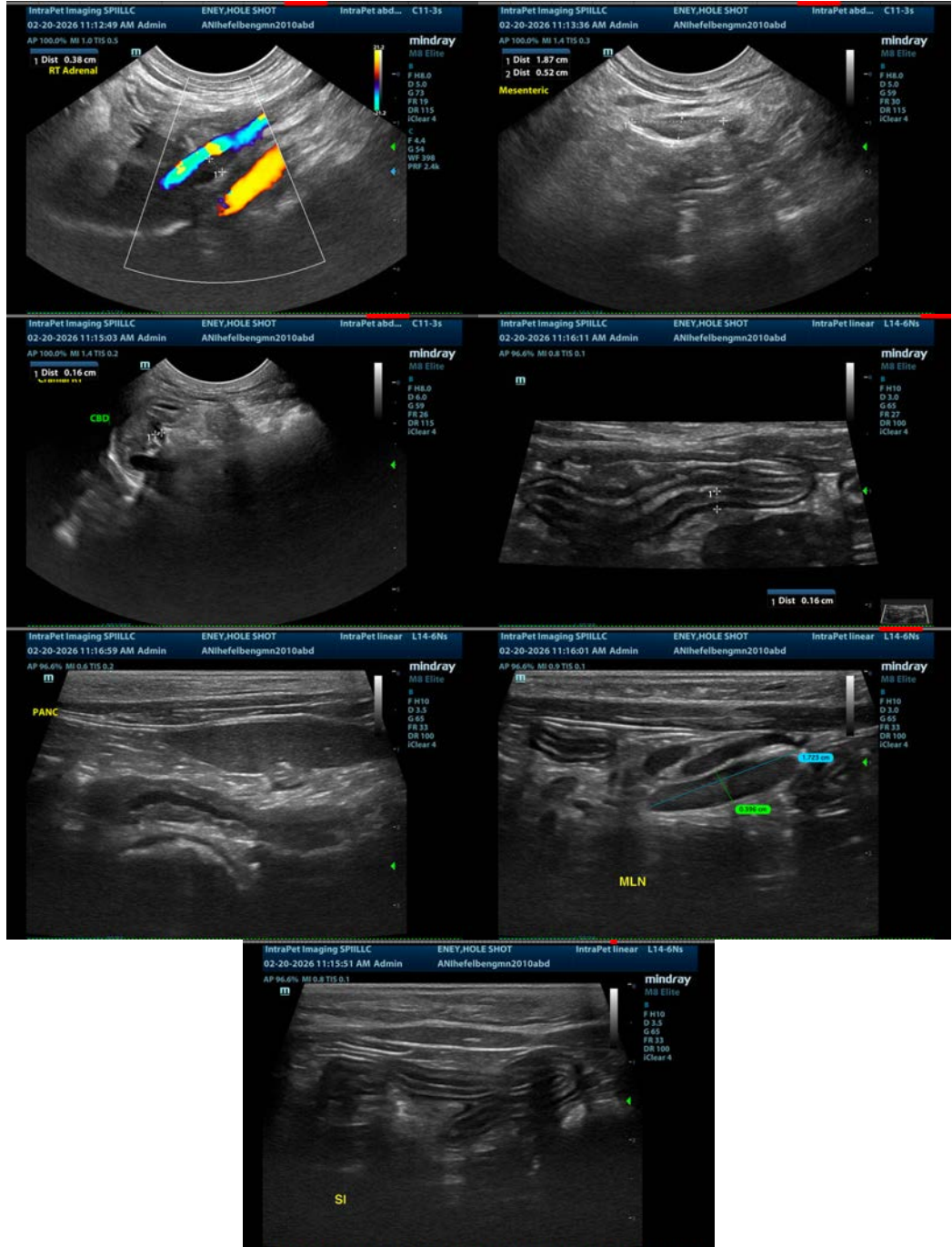
## **INTERPRETATION OF THE FINDINGS & FURTHER RECOMMENDATIONS**

The small intestine appears diffusely thickened/ “ropey” with some areas exhibiting a prominent muscularis layer. These changes are most consistent with inflammatory type change, although early neoplastic change cannot be ruled out. Additionally, the left limb of the pancreas is prominent and hypoechoic with some reactive mesentery in the region, most consistent with mild pancreatitis. Consider the following:

- Recommend GI panel to Texas A&M for a qualitative fPLI, TLI, cobalamin and folate. This will evaluate for elevation in pancreatic values and look for evidence of an underlying enteropathy.
- Consider a novel protein/hydrolyzed protein diet (exclusively at least 4-6 weeks)
- Recommend chronic probiotic therapy.

If these steps are taken and symptoms are persistent, biopsies of the GI tract may be warranted to further evaluate. Additionally, you could consider reevaluation of the pancreas and lymph nodes with ultrasound, looking for progression or improvement over time.





**The information and recommendations provided are based on the images presented by the referring veterinarian/sonographer. No evaluation can be communicated regarding pathology that was not visible in the image/video clips provided.**

Thank you for this referral. If the clinical or image interpretation does not parallel your findings or if I can be of any further assistance please contact me.

Kathleen Sennello DVM,MS, Diplomate ACVIM (Small animal Internal Medicine)  
info@sonopath.com