



PATIENT

Sadie Scoular

SPECIES

Feline

BREED

DSH

SEX

Spayed Female

AGE

17 Years

WEIGHT

2.8 kg

INTERPRETED BY

Kathleen A. Sennello
DVM, MS, DACVIM
(SAIM)

IMAGING PERFORMED BY

Dr. Iacovides

HOSPITAL NAME

Tuxedo AH

REFERRING VET

Dr. Bongiorno

INVOICE

35887

DATE

2/19/26

PRESENTING CLINICAL SIGNS

- Seen last week for inappetence, lethargy and weight loss
- Initial workup revealed hyperthyroidism on bloodwork, but physical exam was suspicious for abdominal mass/problem
- Imaging was delayed until today as cat has continued to have a poor appetite.
- Drinking seems increased
- Abnormal PE/Chem/CBC/UA Results: Weight loss BCS 2/5 slt palor dehydrated pendulous abdomen with suspicion for pain on palpation of cranial abdomen Rads(today): poor serosal detail suggestive of effusion CBC/Chem/tt4: CBC: mild lymphopenia CHEM: SDMA 15 y/dl (0-14) Crea 63 umol/l (71-212) TT4: 76 nmol/l (10-60)

ULTRASONOGRAPHIC EXAMINATION OF THE ABDOMEN

Urinary System

The urinary bladder is mildly distended with anechoic urine. The bladder wall appears thickened and diffusely irregular, measuring 0.57 cm. No significant lesions are visualized associated with the region of the trigone, but evaluation of the urinary bladder is impaired due to lack of urine distention.

The left kidney has a normal shape and size (3.47 cm). Overall echogenicity is normal with adequate corticomedullary distinction and a typical 1:3 cortex:medulla ratio. There is no evidence of perinephric inflammation or effusion. There is no evidence of pyelectasia, nephroliths, infarcts or hydroureter. Renal vasculature is normal. Occasional small cortical cysts were noted.

The right kidney has a normal shape and size (3.12 cm). Overall echogenicity is normal with adequate corticomedullary distinction and a typical 1:3 cortex:medulla ratio. There is no evidence of perinephric inflammation or effusion. There is no evidence of pyelectasia, nephroliths, infarcts or hydroureter. Renal vasculature is normal.

Adrenal Glands

The left adrenal gland is normal in size measuring 0.49 cm at the caudal pole. It is observed in its normal position cranial to the left renal artery. It is normal in appearance (uniformly hypoechoic) and shape with no evidence of a mass effect.

The right adrenal gland is normal in size measuring 0.51 cm at the caudal pole. It is observed in its normal position between the cranial aspect of the right kidney and the caudal vena cava. It is normal in appearance (uniformly hypoechoic) and shape with no evidence of a mass effect.

Spleen

The spleen is subjectively normal in size (0.92 cm), echotexture is homogenous, and the splenic capsule is smooth with no irregularities. The blood flow through the hilus and splenic parenchyma appears normal. No focal parenchymal abnormalities are visualized.

Liver



PATIENT

Sadie Scoular

SPECIES

Feline

BREED

DSH

SEX

Spayed Female

AGE

17 Years

WEIGHT

2.8 kg

INTERPRETED BY

Kathleen A. Sennello
DVM, MS, DACVIM
(SAIM)

IMAGING PERFORMED BY

Dr. Iacovides

HOSPITAL NAME

Tuxedo AH

REFERRING VET

Dr. Bongiorno

INVOICE

35887

DATE

2/19/26

The liver is subjectively large in size and irregular. The parenchyma is heterogenous in echotexture with subtle, indistinct focal mottling. The visible portions of the vasculature and biliary tract appear normal. There is a large, somewhat poorly defined complex cystic mass effect visualized in the mid left region of the liver, measuring >5.55 cm x 3.21 cm. Additionally, there are hyperechoic nodules visualized in the caudate lobe, examples measure 0.6 cm and 0.37 cm which mildly deviate the hepatic margins.

The gall bladder lumen is moderately distended. The gallbladder wall appears somewhat prominent, measuring at 0.18 cm. There is a moderate amount of non-organized echogenic debris. The cystic and common bile ducts are normal/not visible.

Gastrointestinal

The stomach contains minimal luminal contents. It measures at a normal thickness of <0.7 cm with some variability due to the presence of rugal folds. The distinction of the gastric wall layers is adequate and there is no impression of reduced peristaltic activity. No masses or focal lesions were observed.

The visualized areas of duodenum, jejunum and ileum have a uniform diameter with minimal fluid distension. Wall thickness is normal to slightly increased. Bowel loops follow a typical curvilinear path with distinct wall layering, but some areas display a prominent muscularis layer which does not display the typical 1:3 muscularis:mucosa layer ratio. The duodenum measured 0.32 cm in diameter, and the jejunum measured 0.27 cm in diameter. Visualized peristalsis appears appropriate. There were no focal lesions consistent with obstruction or a mass effect observed.

The ileocecal junction was visualized and exhibited normal intact wall layering and is subjectively of normal thickness. Sections of colon are visualized with formed fecal material and gas shadowing distally. There is no observed focal or generalized colon wall thickening or loss of layering.

Pancreas

The pancreas is large and hypoechoic to surrounding mesentery. In the left caudal aspect of the region of the pancreas, there is a significant amount of irregular, poorly defined, mixed echogenicity tissue creating a poorly defined mass effect, measuring approximately 1.82 cm x 2.45 cm, most consistent with a pancreatic mass lesion or an omental mass lesion. There is evidence of regional mesenteric inflammation. Consistent with mild/moderate pancreatitis.

Free Abdomen

There is a large amount of free fluid. There is no significant lymphadenopathy visualized. The omentum is severely irregular and hyperechoic, particularly in the region of the left pancreas/mass effect.

ULTRASONOGRAPHIC FINDINGS

- Minimally distended urinary bladder with a thickened irregular wall- The bladder mucosal changes could be consistent with cystitis or artifactual due to lack of adequate luminal distension. Bladder neoplasia cannot be ruled out but is considered unlikely in this patient.
- Prominent hypoechoic pancreas, which appears to be associated with abnormal mixed echogenicity tissue/mass effect in the left limb. Findings are concerning for pancreatic neoplasia.



PATIENT

Sadie Scoular

SPECIES

Feline

BREED

DSH

SEX

Spayed Female

AGE

17 Years

WEIGHT

2.8 kg

INTERPRETED BY

Kathleen A. Sennello
DVM, MS, DACVIM
(SAIM)

IMAGING PERFORMED BY

Dr. Iacovides

HOSPITAL NAME

Tuxedo AH

REFERRING VET

Dr. Bongiorno

INVOICE

35887

DATE

2/19/26

- Large heterogenous liver with a large complex cystic mass effect- Hepatic changes are non-specific and could be consistent with inflammation/infection (cholangiohepatitis), infiltrative neoplasia, lipidosis or other hepatopathy. The complex cystic structure has the appearance most consistent with a cystadenoma or cystadenocarcinoma.

- Moderate gallbladder debris with a prominent gallbladder wall- Findings could be consistent with edema or mild cholecystitis.

- Mildly thickened small intestine with a prominent muscularis layer- The small intestinal wall changes are most consistent with an inflammatory process (i.e., inflammatory bowel disease) with a low possibility of emerging lymphoma.

- Large volume free abdominal fluid- recommend fluid analysis and cytology.

INTERPRETATION OF THE FINDINGS & FURTHER RECOMMENDATIONS

There is a large amount of free fluid in the abdomen. The pancreas is visible in both limbs and appears prominent and hypoechoic with prominent pancreatic duct. In the region of the caudal left limb of the pancreas there is poorly defined mixed echogenicity tissue creating a mass effect, concerning for a possible pancreatic mass lesion. Recommend a fine needle aspirate of this area.

There is a large complex cystic mass effect visualized associated with the liver. This has the appearance most consistent with a cyst, cystadenoma, or cystadenocarcinoma, although other differentials are possible. If surgical intervention is being considered, recommend a contrast CT scan to better delineate this mass effect for possible surgical resection. This could also represent an incidental finding.

The small intestine appears mildly diffusely thickened. This could be consistent with edema, mild inflammation, etc.

Recommend cytologic evaluation of the suspected pancreatic mass lesion and the free abdominal fluid. If a definitive diagnosis is obtained, recommend consultation with a veterinary oncologist regarding the best treatment options and prognosis. If the diagnosis is still unclear, options could include a contrast CT scan, surgical explore, etc., although a metastatic neoplastic process would be the primary concern.

Consider three view thoracic radiographs to rule out concurrent thoracic disease/involvement.



PATIENT

Sadie Scoular

SPECIES

Feline

BREED

DSH

SEX

Spayed Female

AGE

17 Years

WEIGHT

2.8 kg

INTERPRETED BY

Kathleen A. Sennello
DVM, MS, DACVIM
(SAIM)

IMAGING PERFORMED BY

Dr. Iacovides

HOSPITAL NAME

Tuxedo AH

REFERRING VET

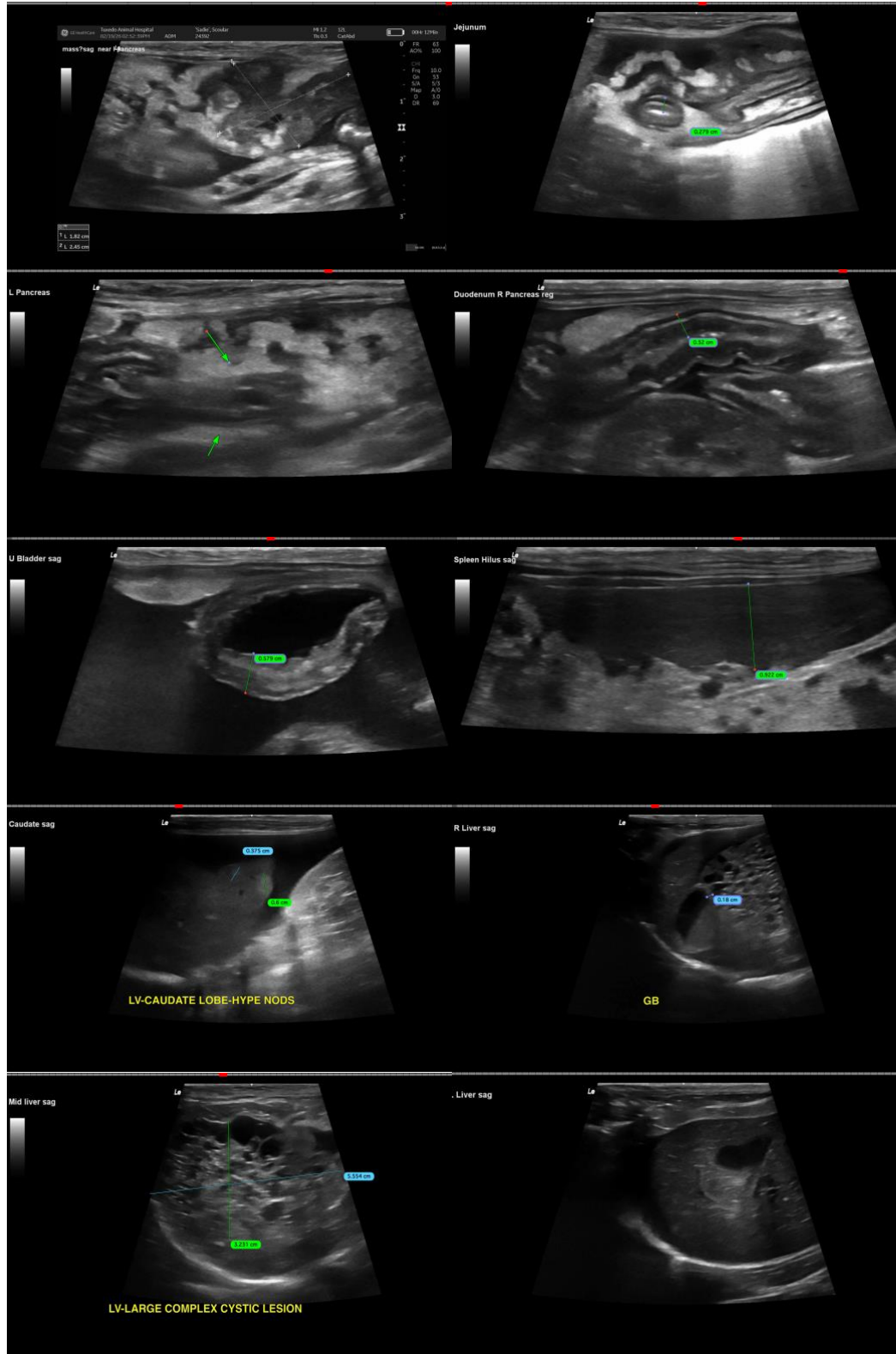
Dr. Bongiorno

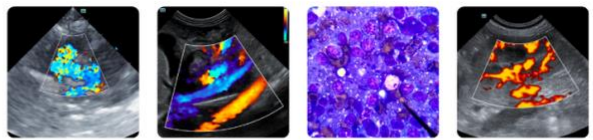
INVOICE

35887

DATE

2/19/26





PATIENT

Sadie Scoular

SPECIES

Feline

BREED

DSH

SEX

Spayed Female

AGE

17 Years

WEIGHT

2.8 kg

INTERPRETED BY

Kathleen A. Sennello
DVM, MS, DACVIM
(SAIM)

IMAGING PERFORMED BY

Dr. Iacovides

HOSPITAL NAME

Tuxedo AH

REFERRING VET

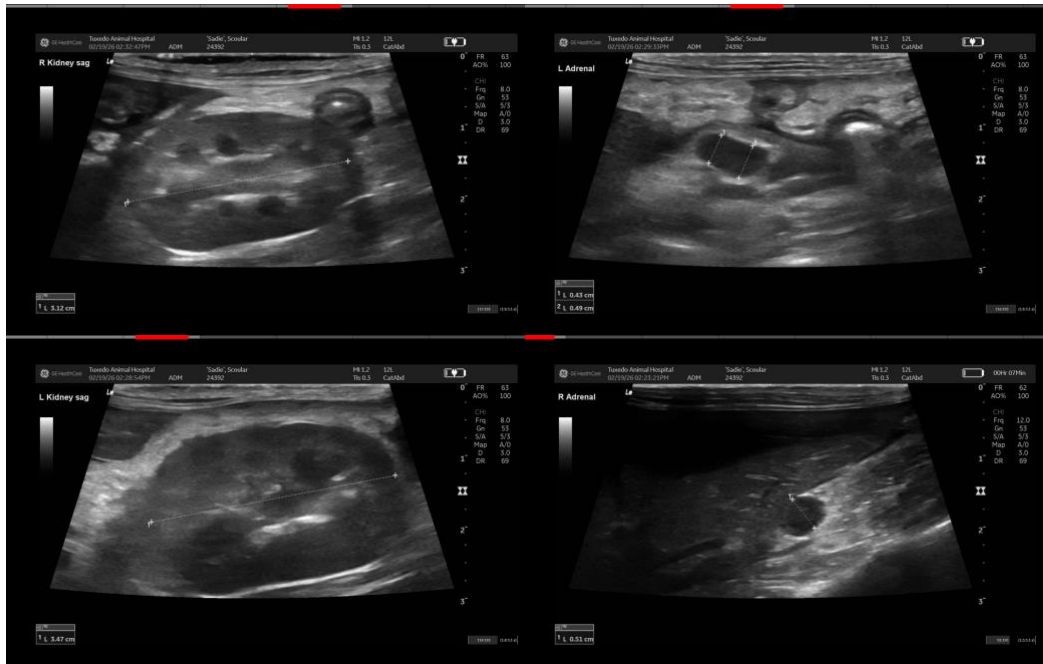
Dr. Bongiorno

INVOICE

35887

DATE

2/19/26



The information and recommendations provided are based on the images presented by the referring veterinarian/sonographer. No evaluation can be communicated regarding pathology that was not visible in the image/video clips provided.

Thank you for this referral. If the clinical or image interpretation does not parallel your findings or if I can be of any further assistance, please contact me.

Kathleen Sennello DVM, MS, Diplomate ACVIM (Small animal Internal Medicine)

info@sonopath.com